



ISSN: 0975-833X

CASE REPORT

PRUNE BELLY SYNDROME- A CASE REPORT

¹Hari Charan Sarangsa and ^{*2}Santosh Kumar Sahu

¹Department of Anatomy, Silchar Medical College and Hospital, Silchar, Assam, India

²Department of Anatomy, Jorhat Medical College and Hospital, Jorhat, Assam, India

ARTICLE INFO

Article History:

Received 16th May, 2015
Received in revised form
23rd June, 2015
Accepted 10th July, 2015
Published online 31st August, 2015

Key words:

Prune Belly Syndrome (PBS),
Large phallus,
Oligohydramnios.

ABSTRACT

The Prune Belly Syndrome (PBS) is characterized by the triad of deficient abdominal wall musculature, undescended testes and urinary tract anomalies. PBS may be also associated with other urological and non urological condition. The exact etiology is not known and neither the best treatment. Many infants are still born or die within first few weeks of life from severe kidney or lung problems, or due to combined congenital anomalies. The present case is a dead male fetus of 31 weeks pregnancy delivered to Anatomy department due to presence of gross congenital anomalies.

Copyright © 2015 Hari Charan Sarangsa and Santosh Kumar Sahu. This is an open access article distributed under the Creative Commons Attribution License, which permits unrestricted use, distribution, and reproduction in any medium, provided the original work is properly cited.

Citation: Hari Charan Sarangsa and Santosh Kumar Sahu, 2015. "Prune Belly Syndrome-A Case Report", *International Journal of Current Research*, 7, (8), 19634-19637.

INTRODUCTION

Prune Belly Syndrome (PBS) is also known as, Eagle-Barret syndrome, Triad, Osler- Parker Syndrome, Abdominal muscle deficiency syndrome and Mesenchymal dysplasia syndrome (Rupshikha *et al.*, 2011; Ghritlaharey *et al.*, 2007; Hasset *et al.*, 2012; Eagle and Barrett, 1950; Obrinsky, 1949). The characteristics wrinkled, prune like abdomen of the infant give the syndrome its name (Wood and Brandon, 2007). Prune belly syndrome is a rare congenital disease. The incidence of prune belly syndrome is between 1 in 29,000 to 1 in 40,000 live male births (Simons *et al.*, 2003). Males are affected 20 times more often than females, with approximately 3% of all cases occurring in females (Leeners *et al.*, 2000; Baris *et al.*, 2001). Fewer than 30 cases of female are reported in literature (Reinberg *et al.*, 1991). Infant born to younger mothers are at greater risk for having prune belly syndrome (Leeners *et al.*, 2000; Baris *et al.*, 2001). The incidence of prune belly syndrome in twins is 4 times greater than that found in single births, at 12.2 per 100,000 live births (Balaji *et al.*, 2000). The exact etiology of Prune belly Syndrome is uncertain. Deficient development of abdominal muscles that causes the skin of the abdomen to wrinkle like a prune, cryptorchidism,

abnormalities of the urinary tract (Rupshikha *et al.*, 2011; Ghritlaharey *et al.*, 2007; Hasset *et al.*, 2012; Eagle and Barrett, 1950; Obrinsky, 1949; Wood and Brandon, 2007; Simons *et al.*, 2003; Leeners *et al.*, 2000; Baris *et al.*, 2001; Reinberg *et al.*, 1991; Balaji *et al.*, 2000). It is associated with other congenital anomalies and most commonly clinically presented with stillborn (Tagore *et al.*, 2011). The case is reported for its rare congenital abnormality

Case Report

A 29 year old female with a non consanguineous marriage of 6 years, second gravida with a healthy first child and with no family history of congenital anomalies delivered a preterm parturition of a still born male baby at 31 weeks at Silchar Medical College and Hospital, Silchar, Assam, India. There was no history of draining or bleeding per vagina, and no history of hypertension, diabetes, tuberculosis, bronchial asthma, epilepsy, no antenatal teratogenic exposure, fever, rash, or any drug intake. The baby weighted 2.6 kg.

The length of the baby was 47 cm, chest circumference 28 cm and head circumference 35 cm. The baby was diagnosed to be a case of Prune belly syndrome because multiple anomalies were recognized at birth. Those were (1) There was flabby abdominal wall ballooning out in the flanks and skin creases radiating laterally and downwards from the umbilicus, (2) Flat nose, (3) Low set ears, (4) Nipples are absent, (5) A large phallus (Figure 1).

*Corresponding author: Santosh Kumar Sahu,
Department of Anatomy, Jorhat Medical College and Hospital,
Jorhat, Assam, India.

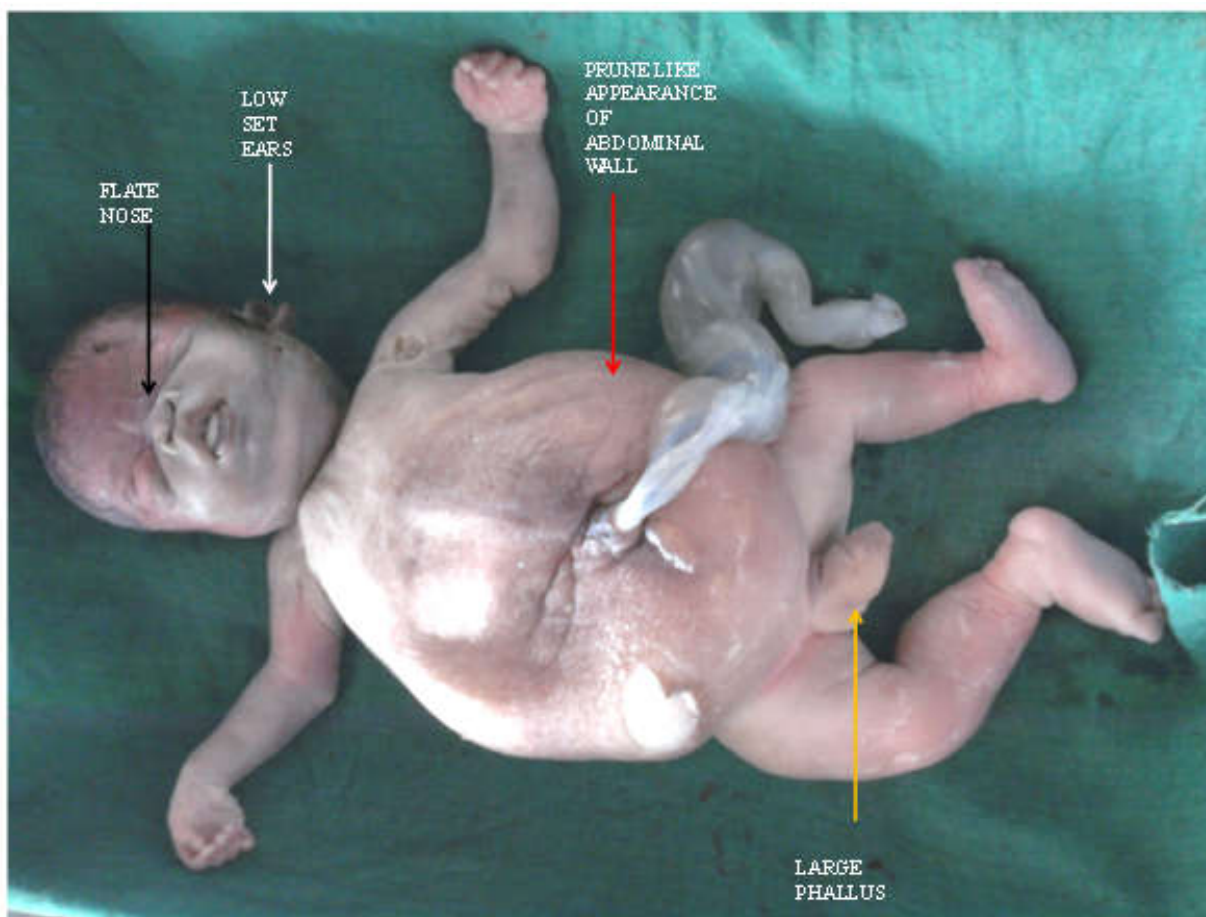


Figure 1. Black arrow showing flate nose, white arrow showing low set ears, red arrow showing prune like appearance of abdominal wall, yellow arrow showing large phallus

Rest of examination is found to be normal. Attendants refused any further imaging investigation and dissection of this stillborn PBS baby and thus the case was handed over to the attendant.

DISCUSSION

This congenital anomaly was first described by Frolichs in 1839 (Smith and John, 2002). Parker in 1895 presented a case with deficient abdominal wall musculature and dilatation of the urinary tract (Felix and Richard, 1997; Parker, 1895). The term Prune Belly was first coined by Oslar in 1901, as the skin of the patient had dried plum appearance with skin creases (Parker, 1895). The Prune belly syndrome is a congenital disorder with a group of birth defects that involve three main problems: 1. Poor development of the abdominal muscles, causing the skin of abdomen wrinkle like a prune, 2. Undescended testicles (cryptorchidism) and 3. Urinary tract problems like renal hypoplasia, hydronephrosis, hydroureteronephrosis, massive bladder, dilated prostatic urethra, hypoplastic prostate etc (Vani *et al.*, 2013).

In addition to this classical syndrome it is also associated with pulmonary 55%, orthopaedic 40-63%, gastrointestinal 31% and cardiac 10% (Geary *et al.*, 1986; Burbige *et al.*, 1987). Again some other anomalies are also found in this syndrome which results from secondary to oligohydramnios as a pressure effect.

These are flattened cranium, faces and nose, low set ears and chin, the pulmonary hypoplasia, cryptorchidism, Spina bifida, Talipes, congenital dislocation of hips and other lower limb abnormalities are commonly found (Vani *et al.*, 2013; Ganesan and Indrajit, 2001). In female PBS never present in complete forms, there is also associated anomalies of uterus and vagina in them (Farooqui *et al.*, 2014).

Our case also present with the deficient abdominal muscle development, cryptorchidism, flat nose and low set ears. The absence of nipple is also observed in PBS by Tagore *et al* (Tagore *et al.*, 2011). The phallus is large in our case; similar large phallus in PBS is also observed by Fette A (Fette, 2015) and Shah D *et al* (Shah *et al.*, 2004). The pathogenesis of Prune belly syndrome is till date not clearly understood

The first theory proposes a prenatal obstruction of the urinary tract, which causes urinary tract dilatation, fetal abdominal distension, and subsequent muscle wall hypoplasia and cryptorchism (Das *et al.*, 1988; Randolph *et al.*, 1981; Volmar *et al.*, 2003; Leordean *et al.*, 2012; Puri and Miyakita H. Prune, 2011). The second, embryology-based theory, proposes the failure of primary mesodermal differentiation between the 6th and 10th week of gestational age (GA), which leads to the defective muscularization of both, the abdominal wall and the urinary tract (Das *et al.*, 1988; Randolph *et al.*, 1981; Volmar *et al.*, 2003; Leordean *et al.*, 2012; Puri and Miyakita H. Prune, 2011).

A third one, the yolk sac theory, indeed, proposes a dysgenesis of the yolk sac and allantois as causative for PBS (Das *et al.*, 1988). But among these three theories, none can explain PBS completely. The abdominal muscle more frequently involved are central and lower abdominal muscle and it can be explained by the first theory but it cannot explain why these kind of changes do not occur in a male infant born with posterior urethral valve (Randolph *et al.*, 1981; Volmar *et al.*, 2003; Leordean *et al.*, 2012; Puri and Miyakita H. Prune, 2011) moreover it also fails to explain the absence of post obstructive changes like smooth muscle thickening, bladder wall trabeculation etc ^[26] The second and third theory cannot explain the abnormalities found in upper urinary tract and genitals (Das *et al.*, 1988; Leordean *et al.*, 2012; Puri and Miyakita H. Prune, 2011). Vani *et al* mentioned teratogenic effect caused by viral infection or drug abuse during early week of pregnancy may cause PBS (Vani *et al.*, 2013)

The incomplete or the female syndrome is also known as the "Pseudo Prune Belly syndrome" (Arronson and Cremein, 1980; Rabinowitz and Schillinger, 1977). Till date no clear genetic inheritance pattern has been proved. The observation of 100% discordance among all twins in whom monozygosity has been proven, goes against a genetic aetiology (Ives, 1974) but, the reported association with Turner's syndrome, monosomy 16, Trisomy 13 and Trisomy 15 confound identification of a simple gene locus ^[31-34]. Felix *et al* suggested that the pattern of inheritance may be a two steps autosomal dominant mutation with sex limited expression that partially mimics X-linkage. This theory accounts for the predominance of male subject and occasional familial occurrence (Felix and Richard, 1997; Adenoyokunna and Familusi, 1982)

The prognosis of PBS is poor with stillbirths and early infant deaths being common (Metwalley *et al.*, 2008) Prune belly syndrome in the adult is scanty. Only one case of 24 year old male from Nigeria is available in literature with PBS (Salako *et al.*, 2009). Diao *et al.* reported that renal failure is the main cause of death in PBS (Diao *et al.*, 2008). There are cases of prune belly syndrome who survived into adult life after abdominal reconstruction and urinary tract repair (Woodhouse, 2001).

Conclusion

Since the first description of the disease between 1839 and 1895 PBS data have been composed primarily of case reports and small case series. There is no known prevention but the routine use of screening for foetal anomalies should be encouraged but till date in a developing country like India accurate antenatal diagnosis of PBS is a challenge. Early diagnosis of this syndrome and determining its optimal treatment are very important in helping to avoid its fatal course.

REFERENCES

Adenoyokunna, A. A. and Familusi, J. B. 1982. Prune belly syndrome in two siblings and a first cousin. *Am. J. Dis. Child*, 136: 23.

- Arronson, I.A. and Cremein, B.J. 1980. Prune belly syndrome in young females. *Uro, Radiol.*, 150 -5.
- Balaji, K., Pati, I. A., Townes, P., Primack, W. and Skare, J. 2000. Concordant prune belly syndrome in monozygotic twins. *Urology*, 55:949.
- Baris, S., Karakaya, D., Ustum, E., Tur, A. and Rizalar, R. 2001. Complicated airway management in a child with prune-belly syndrome. *Paediatr Anaesth*, 11:501-4.
- Beckman, H., Reher, H. and Rauskolb, R. 1984. Letter to the editor, Prune belly sequence associated with trisomy 13. *Am. J. Med. Genet.*, 19:603.
- Burbige, K.A., Amodio, J., Berdon, W.E. and Hensle, T.W. 1987. Prune belly syndrome -35 yrs of experience. *J. Urol.*, 137: 86-90.
- Das, N.L., Doberty, R.D., Hingsbergen, E.A. and Fulcher, A.S. 1988. Pediatric case of the day. *Radiographics*, 18(5):1318-22.
- Diao, B., Diallo, Y., Fall, P.A., Ngom, G., Fall, B., Ndoye, A.K., Fall, I., Ba, M., Ndoye, M. and Diagne, B.A, 2008. Prune Belly syndrome: Epidemiologic, clinic and therapeutic aspects. *Prog. Urol.*, 18(7):470-4.
- Eagle J.F. Barrett, 1950. Congenital deficiency of abdominal musculature with associated genitourinary abnormalities: A syndrome. Report of 9 cases. *Pediatrics*, 6:721-36.
- Farooqui, A., Aqeel, A.A. and Habib, Z. 2014. Prune belly syndrome with overlapping presentation of partial urorectal septum malformation sequence in a female newborn with absent perineal openings. *Case Rep. Surg.*, 746323
- Felix, Y.I.P. and Richard, M. 1997. *Pediatr. Urology*. 3rd ed. Butterworth Heinemann; p. 618-20.
- Fette, A. 2015. Associated rare anomalies in prune belly syndrome: A case report. *J. Ped. Surg. Case Reports*, 3: 65-71
- Frydman, M., Magenis, R.E. and Mohandas, T.K. 1983. Chromosome abnormalities in infants with prune belly anomaly, Association with Trisomy 18. *Am. J. Med. Genet.*, 15: 145.
- Ganesan, S. and Indrajit, I.K. 2001. Images : Prune belly syndrome : Antenatal ultrasound. *Indian J. Radiol. Imaging*, 11:25-8.
- Geary, D.F., Lusky, L.B.M. and Churchill, B.M. 1986. A broaderspectrum of abnormalities in the Prune Belly Syndrome. *J. Uro.*, 135, 324.
- Ghritlaharey, R.K., Gupta, G., Kushwaha, A.S. and Chanchlani, R. 2007. Prune belly syndrome associated with incomplete VACTERL. *J. Indian Assoc. Pediatr. Surg.*, 12(1):39-41
- Harley, L.M. and Rather, W.H. 1972. Prune belly syndrome. *J. Urol.*, 108: 174.
- Hasset, S., Smith, G.H.H. and Holland, A.J.A. 2012. Prune belly syndrome. *Pediatr.Surg. Int.*, 28:219-28
- Ives, E.J. 1974. The abdominal muscles deficiency triad syndrome: Experience with ten cases. *Birth Defects*, 10:127.
- Leeners, B., Sauer, I., Schefels, J., Cotarelo, C.L. and Funk, A. 2000. Prune-belly syndrome: therapeutic options including in utero placement of a vesicoamniotic shunt. *J. Clin. Ultrasound*, 28:500-6.
- Leordean, V., Lazar, D. and Trofenciuc, M. 2012. Case reports: morphological aspects in a urogenital

- malformation, complex and rare, in a child. *Rom. J. Morphol. Embryol.*, 53(2):412-25.
- Metwalley K.A., Farghalley H.S. and Abd-Elsayed A. A. A. 2008. Prune belly syndrome in an Egyptian infant with Down syndrome: A case report. *J Med Case Reports*. 2:322
- Obrinsky, 1949. Agenesis of abdominal muscles with associated malformation of the genitourinary tract; a clinical syndrome. *Am. J. Dis. Child*, 362-73.
- Parker, R.W. 1895. Absence of abdominal muscles in an infant. *Lancet*; p.1252-4
- Puri, P. and Miyakita, H. 2011. Prune belly syndrome. In: Puri P, editor. *Newborn surgery*. Hodder & Stoughton Ltd; p. 681-5.
- Rabinowitz, R. and Schillinger. J.F. 1977. Prune belly syndrome in the female subject. *J. Urol.*, 118:454-6.
- Randolph, J., Cavett, C. and Eng, G. 1981. Surgical correction and rehabilitation for children with "Prune e belly" syndrome. *Ann Surg.*, 193(6):757-62
- Reinberg, Y., Shaprio, E., Manivel, J.C., Manley, C.B., Pettinato, G. and Gonzalez, R. 1991. Prune-Belly syndrome in females: a triad of abdominal musculature deficiency and anomalies of the urinary and genital systems. *J. Pediatr.*, 1991 March; 118(3):395-8.
- Rupshikha, D., Phukon, M.J., Kusre, G.R., Satyanarayana, N. and Sunitha, P. 2011. Prune belly syndrome - A case report. *J. College Med. Sciences-Nepal*, 7(3):48-52
- Salako, A.A., Takure, A.O., Olajide, A.O., Aarowolo, O.A. and Egberongbe, A.A. 2009. Prune belly syndrome in an adult Nigerian: A case report. *Afr. J. Med. Med. Sci.*, 38:357-60.
- Shah, D., Sharma, S., Faridi, M.M.A. Mishra K.V. Vacteral, 2004. Association with Prune belly syndrome. *Ind. Ped.*, 41: 845-7
- Simons, H.P., Dijk, M.V., Anand, K.S., Roofthoof, D., Lingen, R.A.V. and Tibboel, D. 2003. Do we still hurt newborn babies? A prospective study of procedural pain and analgesia in neonates. *J. Americ. Med. Assoc. Ped.*, November; 157(11):1058-64.
- Smith, A.E. and John, R. 2002. *Campbell Urology*. 8th ed: Saunders; P. 2117- 24. (Vol 3)
- Tagore, K.R., Ramineni, A.K.S., Lakshmi, A.R.V, N.B. 2011. Prune belly syndrome. Case reports in pediatrics, Article ID 121736, 3 pages. <http://dx.doi.org/10.1155/2011/121736>
- Vani, A., Saritha, S., Sangeetha, K. and Supriya, G. 2013. Prune belly syndrome (sequenze): a case report. *Int. J. Res. Med. Sci.*, May; 1(2):148- 52.
- Volmar, K.E., Nguyen, T.C., Holcraft, C.J., Blakemore, K.J. and Hutchins, G.M. 2003. Phimosis as a cause of the prune belly syndrome: comparison to a more common pattern of proximal penile urethra obstruction. *Virchows Arch.*, 442:169-72. <http://dx.doi.org/10.1007/s00428-002-0730-x>.
- Wood, A.G. and Brandon, D.H. 2007. Prune belly syndrome, A focused physical assessment. *Advances in neonatal care*. Jun; 7 (3):132-43.
- Woodhouse, C.R.J. 2001. Prospects for fertility in patients born with genitourinary anomalies. *J. Urol.*, 165(6): 2354-60.
