



ISSN: 0975-833X

## RESEARCH ARTICLE

### ISOLATED AORTIC REGURGITATION – ARE WE MISSING SOMETHING!!!

<sup>1</sup>Dr. Srikrishna Raghavendra Boddu, <sup>\*2</sup>Dr. M. Sudhakar Rao, <sup>2</sup>Dr. Padmakumar, R. and <sup>2</sup>Dr. Ashwal, A. J.

<sup>1</sup>Department of Medicine, KMC Manipal, Manipal University, India

<sup>2</sup>Department of Cardiology, KMC Manipal, Manipal University, India

#### ARTICLE INFO

##### Article History:

Received 05<sup>th</sup> October, 2015

Received in revised form

16<sup>th</sup> November, 2015

Accepted 11<sup>th</sup> December, 2015

Published online 31<sup>st</sup> January, 2016

#### ABSTRACT

Coronary ostial stenosis is a rare complication of syphilitic aortitis and majority of cases have been reported only at autopsy. The prevalence of coronary ostial lesions with aortic regurgitation has been reported to be 14%. In the current era of penicillin where not many cases of syphilis can be seen, symptomatic tertiary syphilis presenting as ostial stenosis and aortic regurgitation is a rarity in itself. Here we report a case of cardiovascular syphilis presenting with isolated aortic regurgitation and syphilitic aortitis.

#### Key words:

Isolated Aortic regurgitation,  
Syphilitic Aortitis.

Copyright © 2016 Srikrishna Raghavendra Boddu et al. This is an open access article distributed under the Creative Commons Attribution License, which permits unrestricted use, distribution, and reproduction in any medium, provided the original work is properly cited.

**Citation:** Srikrishna Raghavendra Boddu, M. Sudhakar Rao, Padmakumar, R. and Ashwal, A. J. 2016. "Isolated aortic regurgitation – Are we missing something!!!", *International Journal of Current Research*, 8, (01), 25634-25636.

## INTRODUCTION

In June 2015, a 37 year old male presented to cardiology department with nocturnal angina and progressive dyspnoea (NYHA class 3). He had no other risk factors for coronary artery disease. General examination revealed a pulse rate of 84 per minute which was collapsing in nature and regular in character. His blood pressure in upper limb was 140/90 mm Hg while in lower limb was 180/100 mm Hg. Cardiac auscultation revealed a soft blowing grade 3/6 early diastolic murmur. Electrocardiogram showed left ventricular hypertrophy suggestive of volume overload. Transthoracic echocardiography revealed trileaflet aortic valve with severe aortic regurgitation and mild left ventricular systolic dysfunction (Figure 1). He was planned for aortic valve replacement. A preoperative coronary angiogram was done which revealed 99% stenosis in the left main coronary artery (Figure 2). Laboratory tests revealed VDRL titres 1/16 and TPHA titres of 1/1280. Serology for Hepatitis B and C and HIV were non-reactive.

## DISCUSSION

Coronary ostial stenosis is a rare complication of syphilitic aortitis and majority of cases have been reported only at autopsy (Machado et al., 2008). Syphilis most commonly involves the ascending aorta, because it has a richer lymphatic supply. It is characterized by perivascular lymphocytic and plasma cell infiltrate that leads to obliterative endarteritis of the vaso vasorum and results in periaortitis and necrosis of the elastic fibres and connective tissue in the aortic media (mesoaortitis). The infection and inflammation may extend into the root of the aorta causing dilatation of the aortic annulus resulting in aortic regurgitation (Pugh and Grech, 2002). The prevalence of coronary ostial lesions with aortic regurgitation has been reported to be 14 % (Hosoba et al., 2001). It results in angina pectoris (Saraiva et al., 2010). The angina attacks come on at rest, last for a longer period and not relieved by nitrates. Coronary ostial stenosis may be treated by endarterectomy or bypass grafting (Komaranchath et al., 2013). In the current era of penicillin where not many cases of syphilis can be seen, symptomatic tertiary syphilis presenting as ostial stenosis and aortic regurgitation is a rarity in itself and has to be still considered as an aetiology in all isolated severe AR. Untreated and undiagnosed cases may progress to weakening of aortic wall leading to saccular or fusiform aneurysm formation.

\*Corresponding author: Dr. M. Sudhakar Rao,  
Department of Cardiology, KMC Manipal, Manipal University, India.

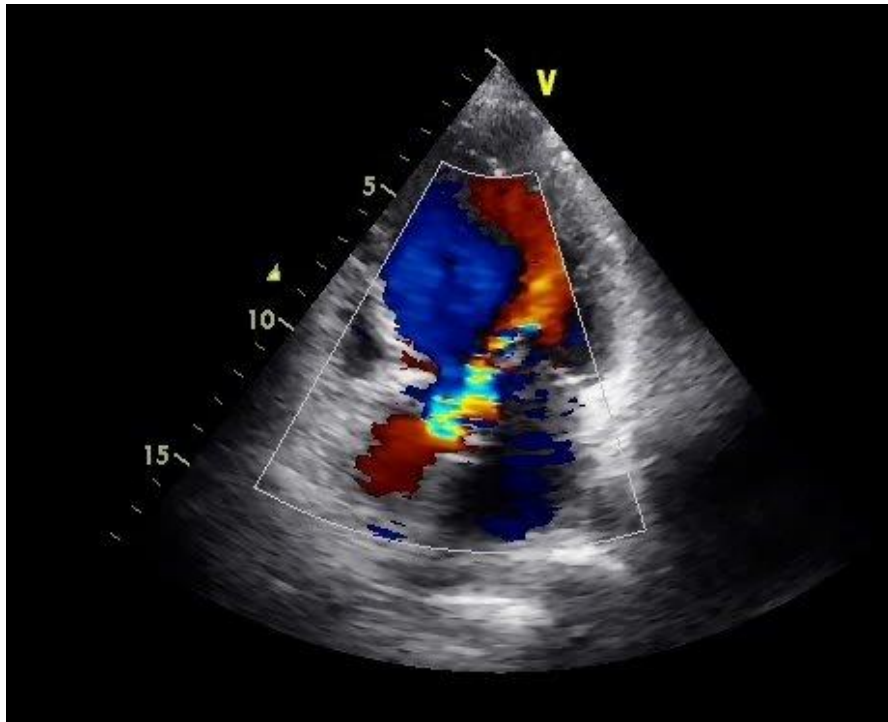


Figure 1. Trans - thoracic echocardiogram in apical 3 chamber view showing severe aortic regurgitation

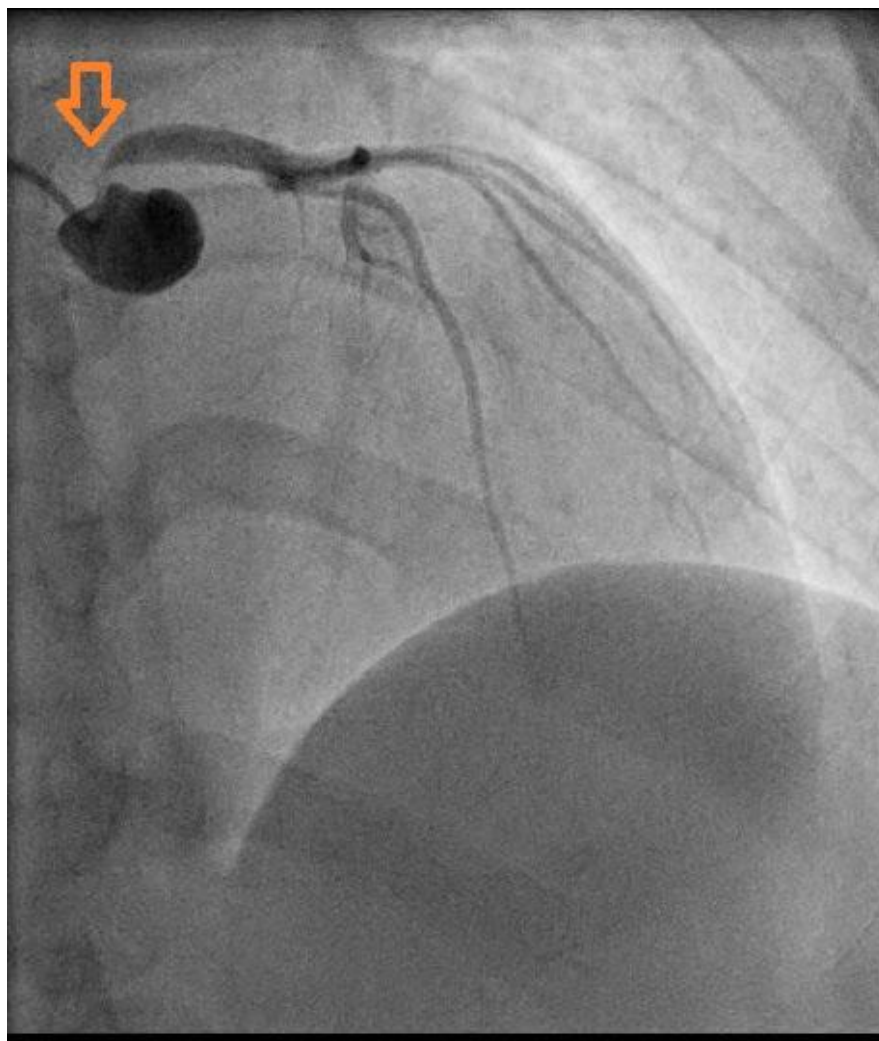


Figure 2. Coronary angiogram in Antero-Posterior (AP) cranial view showing left sided coronary system with left main coronary artery stenosis

**REFERENCES**

- Hosoba, S., Suzuki, T., Koizumi, Y., Asai, T. 2011. Syphilitic aortitis causing bilateral coronary ostial stenosis. *Heart Surg Forum.*, Feb;14(1):E59-60.
- Komaranchath, A.S., Abhilash, A., Kareem, M.M.A. 2013. Heller-Dohle syndrome: a rare case of syphilitic aortitis with calcified ascending aorta aneurysm in an elderly lady. *Am. J. Med. Case Report*, Vol I Article ID 00164.
- Machado, M.N., Trindade, P.F., Miranda, R.C., Maia, L.N. 2008. [Bilateral ostial coronary lesion in cardiovascular syphilis: case report]. *Rev Bras Cir Cardiovasc.*, Jan-Mar; 23(1):129-31.
- Pugh, P.J., Grech, E.D. 2002. Syphilis Aortitis *N. Engl. J. Med.*, 346:676.
- Saraiva, R.S., Cesar, C.A., de Mello, M.A.A., Bras, R. 2010. Syphilitic aortitis: Diagnosis treatment. Case Report. *Cir Cardiovasc.*, 25:415-8.

\*\*\*\*\*