



ISSN: 0975-833X

Available online at <http://www.journalcra.com>

International Journal of Current Research
Vol. 8, Issue, 05, pp.31740-31744, May, 2016

INTERNATIONAL JOURNAL
OF CURRENT RESEARCH

RESEARCH ARTICLE

CLINICAL PRESENTATION AND ETIOLOGICAL PATTERN IN PATIENTS WITH OCULAR MOTOR NERVE PALSY IN KOLAR REGION

¹Dr. Snehalata, G., ¹Dr. Kanthamani, K., ²Dr. Nagesha, ¹Dr. Dilip, K., ¹Dr. Jyotsna and ¹Dr. Preeti, B.

¹Department of Ophthalmology, Kolar

²Department of Vitreo Retina Shankar Nethralaya, Chennai

ARTICLE INFO

Article History:

Received 27th February, 2016
Received in revised form
16th March, 2016
Accepted 04th April, 2016
Published online 31st May, 2016

Key words:

Diplopia,
Ptosis,
Demyelinating.

ABSTRACT

Aim: The aim of the study is to determine the clinical presentation and document the etiological factors in patients with ocular motor nerve palsy in Kolar region

Materials and methods: All patients with ocular motor nerve palsies at R. L. JALAPPA HOSPITAL attached to SRI DEVARAJ URS MEDICAL COLLEGE, Tamaka Kolar were taken up for this observational study between december 2013 to august 2015. Details of various modes of presentation and etiologies were documented.

Results: A total of 74 patients presented with cranial nerve palsies. There were 44 males and 30 females and mean age was 40.68. Most of the patients came with chief complaints of diplopia (43%) followed by ptosis (23%), headache (19%), diminution of vision (8.1%), fever (12.2%) and eye pain (9.5%). The frequency of distribution of ocular motor nerve palsy was the 3rd cranial nerve was most affected in 31 patients (41.89%), 4th cranial nerve was involved in 4 patients (5.4%) and 6th cranial nerve was involved in 25 patients (33.78%) and multiple cranial nerve palsy were involved in 14 patients (18.2%). The etiology was classified as traumatic in 27 (36.5%), ischemic in 16 (21.6%), tumor in 5 (6.8%), demyelinating in 2 (2.7%), inflammatory in 13 patients and idiopathic in 6 (8.1%) cases.

Conclusion: We studied the clinical presentation and etiological pattern of ocular motor nerve palsies in Kolar region, diplopia was the most common symptom at presentation followed by ptosis. Isolated cranial nerve were more frequently affected among them third nerve was involved in majority and etiology causing third nerve palsy was trauma, second most common nerve involved was sixth cranial nerve and most of them had vascular ischemic etiology. CT/MRI have been performed in 70% of our cases and the probable diagnosis was made in 49%. Hence proving the usefulness of these imaging modalities in ocular motor nerve palsies.

Copyright©2016, Dr. Snehalata et al. This is an open access article distributed under the Creative Commons Attribution License, which permits unrestricted use, distribution, and reproduction in any medium, provided the original work is properly cited.

Citation: Dr. Snehalata, G., Dr. Kanthamani, K., Dr. Nagesha, Dr. Dilip, K., Dr. Jyotsna and Dr. Preeti, B. 2016. "Clinical presentation and etiological pattern in patients with ocular motor nerve palsy in kolar region", *International Journal of Current Research*, 8, (05), 31740-31744.

INTRODUCTION

Ocular motor nerve palsies are commonly encountered in clinical practice and usually express an underlying local or systemic disease. The etiology could vary from a simple benign lesion to life threatening neurological disorders; delayed treatment may result in permanent ocular and neurological deficits. The muscles of the eye are innervated by the third, fourth and sixth cranial nerves. Ocular motor nerve palsies (OMNPs) may be unilateral or bilateral, may involve one or several nerves at the same time and may be obvious or sub clinical.

Lesions in one or more of these cranial nerves results in failure of one or both eyes to move in concert with other eye resulting in characteristic forms of strabismus. The clinical manifestations may differ according to the type and localization of the lesion involving the third, fourth and sixth nerves. In order to find out the etiology, it is important to carry out a detailed history taking, a careful clinical examination, as well as complementary investigations. To increase the chance of identifying the causes of OMNPs, a close collaboration between different specialists has been recommended. MRI has clearly shown that brain stem lesions (infarct in nucleus and fasciculus of 3 cranial nerve) mimic as peripheral nerve palsy, the treatment of both of which is entirely different. In this regard, there exists scarcity of knowledge on these neuro-ophthalmological conditions which is limited to few of

*Corresponding author: Dr. Snehalata,
Department of Ophthalmology, Kolar

treatment options. There is also a huge lacunae in the literature in understanding the exact etiology, clinical features and also in utility of advanced neuroimaging modalities to better delineate these clinical entities. Hence we undertook this study to find out the clinical presentation and etiological factors of ocular motor nerve palsies with clinical approach, appropriate investigations and advanced imaging modalities, addressing its role in diagnosis and proper management.

MATERIALS AND METHODS

Source of Data: All patients with ocular motor nerve palsies at R. L. JALAPPA HOSPITAL attached to SRI DEVARAJ URS MEDICAL COLLEGE, Tamaka Kolar were taken up for this observational study between december 2013 – august 2015.

Sample size: A total number of 74 patients with ocular motor nerve palsy were selected for the study

Inclusion Criteria: All conscious patients of ocular motor nerve palsies, isolated III, IV or VI cranial nerve or multiple.

Statistical analysis

Data were analyzed using the stastical program for social science (SPSS) software. Comparison of variables were done by Chi-Square test. $p < 0.05$ will be considered significant.

Techniques of Examination: Patients with paralytic squint who fulfilled the above criteria were enrolled in the study and details regarding their name, age, sex, symptoms, and its duration and any change in the symptoms between their presentation and their onset have been recorded. Detailed history regarding the incidences that preceded the onset of symptoms like trauma [trivial or severe], headache fainting attacks, numbness, etc., were taken. Past history of any episodes of similar nature and the treatment given for the same has been noted. History of systemic illnesses like hypertension, diabetesmellitus, thyroid abnormalities, and seizure disorder and previous neurological involvement in any other disorders like tuberculosis, syphilis were noted. History specific to ocular complaints such as double vision, blurring of vision, field defects, and vestibular complaints like vertigo, tinnitus, ear discharge have been recorded. Personal history regarding smoking, alcohol intake and diet pattern were asked and recorded.

Ophthalmic examination included visual acuity assessment with snellen chart, anterior segment evaluation by slit-lamp biomicroscope, fundus by ophthalmoscopy. Ocular movements both unocular and binocular were examined in all cardinal gazes. Amount of deviation of eye were noted and diplopia charting was done. Otorhinolaryngologic examination were performed as and when required. A complete haemogram, urine analysis for albumin, sugar, and deposits, blood sugar VDRL, mantoux test, X-ray of skull (both anteroposterior and lateral) and paranasal sinuses were done in patients as and when indicated. CT-scan was done in almost all trauma cases and in other cases when there was need. MRI-scan was done depending on necessity of individual case. Certain special tests

like icepack test has been done in certain cases to diagnose and to differentiate myasthenia gravis from nerve palsies. Follow up of these cases has been done at the end of 4 weeks, 8weeks, 12weeks, and 6 months. The etiology of the ocular motor nerve palsies were classified into different categories like ischemic, traumatic, aneurysmal, neoplastic, demyelinating, raised intracranial pressure and idiopathic. The clinical presentation of ocular motor nerve palsies were described in terms of laterality of palsies, single or multiple ocular motor nerve palsies, frequency of involvement of nerves, isolated lesions or associated with other neurological signs & symptoms

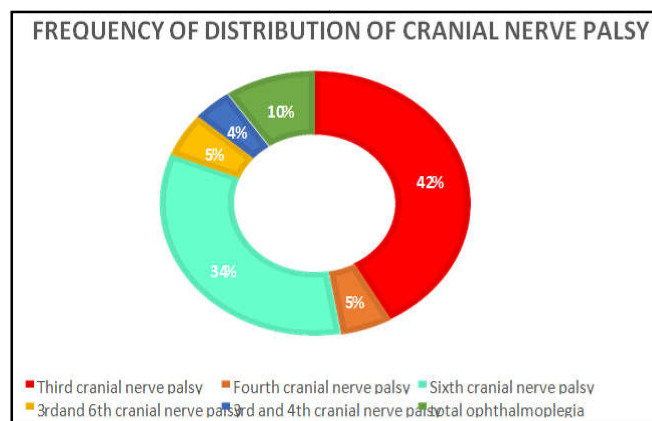
OBSERVATION AND RESULTS

A total of 74 patients presented with cranial nerve palsies in this prospective study. There were 44 males and 30 females and the male to female ratio was 1.4:1. The mean age of the patients was 40.68 ± 17.43 (range 7 years to 75 years) Most of the patients were between 31 years and 40 years. The most common symptom presented was diplopia seen in 32(43.2%) patients; this was followed by diminution of vision in 22(29.7%), drooping of upper eyelid in 19(25.7%), headache in 19(25.7%), fever in 9(12.2%).

The relationship between the underlying disorders / systemic association with cranial nerve palsy included diabetes mellitus 11 patients (14.9%), systemic hypertension 2 patients (2.7%) and bronchial asthma 2 patients (2.7%) Among the patients studied thirty two patients (43.2%) had ptosis, six patients (8.1%) had exotropia, twelve patients (16.2%) had esotropia, four patients (5.4%) had proptosis, fixed and dilated pupil was seen in 13 patients (17.6%), hypertropia was seen in 4 patients (5.4%), ecchymosis, chemosis and subconjunctival hemorrhage were seen more associated with trauma history in 14, 7 and 11 patients respectively

Graph represents the frequency of distribution of cranial nerve palsy.

The 3rd cranial nerve was affected in 31 patients, 4th cranial nerve was involved in 4 patients and 6th cranial nerve was involved in 25 patients. The 3rd and 6th cranial both nerves were affected in 3 patients, 3rd and 6th cranial nerves both involvement were observed in 4 patients, all the three cranial nerves (3rd, 4th, 6th) were involved in 7 patients.



Most cranial nerve palsies were associated with normal pupillary reaction. Only 30 patients were associated with pupil involvement. Patients with 3rd and multiple cranial nerve palsies had sluggishly reactive pupils and in some pupil was dilated and fixed. Right eye was involved in majority of the patients accounting for 48(64.9%) and left eye in 31(41.9%) and both eye was involved in 6 patients (8.1%).

CT/MRI of the study

Neuroimaging (CT, MRI or MRA) was performed for 53 (71.8%) patients and revealed an abnormality in 36 cases (48.6%) it included intracranial tumors, non-neoplastic space occupying lesions, ischemic and demyelinating lesion. Neuroimaging was normal in the remaining 17 patients (23%).

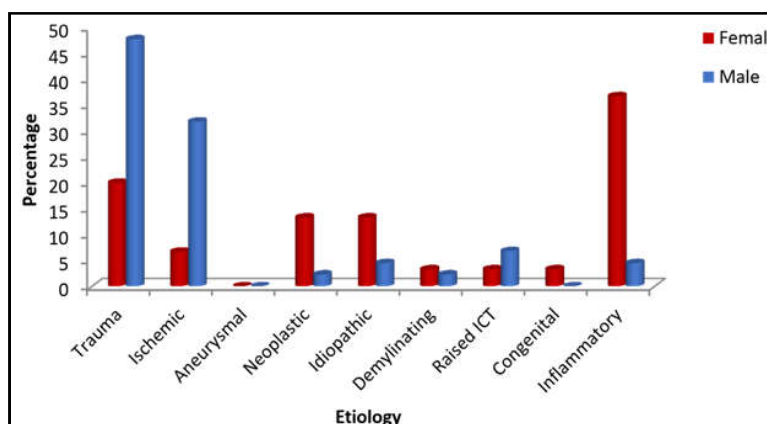
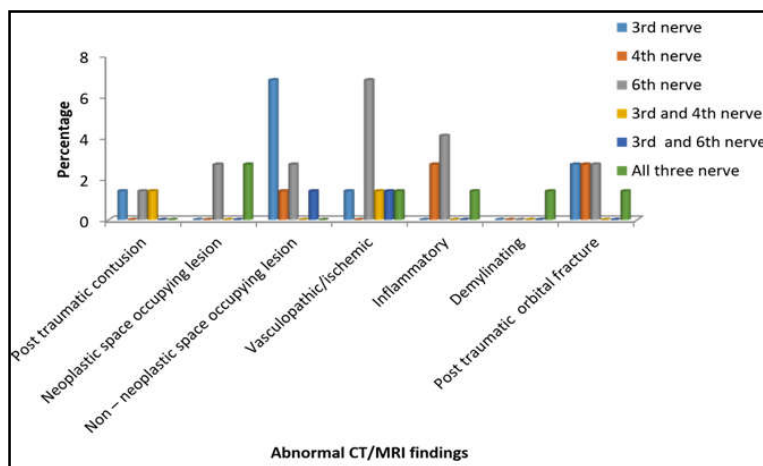
	Pedro edge <i>et al</i>	Rowe <i>et al</i>	Present study
Mean age and Range	34.50 ± 18.41 years (range, 4-75 years)	69.18 ± 14.19 years (range, 1-94 years).	40.68±17.43 years (range, 7-75 years)

	Pedro edge <i>et al</i>	Tabassi <i>et al</i>	Present study
Male : Female ratio	0.8:1	1.5:1	1.4:1

Chief complaint	Mwanza <i>et al</i>	Tabassi <i>et al</i>	Pedro dge <i>et al</i>	Present study
Diplopia.	11(35.4%)	3(10.7%)	7(21.2%)	32(43.2%)
Drooping of eyelid.	7(22.5%)	22(78.6%)	4(12.2%)	17(23%)
Diminution of vision.	4(12.9%)	3(10.7%)	2(6%)	22(29.7%)
Headache.	-	13(46.7%)	7(21.2%)	19(25.5%)

Cranial nerve	Menon	Mwanza	Rama	Rucker	Rucker	Rush	Present study
III	63(31.9%)	11(35%)	28(40%)	33.5%	27.4%	29.0%	31(41.89%)
IV	12(6%)	04(12.9%)	1(1.4%)	6.7%	8.4%	17.2%	04(5.4%)
VI	88(44.6%)	12(38%)	29(41%)	40.9%	51.5%	41.9%	25(33.78%)
Multiple	24(12%)	06(19.3%)	32(8%)	18.9%	12.7%	11.9%	14(18.9%)

Etiology	Rama <i>et al</i>	Present study
Inflammatory	19(21.11%)	13(17.6%)
Intracranial neoplasia	16(17.77%)	5(6.8%)
Head injury	16(17.77%)	27(36.5%)
Vascular	13(14.44%)	16(21.6%)
Idiopathic	6(6.66%)	6(8.1%)
Miscellaneous	13(14.44%)	7(9.5%)



The final diagnosis was classified as traumatic in 27(36.5%), ischemic in 16(21.6%), tumor in 5 (6.8%), demyelinating in 2 (2.7%), inflammatory in 13 patients and idiopathic in 6 (8.1%) cases. Among patients with ischemic etiology, 9 (32.1%) had diabetes mellitus and 3 (10.7%) had systemic hypertension, one patient had history of a cerebrovascular accident. Neuroimaging (CT, MRI or MRA) was performed for 53 patients (71.8%) and revealed an abnormality in 36 cases (48.6%) which included intracranial tumors, non-neoplastic space occupying lesions, ischemic and demyelinating lesion, neuroimaging was normal in the remaining 17 patients (23%).

DISCUSSION

Over a period of one and half year of study duration, 74 cases of ocular motor nerve palsies were seen. Our results show that most of the patients were between 31 and 40 years of age with a mean of 40.68 ± 17.43 years (range, 7-75 years). This was similar to study done in Nigeria by Pedro-edge *et al* where mean age of presentation was 34.50 ± 18.41 years (range, 4-75 years). This differs from a study by Rowe *et al.* (1995) where the mean age of patients was 69.18 ± 14.19 years (range, 1-94 years). This difference is not surprising since Rowe *et al* (1995) study involved only stroke patients which may have accounted for the older age group as the risk factors to developing a stroke are greater in older individuals.

Male to female ratio of ocular motor nerve palsy

The male to female ratio in our study was 1.4:1, similarly it was 1.5:1 in a study by Tabassi *et al.* done at Iran which was carried out to know the etiology of third nerve, The results differs from a study by Pedro edge *et al.*, where the male to female ratio was 0.8:1

Chief complaints at presentation of ocular motor nerve palsy

The most common symptom at presentation were double vision, defective vision, fever, headache and ptosis. Diplopia and ptosis are in keeping with the functions of some of the affected cranial nerves. The patient with fever, eye pain, and headache and neck stiffness had inflammatory causes like meningitis, neurotuberculosis, herpes zoster ophthalmicus, HIV. This study showed that diplopia 32(43.2%), which is an extremely disturbing phenomenon, remains the most common symptom at presentation which is comparable with Mwanza *et al* were diplopia was seen in 11(35.4%) patient. In our study, most patients (87.5%) had horizontal diplopia. This was expected as the 3rd and 6th cranial nerves were the most affected. This results differ from study by Tabassi *et al* were drooping of upper eyelid was the chief complaint seen in 22 (78.6%) patients and diplopia was seen in least number of cases. This can be accounted as in our study as patients with mild ptosis may not be aware of the abnormality and they would not come to seek treatment for it, so any doubt arise on the presence or absence of ptosis in a case of third cranial nerve palsy, objective measurements should be done. In our study headache was seen in 19(25.5%) cases it is comparable with both the study by Pedro edge *et al* and Tabassi *et al.*

The frequency of distribution of ocular motor nerve palsies was compared with both Indian and western countries

The incidence of isolated III cranial nerve involvement was similar to all the studies previously done, even though paralysis of the sixth cranial nerve is recognized as the most common type in most of the series throughout the literature (Menon, Mwanze, Rama), the third cranial nerve was the most affected in our study. The sixth nerve affection seen in 33% was lower in our study when compared to other series. The IV nerve was involved in 4 patients (5.4%) affection were similar to Rama *et al.*, Menon *et al.*, Rucker1 *et al.* The incidence of combined nerve palsies in various combinations were seen in 14 patient (18.9%) was higher in our series compared to other studies previously done.

Etiology of the patients with ocular motor nerve palsy

Head injury 27(36.5%) is one of the common causes of ocular motor palsy in our study in comparison to the study by Rama *et al* and Rucker in which head trauma accounted only in 18% of cases, our study had higher incidence of trauma as this region is more close towards the highway and prone for road traffic accident. The mechanism of traumatic abducent nerve palsy may be direct mechanical injury to the nerve or an indirect injury. The indirect injury results from nerve ischemic change due to vessel compression or vasospasm. (Rowe, 2011; Tabassi *et al.*) The three cranial nerves (3rd, 4th and 6th) are fed by a comprehensive network of arterial blood vessels, and thus are susceptible to vascular compromise particularly localized lesions and disturbances at the level of the brainstem cranial nerve nuclei as well as in the cavernous sinus just before innervating the extraocular muscles. Rowe *et al.* (1995) Inflammatory etiology like neuroinfection, tuberculoma, herpes zoster ophthalmicus, Human immunodeficiency virus infection, meningitis were seen in 13 patients. In comparison to Rama *et al* were inflammatory cause was the most common casuse as the study was conducted at Rayalaseems area i.e., former Ceded Districts of Andhra Pradesh Is an entity which accounts for over a third of neurological problems in the region.

Vascular lesions like 16(21.6%) diabetes was the underlying cause in most of the OMNP(80%) 11 out of 16 had diabetes, two patients had hypertension., It is comparable with Berlit *et al* and Mosterwere OMNP of vascular origin (29.7%) was the most common, followed by inflammatory disease (19.4%) and tumors (10.9%). Moster also said that the vascular group was involved in older compared to the younger group. Five cases of intracranial neoplasia were seen in the present study accounting for 6.8% the incidence were less when compared to Rama Rucker while it was similar to Krishna's series Not even a single case of aneurysm was detected in our study as an etiology of ophthalmoplegia. The incidence was very high (7.7%) in Rucker's series Krishna and Mehkrialso reported only 4 cases (2.2%). This might not reflect the true incidence of aneurysm in general as there have been other cases which manifested mainly as subarachnoid haemorrhage.

In every case series a proportion of patients remained whose pathogenesis was unknown. In our study seven patients, the etiology could not be established. The third nerve alone was affected in three of them, while the third and sixth were

involved in one case and total ophthalmoplegia were seen in two patients of unknown etiology. Rucker found 211 of 1000 cases (21%) while Krishna and Mehkri found 18% of undetermined etiology. The incidence in our study was lower. No definite explanation could be offered for this. Associated vision loss was found in 8 patients, they had optic atrophy due to optic nerve involvement clinically evident as relative afferent pupillary defect, V, VII and VIII nerve were involved in three patients with multiple cranial nerve palsies. These associated findings were correlating with Menon's study.

Conclusion

We studied the clinical presentation and etiological pattern of ocular motor nerve palsies in Kolar region, diplopia was the most common symptom at presentation followed by ptosis. Isolated cranial nerve were more frequently involved in our study among them third nerve was seen in majority of cases and etiology causing third nerve palsy was trauma in most cases, second most common nerve involved was sixth cranial nerve and most cases of 6th cranial nerve palsy were related to systemic disorders such as diabetes mellitus, hypertension. Trauma was found to be the major etiological factor for multiple cranial nerve palsies followed by neoplasia and demyelination, optic nerve was involved in majority of the patients in our study. CT/MRI have been performed in 70% of our cases and the probable diagnosis was made in 49%. Hence proving the usefulness of these imaging modalities in ocular motor nerve palsies. Ocular motor nerve palsy patients with systemic risk factors like diabetes, hypertension can be managed initially with close observation. Imaging is needed for all those ocular motor nerve palsy patient who do not show improvement after the acute stage >2weeks, or develop neurologic findings, or in those patients without resolution after 12 to 16 weeks.

REFERENCES

Berlit, P. 1991. Isolated and combined pareses of cranial nerves III, IV and VI. A retrospective study of 412 patients. *J NeurolSci*, 03:10–15.

- Kim, J.S., Kang, J.K., Lee, S.A. 1993. Isolated or predominant ocular motor nerve palsy as a manifestation of brain stem stroke; 24:581-586.
- Krishna, A.G., Mehkri, M.B. 1973. *India Neurol Suppl.* IV; 20: 584.
- Menon, V., Singh, J., Prakash, P. 1981. Aetiological patterns of ocular motor nerve palsies. *Indian Journal of Ophthalmology*, 99:76–79.
- Moster, M.L., Savino, P.J., Sergott, R.C., Bosley, T.M., Schatz, N.J. 1984. Isolated sixth-nerve palsies in younger adults. *Arch Ophthalmol*, 102:45-9
- Mwanza, J.C., Ngweme, G.B., Kayembe, D. 2006. Ocular motor nerve palsy: A clinical and etiological study. *Indian J Ophthalmol*; 54:173-5.
- Oczna, K., Zielińska, A.K., 1995. Krzystkova KM, Madroszkiewicz A, Wójcik E, Filipowicz E. Principles and results of treatment in acquired paralysis of III, IV and VI nerves;97:147-51.
- Pedro edge, C.N., Fiebai, B., Awoyesuku, E.A. 2014. A 3 year review of cranial nerve palsies from the university of port Harcourt teaching eye clinic, Nigeria. *Middle east African Journal of Ophthalmology*, 21(2):170-74.
- Rama, V., Vimala, J., ChanderShekhar, M., Anjaneyulu, C., Dinakar, I. 1980. *J Ophthalmol.*, 15:
- Richards, B.W., Jones, F.R., Younge, B.R. 1992. Causes and prognosis in 4,278 cases of paralysis of the oculomotor, trochlear, and abducens cranial nerves. *Am J Ophthalmol*; 113:489496.
- Rowe, F. 2011. Prevalence of ocular motor cranial nerve palsy and associations following stroke. *Eye(Lond)*; 25:881–7.
- Rucker, C.W. 1958. Paralysis of the third, fourth and sixth cranial nerves. *Am J Ophthalmol.*, 46:787–794.
- Rucker, C.W. 1966. The causes of paralysis of third, fourth and sixth cranial nerves. *Am J Ophthalmol.*, 61:293-98 .
- Rush, J.A., Younge, B.R. 1981. Paralysis of cranial nerves III, IV, and VI. Cause and prognosis in 1,000 cases. *Arch Ophthalmol*, 99:76-79.
- Tabassi, A.R., Dehghani, A.R., Mosayebi, H. Etiology of Oculomotor Nerve Paralysis. Tehran University of Medical Sciences, Tehran, Iran
