



CASE REPORT

TUBERCULOUS RADICULOMYELITIS COMPLICATING TUBERCULOUS MENINGITIS

Dr. Nabeel Mushtaque Ahmed, *Dr. Vinay Pandey and Dr. Ashish Srivastava

Department of Medicine, JNMC AMU, Aligarh, India

ARTICLE INFO

Article History:

Received 05th January, 2016
Received in revised form
10th February, 2016
Accepted 17th March, 2016
Published online 26th April, 2016

Key words:

Ulcer, Dog, Stomach, Omentum.

ABSTRACT

Tuberculous radiculomyelitis (TBRM) is a complication of tuberculous meningitis (TBM), which has been reported rarely in the modern medical literature. We describe a case of TBRM that developed in an human immunodeficiency virus (HIV)-infected patient, despite prompt antituberculous treatment. The most common symptoms are subacute paraparesis, radicular pain, bladder disturbance, and subsequent paralysis. CSF evaluation usually shows an active inflammatory response with a very high protein level. MRI and CT scan are critical for diagnosis, revealing loculation and obliteration of the subarachnoid space along with linear intradural enhancement. As in other forms of paradoxical reactions to antituberculous treatment, there is evidence that steroid treatment might have a beneficial effect.

Copyright © 2016, Dr. Nabeel Ahmed et al. This is an open access article distributed under the Creative Commons Attribution License, which permits unrestricted use, distribution, and reproduction in any medium, provided the original work is properly cited.

Citation: Dr. Nabeel Mushtaque Ahmed, Dr. Vinay Pandey and Dr. Ashish Srivastava, 2016. "Tuberculous radiculomyelitis complicating tuberculous meningitis", *International Journal of Current Research*, 8, (04), 29518-29523.

INTRODUCTION

Tuberculous radiculomyelitis (TBRM) is a complication of neurological tuberculosis that is rarely reported, even in countries where tuberculosis of the CNS is common (Naidoo *et al.*, 1991). Wadia and Dastur, in their important review of TBRM (Wadia *et al.*, 1969), have suggested that the designation "TBRM" be used as a generic term to include cases previously categorized as arachnoiditis, intradural spinal tuberculoma or granuloma, and spinal cord complications of TBM. Here we report a case of TBRM complicating TBM in an HIV-infected patient and review the literature on TBRM.

CASE REPORT

A 27-year-old man presented to our Medicine Opd, JNMC because of subacute onset of bilateral lower limb weakness. The patient was a former injection drug abuser who had tested positive for HIV 4 years earlier. He was naive for antiretroviral treatment. Three months before presentation, he had been admitted to our hospital because of headache, fluctuating mental status, fever, marked neck stiffness, and bilateral sixth cranial nerve paresis. A lumbar puncture was performed (Table 1). PPD test was negative, and his CD4 cell count was 54×10^6 cells/L.

*Corresponding author: Dr. Vinay Pandey

Department of Medicine, JNMC AMU, Aligarh, India

The patient was started empirically on antituberculous drugs (isoniazid, rifampin, and ethambutol) the same day of admission. The patient indicated that after he was discharged from the hospital he slowly developed progressive lower limb weakness with difficulty walking and bladder disturbance. According to the patient and his family, compliance with antituberculous therapy had been excellent. Neurological examination showed absent lower limb deep tendon reflexes. Muscle strength was clearly decreased (3/5), both proximally and distally. Left plantar response was extensor and right was equivocal. Truncal weakness was present. There was a slight distal pinprick and light touch sensory deficit in the legs, suggestive of a lesion at the T10 root level and bladder sphincteric disturbance. Another lumbar puncture was performed 102 days after the patient presented with tuberculous meningitis (Table 1). Findings of chest, and thoracic and lumbar spine radiographs were normal as were those of contrast-enhanced CT of the brain. AT1-weighted sagittal MRI of the spine (Figure 1), with and without gadolinium, showed thickening of the dorsal meninges with obliteration of the posterior subarachnoid spaces surrounding the cervical, thoracic, and lumbar spinal cord. There was posterior enhancement of the cervical and thoracic spinal cord meninges, loculation, and obliteration of the spinal subarachnoid space. In addition, several nodular-enhancing lesions in the thoracic spine, consistent with subarachnoid tuberculomas, were demonstrated. MRI did not show signs of vertebral osteomyelitis.

Table 1. CSF characteristics in a patient with tuberculous meningitis complicated by tuberculous radiculomyelitis

	At presentation with	102 days after starting
CSF	Tuberculous meningitis	TB treatment
WBC count, cells/mL	320 (35% PMN, 65% L)	3
Glucose level, g/L	0.02	0.38
Protein level, g/L	2.20	2.44
ADA	17.4 U/L	9.3
AFB staining	Negative	Negative

NOTE. ADA, adenosindeaminase; AFB, acid-fast bacilli; L, lymphocytes; PMN, polymorphonuclear cells; TB, tuberculosis.

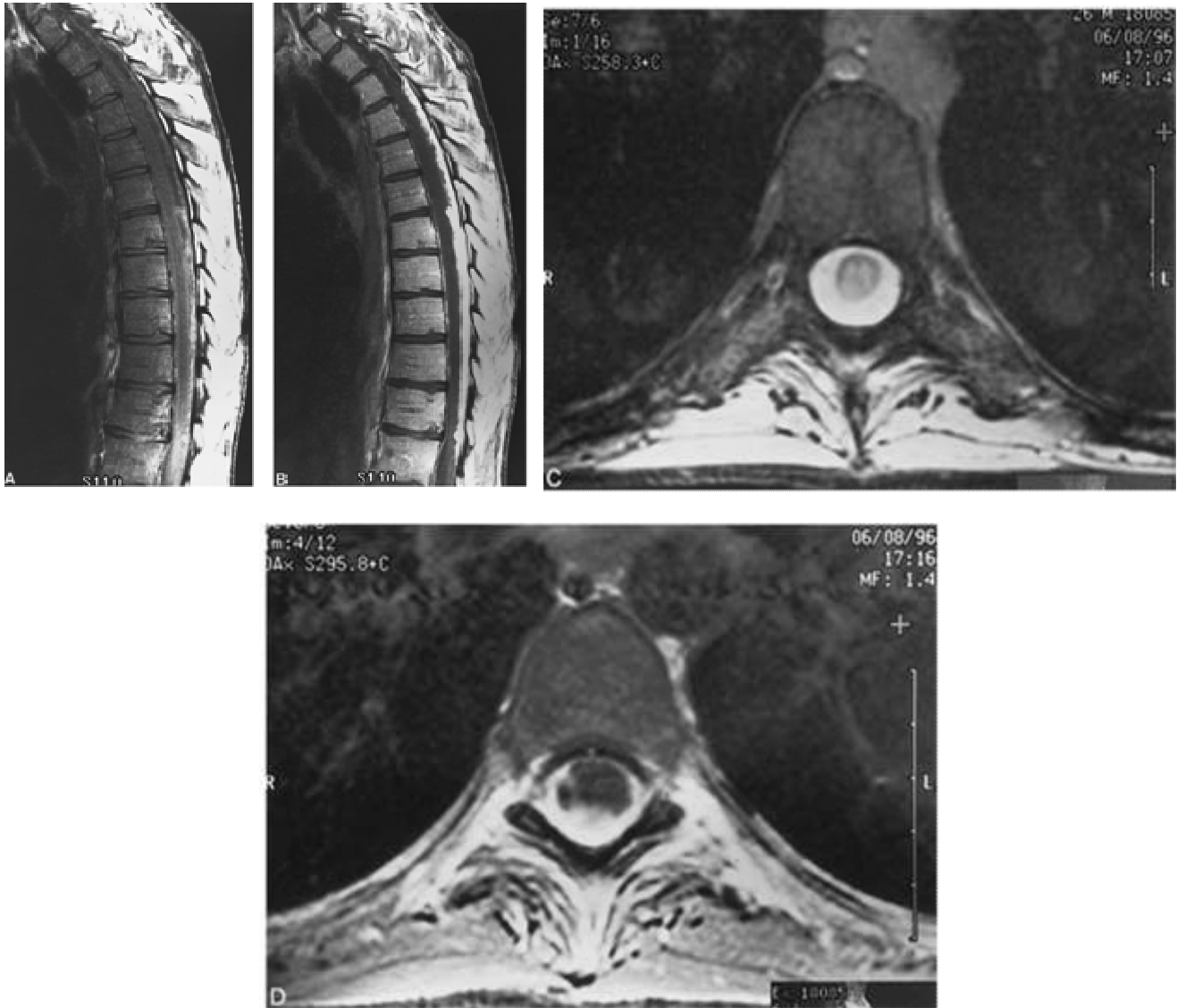


Figure 1. MRI performed at presentation. *A* and *B*, Sagittal spine echo T1-weighted MR image before and after administration of iv gadolinium-DTPA, showing marked meningeal thickening with intense enhancement of the entire subarachnoid space indicating arachnoiditis. *C* and *D*, Axial T1- and T2-weighted spin and fast spin echo images showing diffuse enhancement of dura-arachnoid complex around cord. T2 sequence shows increased signal intensity of cord indicative of medullar damage

The clinical and radiological features were consistent with TBRM. Methylprednisolone (45 mg daily) was added to the therapeutic regimen. During the following month, there was improvement in the lower extremity strength to the point that the patient could walk without support. There was no change in bladder disturbance. Four months after presentation (Figure 2), another MRI revealed a syringomyelic cavity

involving the thoracic and lumbar spinal cord (from the second thoracic vertebra to the conus medullaris) with minimal meningeal enhancement after contrast administration. Antituberculous treatment and steroid therapy were maintained for 12 and 10 months, respectively. The patient did not receive antiretrovirals before finishing antituberculous treatment.

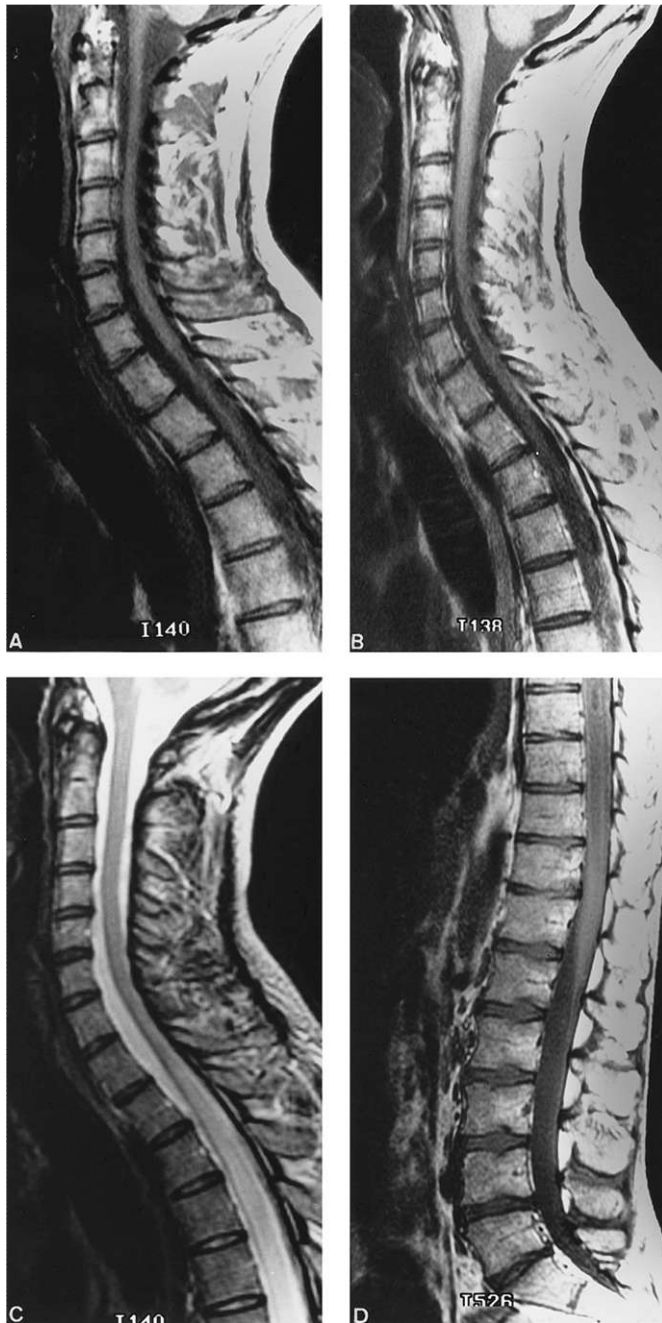


Figure 2. MRI performed 4 months after treatment. *A* and *B*, Sagittal spine echo T1-weighted MR image before and after administration of iv gadolinium-DTPA, showing minimal meningeal enhancement and a low intensity intramedullary lesion. *C* and *D*, Sagittal spine echo T2-weighted MR image showing a central syringomyelic cavity extending from the T2 level down to the conus medullaris

CD4 cell count at the end of antituberculous treatment was 184×10^6 cells/L. At that point, the patient started a regimen of stavudine, lamivudine, and indinavir. The patient has been followed for 1 year after presentation. There has been no significant change in his neurological status during the last 1 year.

Discussion and Review

Pathogenesis. TBRM may develop in 1 of 3 ways: (1) as a primary tuberculous lesion (i.e., the first expression of

tuberculosis of the CNS); (2) as a downward extension of TBM; and (3) as a secondary extension from vertebral tuberculosis. Myelopathy with spinal subarachnoid obstruction secondary to tuberculourachnoiditis was first described by Sir Victor Horsley (Horsley, 1909). Although for a long period TBRM was considered a complication of vertebral tuberculosis, in 1947, Ransome and Montiero reported 4 patients from Singapore in whom tuberculomyelopathy occurred in the absence of Pott's disease (Ransome, 1947). **Pathology.** Macroscopically, one of the most remarkable features of TBRM is the presence of an exudate that is usually described as extensive, copious, and tenacious. The entire space between the spinal dura mater and the leptomeninges can be occupied and expanded by this exudate (Dastur *et al.*, 1995). The exudate can produce partial or complete encasement of the spinal cord, with impingement of spinal roots. In addition, thrombosis of the anterior spinal artery that produces cord infarction has been described elsewhere (Dastur, 1969; Villoria *et al.*, 1995; Sheller, 1986). Microscopically, the main pathological feature of TBRM is the presence of a granulomatous reaction of the spinal leptomeninges frequently associated with histiocytic proliferation, vasculitis caseation, and tubercle formation (i.e., frank giant cell systems with necrotic centers and epithelioid cells) (Dastur, 1969).

Clinical findings: The clinical features of TBRM have been well described (Wadia and Dastur, 1969). TBRM is characterized by the subacute onset of paraparesis that progresses over 1 or 2 months. Symptoms include root pain, paraesthesias, bladder disturbance, and muscle wasting; subsequent paralysis develops, usually after a few days. It is not uncommon to find absent deep tendon reflexes with flaccidity in the lower limbs and the presence of extensor plantar response (Wadia, 1973). Secondary radiculomyelitis may appear during the acute stage or after variable periods since the onset of TBM. Kozlowski (Kozlowski, 1963) described 2 cases of adhesive arachnoiditis that developed 7 and 9 years, respectively, after TBM. In another series, 2 patients with paraparesis that occurred 14 and 17 years, respectively, after TBM were reported (Chang *et al.*, 1989). It is possible that TBRM, in some of the cases with a long delay between TBRM diagnosis and TBM, was diagnosed on the basis of a long-term complication of TBRM, such as the development of a syringomyelic cavity. Although spinal extension of tuberculous basal meningitis usually develops within weeks of starting inadequate antituberculous treatment (Wadia, 1973), radiculomyelopathy can also develop during appropriate treatment of intracranial tuberculosis (Freilich, 1979; Wadia, 1973; Teoh *et al.*, 1987; Leonard *et al.*, 1990). In most patients with TBRM, evaluation of CSF reveals an active inflammatory response with pleocytosis (lymphocytosis), hypoglycorrhachia, and a very high protein level (probably the result of CSF flow blocks). It should be noted that these alterations could persist despite sterilization of the CSF (as it happened in our case). Diagnosis of TBRM is usually suspected on the basis of clinical and CSF findings, as well as with typical myelographic, CT, or MRI appearance (Gupta *et al.*, 1994; Sharma *et al.*, 1997). In our patient, the presentation of TBRM was similar to the clinical picture described by others (Wadia, 1969; Dastur, 1969; Woolsey *et al.*, 1988; Lin *et al.*, 1994; Brooks *et al.*, 1954). The initial

TBM was followed by extension of the inflammatory process to the spinal cord and nerve roots, manifesting as paraparesis and areflexia. In non-immunosuppressed patients, the thoracic spinal cord is most frequently involved (Chang *et al.*, 1989; Gupta *et al.*, 1994; Sharma *et al.*, 1997). Our patient was HIV-infected. In our review, we found only 1 other case of TBRM associated with HIV-infection (Woolsey *et al.*, 1988). Patients coinfecting with HIV and tuberculosis are at high risk for developing TBM. In fact, the risk of CNS involvement in patients with tuberculosis is 5 times higher if the patient is HIV coinfecting (Berenguer *et al.*, 1992), especially if the HIV has been acquired through injection drug use (Villoria *et al.*, 1995). However, it has been shown that HIV infection does not appear to modify the clinical manifestations and complications of TBM (Berenguer *et al.*, 1992). There are no data to support an increase in the incidence of TBRM in the HIV-infected population.

Radiographic Imaging: CT and MRI are critical for the diagnosis of TBRM. (Chang *et al.*, 1989) compared conventional myelograms, myelo-CT, and MRI with and without administration of contrast medium and concluded that conventional myelography remained the primary radiological method for diagnosis of suspected TBRM, particularly in those cases that are characterized by chronic adhesive changes. They considered, however, that in patients with an active inflammatory process within the thecal sac or with myelopathy, gadolinium enhanced MRI may be the optimal primary imaging technique, obviating myelography. (Gupta *et al.*, 1994) supported MRI as the primary imaging modality in the screening of patients with suspected intraspinal tuberculosis, regardless of the stage of the disease. The MRI features of TBRM include loculation and obliteration of the spinal subarachnoid space, with loss of the outline of the spinal cord in the cervicothoracic spine and matting of the nerve roots in the lumbar region (Chang *et al.*, 1984; Gupta *et al.*, 1994; Kumar *et al.*, 1993; Villoria *et al.*, 1995; Gero *et al.*, 1991). Even when the enhanced MRI appears entirely normal, gadolinium enhanced MRI usually reveals nodular, thick, linear intradural enhancement, often completely filling the subarachnoid space (Chang *et al.*, 1984; Gupta *et al.*, 1994; Kumar *et al.*, 1993; Gero *et al.*, 1991). When TBRM is imaged in a chronic phase, the gadolinium-enhanced images may not show any enhancement, even when unenhanced images show signs of arachnoiditis (e.g., matted nerve roots) (Gupta *et al.*, 1994).

The secondary development of a syringomyelic cavity is a known late complication of some cases (including ours) of tuberculous arachnoiditis (Daif *et al.*, 1997; Fehlings *et al.*, 1992). MRI imaging coupled with iv gadolinium has proved to be more sensitive than enhanced CT in its ability to show abnormal meningeal enhancement in non-AIDS and AIDS patients (Post *et al.*, 1986; Chang *et al.*, 1990; Villoria *et al.*, 2000). Meningeal enhancement is seen in the basal cisterns and over the convexity of the brain in most patients, and is the most direct evidence of the inflammatory reaction to the tuberculous meningeal infection (Villoria *et al.*, 1995). Spinal meningeal enhancement in the cervical and thoracic regions suggests TBRM (Villoria *et al.*, 1995). Our conclusion from the literature review is that the most sensitive method for

radiological evaluation for TBRM is an MRI using T1-weighted sagittal and axial views pre- and post-administration of gadolinium-DTPA. **Treatment.** In patients with TBM, early diagnosis and initiation of therapy is of utmost importance to prevent unnecessary morbidity and mortality (Naidoo *et al.*, 1991; Berenguer *et al.*, 1992; Jinkins *et al.*, 1995). Delayed treatment in cases of TBM may result in severe sequelae. Although the importance of early treatment of TBM cannot be overemphasized, it should be recognized that TBRM, in some cases, might develop "paradoxically" shortly after the start of appropriate treatment for TBM. Some authors have considered that TBRM might represent a form of paradoxical reaction to tuberculosis treatment, as it happened in our case (Rao *et al.*, 1995). In other types of neurotuberculosis, such as intracranial tuberculomas, it has been well described as a paradoxical growth of the tuberculomas during appropriate antituberculous treatment (Afgani and Lieberman, 1994). Possible explanations for these paradoxical reactions are the recovery of the patient's delayed hypersensitivity response and an increase in response to mycobacterial antigens liberated after antituberculous treatment. Steroids have been used in other types of paradoxical tuberculous reactions and consequently they might play a role in the prevention of TBRM in patients treated for TBM.

Steroids have been used to prevent and treat the neurological complications of TBM (Parsons, 1989; Horne, 1966; Escobar *et al.*, 1975). Although it has been suggested that CSF WBC counts and protein content normalize more rapidly with use of steroids, their precise role in treating TBM is still uncertain. Reduction of mortality by corticosteroids in the acute phase of TBM has been reported in several series (Wasz-Hockert, 1962; Udani, 1971;), including small numbers of patients (Kirsell, 1951; Escobar *et al.*, 1975), but not in others (Berenguer *et al.*, 1992). Most investigators consider that steroids are probably beneficial and should be given for 2 neurological complications associated with TBM: cerebral edema and spinal block (Ogawa *et al.*, 1987; Humphries, 1992). Our review found conflicting reports on the efficacy of steroids for the treatment of TBRM (Naidoo *et al.*, 1991; Wadia, 1969; John and Douglas, 1975; Freilich, 1979; Fehlings, 1992). Although we recognize that no randomized controlled trial has been performed, we support the strategy of using full antituberculous therapy along with corticosteroids at presentation of TBRM (Naidoo *et al.*, 1991). The value of decompressive laminectomy remains uncertain (Gime'nez-Rolda, 1974; Vlcek *et al.*, 1984). In the more chronic forms of the disease, a localized area of arachnoiditis or cord compression from a cyst can be surgically treated with good results, but more extensive adhesive disease usually progresses despite laminectomy (Naidoo *et al.*, 1991). In summary, TBRM is a rare complication of TBM. TBRM should be suspected whenever a patient with TBM develops spinal cord symptoms. Neuroimaging with MRI is critical for diagnosis. Given the exuberant nature of the inflammatory process at the spinal level, steroid treatment is probably indicated.

REFERENCES

- Afgani, B., Lieberman, J. M. 1994. Paradoxical enlargement or development of intracranial tuberculomas during therapy. *Clin Infect Dis.*, 19:1092-9.

- Berenguer, J., Moreno, S., Laguna, F., *et al.* 1992. Tuberculous meningitis in patients infected with the human immunodeficiency virus. *N Engl J Med.*, 326:668–72.
- Brooks, W.D.W., Fletcher, A. P., Wilson, R. R. 1954. Spinal cord complications of tuberculous meningitis: a clinical and pathological study. *Q J Med.*, 23:275–90.
- Chang, K. H., Han, M. H., Choi, Y. W., Kim, I. O., Han, M. C., Kim, C. W. 1989. Tuberculous arachnoiditis of the spine: findings on myelography, CT, and MR imaging. *AJNR Am J Neuroradiol*, 10:1255–62.
- Chang, K. H., Han, M. H., Roh, J. K., *et al.* 1990. Gd-DTPA-enhanced MR imaging in intracranial tuberculosis. *Neuroradiology*, 32:19–25.
- Chang, K.H., Han, M. H., Roh, J. K., *et al.* 1990. Gd-DTPA-enhanced MR imaging of the brain in patients with meningitis: comparison with CT. *AJNR Am J Neuroradiol*, 11:69–76.
- Daif, A. K., Al Rajeh, S., Ogunniyi, A., Al Boukai, A., Al Tahan, A. 1997. Syringomyelia developing as an acute complication of tuberculous meningitis. *Can J Neurol Sci.*, 24:73–6.
- Dastur, D. K., Manghani, D. K., Udani, P. M. 1995. Pathology and pathogenetic mechanisms in neurotuberculosis. *Radiol Clin North Am.*, 33:733–52.
- Dastur, D. K., Wadia, N. H. 1969. Spinal meningitides with radiculo-myelopathy. II. Pathology and pathogenesis. *J Neurol Sci.*, 8:261–97.
- De La Blanchardiere, A., Stern, J. B., Molina, J. M., *et al.* 1996. Spinal tuberculous arachnoiditis. *Presse Med.*, 25:1333–5.
- Escobar, J. A., Belsey, M. A., Duenas, A. 1975. Mortality from tuberculous meningitis reduced by steroid therapy. *Pediatrics*, 56:1050–5.
- Escobar, J. A., Belsey, M. A., Duenas, A., Medina, P. 1975. Mortality from tuberculous meningitis reduced by steroid therapy. *Pediatrics*, 56:1050–5.
- Fehlings, M. G., Bernstein, M. 1992. Syringomyelia as a complication of tuberculous meningitis. *Can J Neurol Sci.*, 19:84–7.
- Freilich, D., Swash, M. 1979. Diagnosis and management of tuberculous paraplegia with special reference to tuberculous radiculomyelitis. *J Neurol Neurosurg Psychiatry* 42:12–8.
- Gero, B., Sze, G., Sharif, H. 1991. MR imaging of intradural inflammatory diseases of the spine. *AJNR Am J Neuroradiol*, 12:1009–19.
- Gime'nez-Rolda'n, S., Esteban, A., Benito, C. 1974. Communicating syringomyelia following cured tuberculous meningitis. *J Neurol Sci.*, 23:185–97.
- Go'mez, A. J., Ziegler, D. K. 1966. Myelopathy-arachnoiditis secondary to tuberculous meningitis. *J Nerv Ment Dis.*, 142:94–100.
- Gupta, R. K., Gupta, S., Kumar, S., Kohli, A., Misra, U. K., Gujral, R. B. 1994. MRI in intraspinal tuberculosis. *Neuroradiology*, 36:39–43.
- Horne, N. W. 1966. A critical evaluation of corticosteroids in tuberculosis. *Adv Tuberc Res.*, 15:1–54.
- Horsley, V. 1909. Chronic spinal meningitis: its differential diagnosis and surgical treatment. *BMJ*, 1:513–7.
- Humphries, M. 1992. The management of tuberculous meningitis. *Thorax*, 47: 577–81.
- Jenkins, J. R., Gupta, R., Chang, K. H. 1995. Rodriguez-Carbajal J. MR imaging of central nervous system tuberculosis. *Radiol Clin North Am.*, 33: 771–86.
- John, J. F., Douglas, R. G. 1975. Tuberculous arachnoiditis. *J Pediatr.*, 86:235–7.
- Kato, M., Mochizuki, T., Negaro, K., Fukusako, T., Nogaki, H., Morimatsu, M. 1997. Magnetic resonance imaging of a case of central nervous system tuberculosis with tuberculous arachnoiditis and multiple tuberculomas. *Nippon Ronen Igakkai Zasshi*, 34:818–24.
- Kirsell, L. W. 1951. The clinical application of pituitary adreno-corticotrophic and adrenal steroid hormones. *Ann Intern Med.*, 35:615–8.
- Kozlowski, K. 1963. Late spinal blocks after tuberculous meningitis. *AJR Am J Roentgenol.*, 90:1220–6.
- Kumar, A., Montanera, W., Willinsky, R., TerBrugge, K. G., Aggarwal, S. 1993. MR features of tuberculous arachnoiditis. *J Comput Assist Tomogr*, 17: 127–30.
- Leonard, J. M., Des Prez, R. M. 1990. Tuberculous meningitis. *Infect Dis Clin North Am.*, 4:769–87.
- Lin, S. K., Wu, T., Wai, Y. Y. 1994. Intramedullary spinal tuberculomas during treatment of tuberculous meningitis. *Clin Neurol Neurosurg*, 96:71–8.
- Naidoo, D. P., Desai, D., Kranidiotis, L. 1991. Tuberculous meningo myelo radiculitis: a report of two cases. *Tubercle* 72:65–9.
- Ogawa, S. K., Smith, M. A., Brennessel, D. J., Lowy, F. D. 1987. Tuberculous meningitis in an urban medical center. *Medicine (Baltimore)* 66:317–26.
- Parsons, M. 1989. The treatment of tuberculous meningitis. *Tubercle*, 70:79–82.
- Post, M. J., Sheldon, J. J., Hensley, G. T., *et al.* 1986. Central nervous system disease in acquired immunodeficiency syndrome: prospective correlation using CT, MR imaging, and pathologic studies. *Radiology*, 158:141–8.
- Post, M.J.D., Sheldon, J.J., Hensley, G.T., *et al.* 1986. Central nervous system diseases CID 30 (June) Tuberculous Radiculomyelitis After Tuberculous Meningitis 921 in acquired immunodeficiency syndrome: prospective correlation using CT, MR imaging and pathologic studies. *Radiology*, 1986; 158:141–8.
- Ransome, G. A., Montiero, E. S. 1947. A rare form of tuberculous meningitis. *BMJ*, 1:413–4.
- Rao, G. P., Nadh, B. R., Hemaratnan, A., Srinivas, T. V., Reddy, P. K. 1995. Paradoxical progression of tuberculous lesions during chemotherapy of central nervous system tuberculosis. *J Neurosurg*, 83:359–62.
- Schapira, M., Presas, J. L., Speiser, E., Klimovsky, S., Barro, A., Nogues, M. 1992. Paraplegia aguda y cavitacio'n intramedular en un paciente con tuberculosis pulmonar. *Medicina (B Aires)* 52:560–2.
- Sharma, A., Goyal, M., Mishra, N. K., Gupta, V., Gaikwad, S. B. 1997. MR imaging of tubercular spinal arachnoiditis. *AJR Am J Roentgenol*, 168:807–12.
- Sheller, J. R., Des Prez, R. M. 1986. CNS Tuberculosis. *Neurol Clin*, 4:143–58.
- Teoh, R., Humphries, M. J., O'Mahony, G. 1987. Symptomatic intracranial tuberculoma developing during treatment of tuberculosis: a report of 10 patients and review of the literature. *Q J Med.*, 63:449–60.

- Udani, P. M., Parekh, U. C., Dastur, D. K. 1971. Neurological and related syndromes in CNS tuberculosis: clinical features and pathogenesis. *J NeurolSci.*, 14:341-57.
- Villoria, M. F., De la Torre, J., Fortea, F., Muñoz, L., Hernández, T., Alarcón, J. J. 1992. Intracranial tuberculosis in AIDS: CT and MRI findings. *Neuroradiology*, 34:11-4.
- Villoria, M. F., Fortea, F., Moreno, S., Muñoz, L., Manero, M., Benito, C. 1995. MR imaging and CT of central nervous system tuberculosis in the patient with AIDS. *RadiolClin North Am* 1995; 33:805-20.
- Vlcek, B., Burchiel, K. J., Gordon, T. 1984. Tuberculous meningitis presenting as an obstructive myelopathy. *J Neurosurg*, 60:196-9.
- Wadia, N. H. 1973. Radiculomyelopathy associated with spinal meningitis (arachnoiditis) with special reference to the spinal tuberculous variety. In: Spillane JD, ed. Tropical neurology. Oxford: Oxford University Press.
- Wadia, N. H., Dastur, D. K. 1969. Spinal meningitides with radiculo-myelopathy. I. Clinical and radiological features. *J NeurolSci.*, 8:239-60.
- Wasz-Hockert, O. 1962. Late prognosis in tuberculous meningitis. *ActaPaediatr*, 51:1-119.
- Woolsey, R. M., Chambers, T. J., Chung, H. D., McGarry, J. D. 1988. Mycobacterial meningomyelitis associated with human immunodeficiency virus infection. *Arch Neurol*, 45:691-3.
