



ISSN: 0975-833X

Available online at <http://www.journalcra.com>

International Journal of Current Research
Vol. 8, Issue, 06, pp.32735-32737, June, 2016

INTERNATIONAL JOURNAL
OF CURRENT RESEARCH

RESEARCH ARTICLE

SARCOIDOSIS: RARE MANIFESTATIONS AND DIAGNOSTIC DILEMMA IN TUBERCULOSIS ENDEMIC REGIONS: REVIEW OF LITERATURE WITH CASE STUDIES

Dr. Anjali Tewari, *Dr. Deepti Gupta, Dr. Nupur Trivedi, Dr. Shefali Agarwal
and Dr. Asha Agarwal

Consultant pathologist, Regency Hospital, Kanpur – 208005

ARTICLE INFO

Article History:

Received 15th March, 2016
Received in revised form
07th April, 2016
Accepted 18th May, 2016
Published online 15th June, 2016

Key words:

Sarcoidosis,
Tuberculosis,
Caseating/noncaseating epithelioid cell
granulomas.

ABSTRACT

Sarcoidosis is a systemic inflammatory disorder of unknown etiology, characterized by the presence of non-caseating epithelioid cell granulomas. Growing literature on sarcoidosis in India has led to an increased awareness of the disease. With the advent of better diagnostic tools, rare manifestations of sarcoidosis are likely to be recognized. However, a lot of diagnostic dilemma is associated with sarcoidosis. Clinical, radiological and histopathological similarities with tuberculosis pose even a greater diagnostic challenge in countries endemic to tuberculosis. Not only sarcoidosis is a close mimic of TB, but TB has been linked to the causation of sarcoidosis. Recent advances in immunologic and molecular techniques have strengthened the association between mycobacteria and sarcoidosis.

Aims & Objectives: (1) To study the rare manifestations in patients with sarcoidosis. (2) To demonstrate the sarcoidosis-tuberculosis link, diagnostic modalities and dilemma in the diagnosis.

Method: Retrospective review of records of 20 patients with histopathologically proven sarcoidosis seen over 2 years in a tertiary care centre in Kanpur, was done.

Results: 20% (4 out of 20) cases had rare manifestations (one had isolated bone marrow sarcoidosis, two had isolated liver involvement and the fourth case had uterine sarcoidosis) while the rest 80% had lung or/and lymph node involvement. 6 (30%) out of 20 cases had a tuberculosis link. Four had tuberculosis and then later developed sarcoidosis, one had sarcoidosis and then later developed overt tuberculosis; one had coexisting tuberculosis and sarcoidosis.

Conclusion: The clinicians and pathologists should keep in mind the rare sites of sarcoidosis before making a diagnosis of tuberculosis in India and should further investigate the patients for sarcoidosis. Also, in patients having recurrent tuberculosis or not responding to ATT with granulomatous pathology, a diagnosis of sarcoidosis should be thought of.

Copyright©2016, Dr. Anjali Tewari et al. This is an open access article distributed under the Creative Commons Attribution License, which permits unrestricted use, distribution, and reproduction in any medium, provided the original work is properly cited.

Citation: Dr. Anjali Tewari, Dr. Deepti Gupta, Dr. Nupur Trivedi, Dr. Shefali Agarwal and Dr. Asha Agarwal. 2016. "Sarcoidosis: Rare manifestations and diagnostic dilemma in tuberculosis endemic regions: review of literature with case studies", *International Journal of Current Research*, 8, (06), 32735-32737.

INTRODUCTION

Sarcoidosis is a systemic inflammatory disorder of unknown etiology, characterized by the presence of non-caseating epithelioid cell granulomas. Growing literature on sarcoidosis in India has led to an increased awareness of the disease. With the advent of better diagnostic tools, rare manifestations of sarcoidosis are likely to be recognized. However, a lot of diagnostic dilemma is associated with sarcoidosis (Baughman, 2003). Clinical, radiological and histopathological similarities with tuberculosis pose even a greater diagnostic challenge in countries endemic to tuberculosis.

Not only sarcoidosis is a close mimic of TB, but TB has been linked to the causation of sarcoidosis. Recent advances in immunologic and molecular techniques have strengthened the association between mycobacteria and sarcoidosis (Shah, 2007).

Aims and Objectives

- To study the rare manifestations in patients with sarcoidosis.
- To demonstrate the sarcoidosis-tuberculosis link, diagnostic modalities and dilemma in the diagnosis.

*Corresponding author: Dr. Deepti Gupta

Consultant pathologist, Regency Hospital, Kanpur – 208005

MATERIALS AND METHODS

Retrospective review of records of 20 patients with histopathologically proven sarcoidosis seen over 2 years in a tertiary care centre in Kanpur, was done. The presenting complaints, provisional clinical diagnosis, radiological findings (X-ray chest, CECT, USG), sputum culture/ZN stain, TBNA/Biopsy findings, Serum ACE levels, tuberculin test, any other organ biopsy and final diagnosis were recorded. The patient was followed up and response to therapy was recorded to confirm the diagnosis.

RESULTS

Clinical and radiological presentations in all the cases were indecisive and a provisional diagnosis of tuberculosis was kept as it being the more common disease in Indian subcontinent. Tuberculin test, Serum ACE levels and most importantly histopathological (caseating vs non caseating granulomas) result helped in reaching the diagnosis of Sarcoidosis. Of all the cases of sarcoidosis, 16 were reported in lymph node or lung, the most common sites of sarcoidosis. Out of the rest four cases, one showed sarcoidosis in bone marrow primarily,

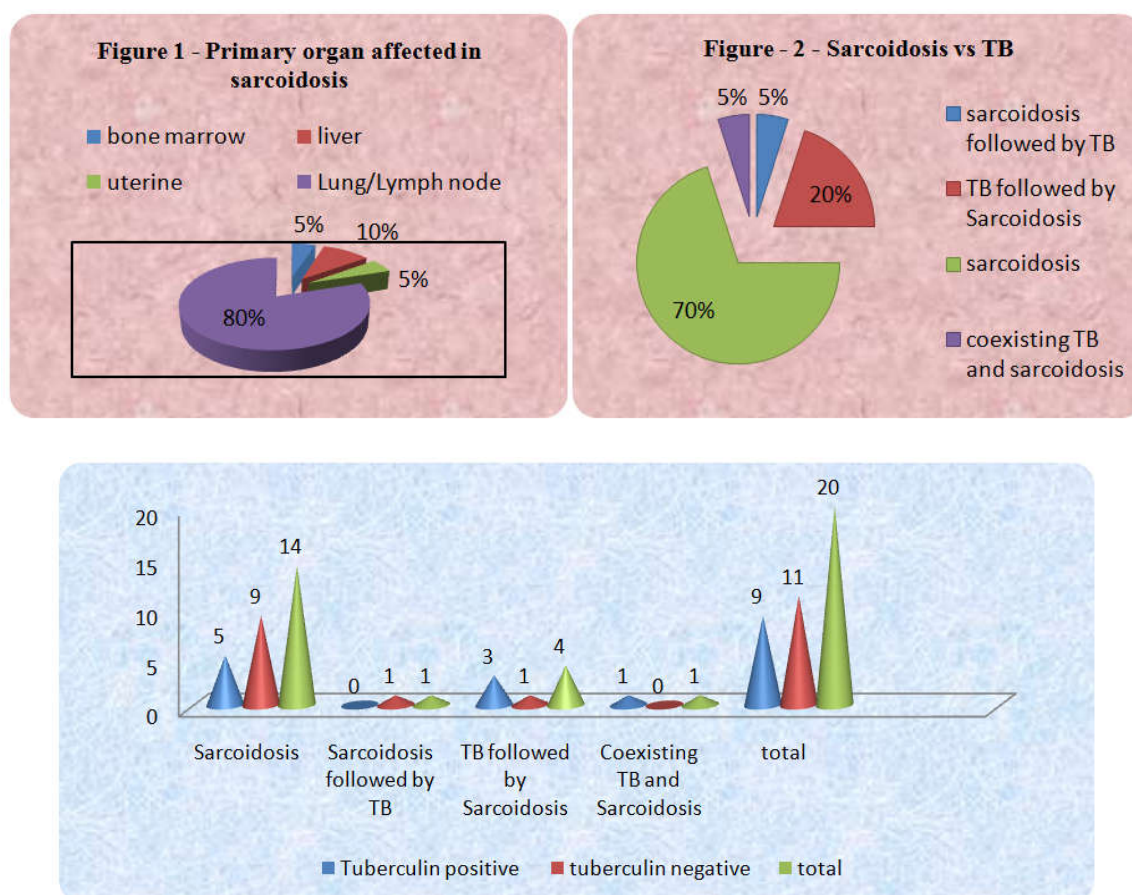


Figure 3. Tuberculin test

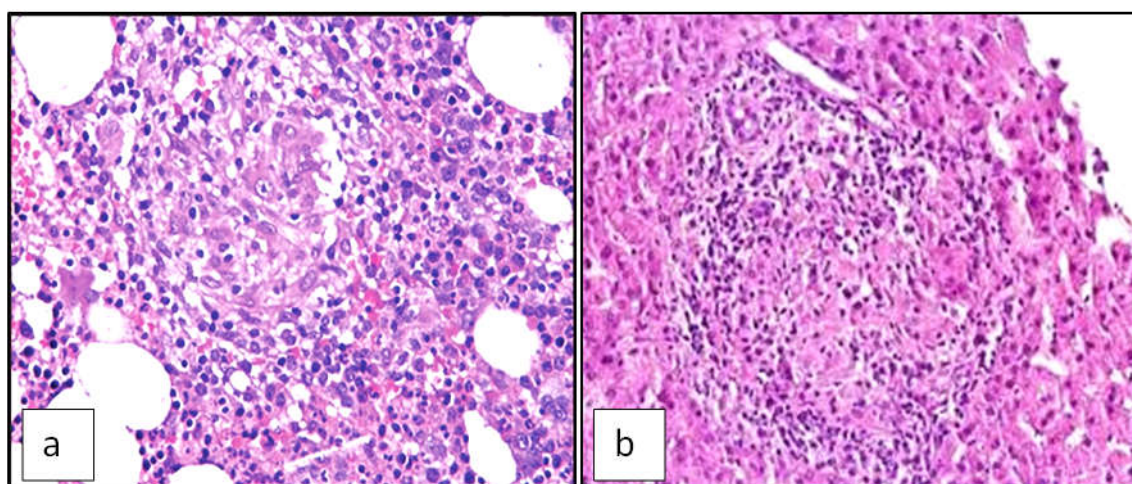


Figure 4. Non caseating granulomas in (a) Bone marrow biopsy X400 (b) Liver biopsy X400

one had only uterine sarcoidosis, while the rest two had liver sarcoidosis. (Figure 1, 4). Fourteen out of twenty cases (70%) revealed noncaseating granulomas on tissue sections and were AFB negative. Out of these 14 cases 9 were tuberculin negative and 10 had elevated ACE levels. The radiological picture (X-ray/CT) was in favour of sarcoidosis in 9 cases. Taking all the findings collectively, diagnosis of sarcoidosis was made in these 14 cases, (Figure 2,3). Out of the rest 6 cases, one patient was diagnosed with sarcoidosis (negative tuberculin, high ACE levels, bilateral hilar lymphadenopathy and noncaseating granulomas in lung biopsy), but later on treatment with steroids and follow up developed AFB positive disease and was treated with ATT which improved the condition of the patient. (sarcoidosis followed by tuberculosis) One patient was diagnosed as having coexisting sarcoidosis and TB. He had very high serum ACE levels and both caseating and non caseating granulomas in lymph node. The patient responded well to ATT with steroid therapy. Four cases of tuberculosis had a flared up disease after the completion of ATT course and had a conversion from AFB positive to AFB negative disease. All these patients showed improved on steroid therapy, (tuberculosis followed by sarcoidosis)

DISCUSSION

The conundrum of link between tuberculosis and sarcoidosis has fascinated the researchers and clinicians for ages. Both TB and Sarcoidosis share remarkable similarities in their clinical and radiological presentations. Both diseases present with fever, malaise, weight loss and fatigue. Respiratory symptoms are also common to both the diseases. Radiologic similarities may be seen in both diseases. Discrete, bilateral, symmetrical lymph node enlargement is usually seen in sarcoidosis. Fibrosis and military distribution although more common in TB but may be seen in both the diseases. On histopathology, both the diseases show granulomatous inflammation. Caseation is seen in tuberculosis whereas fibrinoid necrosis though rare can occur in upto 30% of cases of sarcoidosis (Kalpana Babu, 2013).

Since sarcoidosis was first described, there has always been a belief that the disease is in some way related to tuberculosis. However, the inability to identify mycobacteria by histological staining or culture from pathological tissue samples continues to be one of the strongest arguments against a potential role of mycobacteria. Several studies have been carried out using molecular techniques to study the presence of mycobacteria in sarcoidosis patients (du Bois, 2003). The four cases who had tuberculosis and then developed sarcoidosis indicate that weakened tuberculous pathogenicity and altered immunodefense mechanism in select individuals results in non caseating granulomatous sarcoidosis (Shah, 2007). Over a period of time the patients of tuberculosis underwent adaptive evolutionary changes to strengthen their defense mechanism against infective organism. This is evident by cell wall deficient mycobacteria grown from the blood of subjects of sarcoidosis (Almenoff, 1996).

Gazouli *et al* reported that in Greek population 72% of tissues contained amplifiable MTB DNA and Saboor found MTB DNA in half of the sarcoidosis lung samples using PCR (Gazouli, 2002 and Saboor, 1992). Wonder *et al* found evidence of mycobacterial DNA in the granulomas of 60% of sarcoidosis specimens when assessing for rpoB, and 16S rRNA (Drake, 2002). Scadding reported 34 cases of tuberculous sarcoidosis. 11 cases had caseating tuberculosis that preceded the development of sarcoidosis. In 5 cases, sarcoidosis was followed by caseating tuberculosis. In remaining 18 cases, tubercle bacilli were isolated during the course of sarcoidosis although clinical, immunological and radiological features remained characteristic of sarcoidosis. He isolated tubercle bacilli from the patients of sarcoidosis. He also coined the term "Tuberculous Sarcoidosis" (Scadding, 1962). The clinicians and pathologists should keep in mind the rare sites of sarcoidosis before making a diagnosis of tuberculosis in India and should further investigate the patients for sarcoidosis. Also, in patients having recurrent tuberculosis or not responding to ATT with granulomatous pathology, a diagnosis of sarcoidosis should be thought of.

REFERENCES

- Baughman, R.P., Lower, E.F., du Bois, R.M. 2003. Sarcoidosis. *Lancet*, 361:1111-8.
- Shah, J.R. 2007. Tuberculous Sarcoidosis. *Lung India*, 24: 83-6.
- Kalpana Babu. 2013. Sarcoidosis in tuberculosis-endemic regions: India. *Journal of Ophthalmic Inflammation and Infection*, 3:53.
- du Bois, R.M., Goh, N., McGrath, D., Cullinan, P. 2003. Is there a role for microorganisms in the pathogenesis of sarcoidosis?. *J Intern Med*, 253:4-17.
- Almenoff, P.L., Johnson, A., Lesser, M., Mattman, L.H. 1996. Growth of acid fast L forms from the blood of patients with sarcoidosis. *Thorax*, 51: 530-3.
- Gazouli, M., Ikonomopoulos, J., rigidou, R., Foteinou, M., Kittas, C., Gorgoulos, V. 2002. Assessment of mycobacterial, propionibacterial, and human herpesvirus 8 DNA in tissues of Greek patients with sarcoidosis. *J Clin Microbiol.*, 40: 3060-3.
- Saboor, S.A., Johnson, N.M., McFadden, J. 1992. Detection of mycobacterial DNA in sarcoidosis and tuberculosis with polymerase chain reaction. *Lancet*, 339: 1015-7.
- Drake, W.P., Pei, Z., Pride, D.T., Collins, R., Cover, T.L., Blaser, M.J. 2002. Molecular Analysis of Sarcoidosis Tissues for Mycobacterium Species DNA. *Emerg Infect Dis*, Nov; 8(11): 1334-1341.
- Scadding, J.G. 1962. The relation between sarcoidosis and tuberculosis. *Brompton hospital case reports*. *Lloyd-Luke*, 31:34.
