



## RESEARCH ARTICLE

### ILEOCAECAL ENDOMETRIOSIS PRESENTING AS INTESTINAL OBSTRUCTION

\*<sup>1</sup>Syed Imtiyaz Hussain, <sup>2</sup>Gulshan Akhter, <sup>1</sup>Baba Iqbal Khaliq and <sup>1</sup>Ruby Reshi

<sup>1</sup>Senior Resident Post Graduate Department of Pathology GMC Srinagar

<sup>2</sup>Postgraduate Department of Obstetrics and Gynaecology GMC Srinagar - 190010

#### ARTICLE INFO

##### Article History:

Received 20<sup>th</sup> April, 2016  
Received in revised form  
09<sup>th</sup> May, 2016  
Accepted 23<sup>rd</sup> June, 2016  
Published online 16<sup>th</sup> July, 2016

##### Key words:

Endometriosis, Terminal ileum,  
Endometrial glands.

#### ABSTRACT

Endometriosis is characterized by the presence of endometrial tissue consisting of glands and/or stroma located outside the uterus. Involvement of the terminal ileum is extremely rare. Preoperative distinction of ileal endometriosis from other diseases of the ileocecal region is difficult in terms of clinical presentation, symptomatology, radiological appearance, and surgical and pathological findings. We report a case which was diagnosed as suspicious of malignancy and was having intestinal obstruction, but finally diagnosed as ileocaecal endometriosis by histopathological evaluation after resection of the involved segment.

Copyright©2016, Syed Imtiyaz Hussain et al. This is an open access article distributed under the Creative Commons Attribution License, which permits unrestricted use, distribution, and reproduction in any medium, provided the original work is properly cited.

Citation: Syed Imtiyaz Hussain, Gulshan Akhter, Baba Iqbal Khaliq and Ruby Reshi, 2016. "Ileocaecal endometriosis presenting as intestinal obstruction", *International Journal of Current Research*, 8, (07), 34161-34163.

## INTRODUCTION

Presence of endometrial tissue seen at various sites other than uterus is known as endometriosis. It is a relatively a common disease in women of childbearing age. Some extra uterine sites of endometriosis are ovaries, pouch of douglas, peritoneum, fallopian tubes, urinary bladder, caesarean scar, vagina, episiotomy wound, laparoscopic port, pleura, lung, etc. Intestinal involvement is seen in 12-37% of cases and most of them show serosal implantation without causing any symptoms. Only 1% can have intestinal obstruction (De Bree et al., 1998) However, intestinal endometriosis involving full thickness of the wall of intestine and mucosa causing stricture and complete intestinal obstruction is very rare. In the ileo-caecal region the clinical differential diagnosis are tuberculosis, lymphoma, carcinoma. We report one such case which shows microscopically endometrial tissue and diagnosis of endometriosis was given.

### Case report

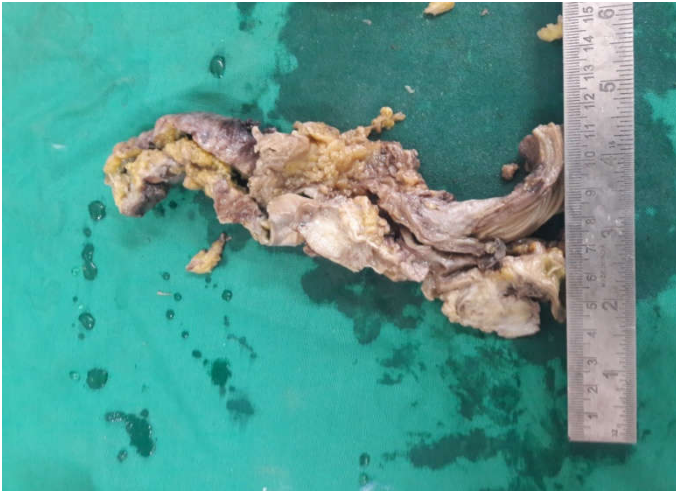
A 34-year-old multigravida female patient was admitted to surgical department of our tertiary teaching care hospital with complaints of abdominal pain and constipation of more than 3

months duration. The colonoscopic exam revealed inflammatory changes of the colonic mucosa and obstructive lesion at ileocaecal region with clinical impression likely malignant and base line investigations shows anemia only and right hemicolectomy was done and we receive the said specimen. On gross there was 3.5 cm firm grey white lesion present at ileo caecal region which was causing obstructive symptoms and raises the suspicious of malignancy, rest of mucosa appears normal. Fourteen (14) lymph nodes were dissected out from the specimen. On microscopy there were endometrial glands and stoma in submucosal and muscularis propria and no malignant glands were seen any where and hence the diagnosis of endometriosis was made and all the nodes were free.

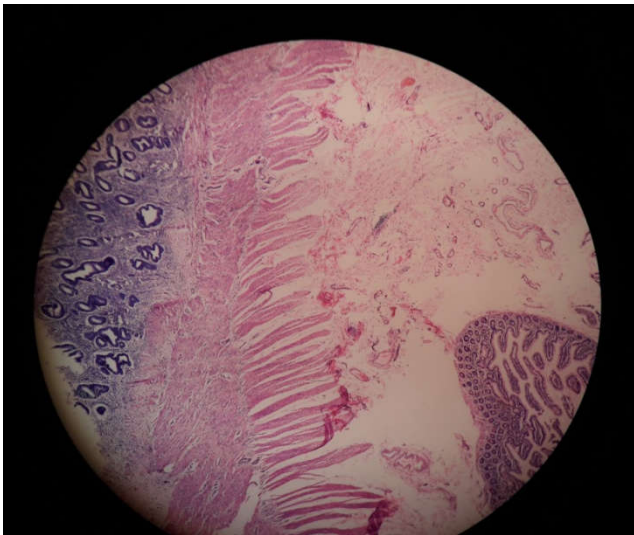
## DISCUSSION

Endometriosis is defined as the presence of endometrial tissue outside the uterine cavity. Although it is a benign disease, it may be aggressive producing local invasion and even metastases (Won, 1969). Endometrial tissue presence has been explained by various theories which includes direct myometrial extension, coelomic metaplasia, lymphatic and haematogenous metastasis. Presence in the small and large intestines leads to acute and chronic symptomatology. It may mimic a large number of diseases.

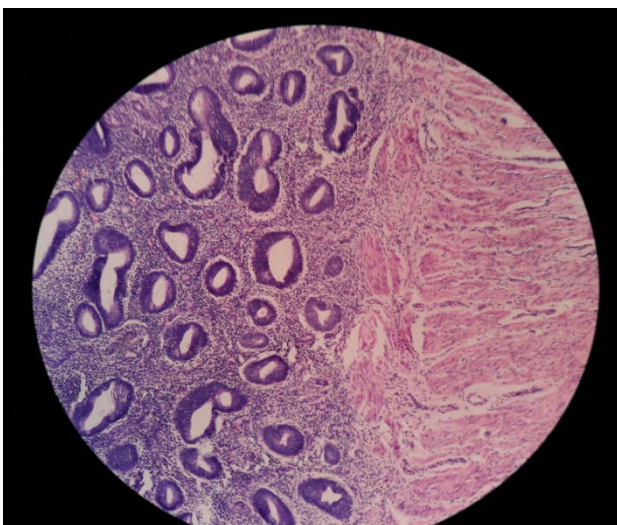
\*Corresponding author: Syed Imtiyaz Hussain,  
Postgraduate Department of Pathology GMC Srinagar



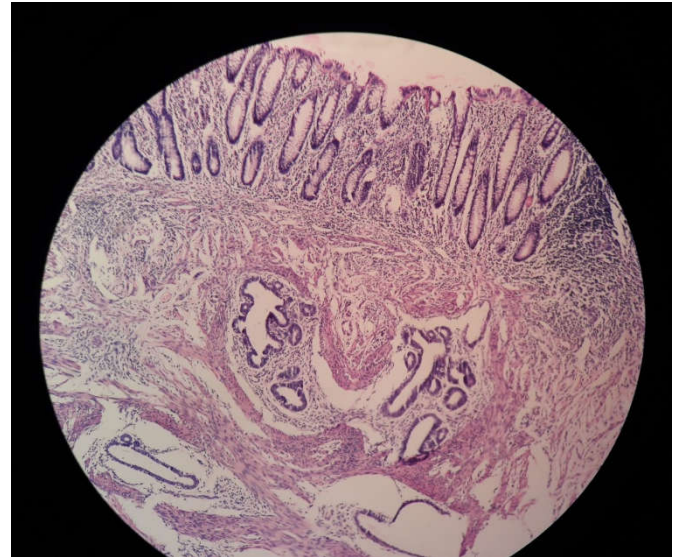
**Figure 1.** Gross picture of portion of gut showing mucosa on one side and grey white solid area on other side causing ileocaecal obstruction



**Figure 2.** Photo micrograph showing gut mucosa on one side and variable sized endometrial glands and stoma on other side in between muscle. (4X)



**Figure 3.** Photomicrograph showing variable sized endometrial glands and stromal tissue and muscular propria. (40x)



**Figure 4.** Photomicrograph showing mucosal glands on top and endometrial gland deep in the muscular layer (10x)

Clinical differential diagnosis includes diverticulitis, appendicitis, Crohn's disease, tubo ovarian abscess, ileocaecal Koch's, irritable bowel syndrome, carcinoma and lymphoma. Small bowel involvement is seen in 5-18% of patients of intestinal endometriosis but nodular endometriosis involving the entire wall of the terminal ileum and resulting in complete obstruction is extremely rare (Dwoski *et al.*, 2001; Mussa *et al.*, 2001).

Endometriosis of the gastrointestinal tract is a common disorder that, when symptomatic, may be difficult to diagnose accurately. The rectosigmoid area (72%) is the most involved area. Other affected intestinal sites in decreasing order of frequency are the rectovaginal septum (13%), the small bowel (7%), the cecum (4%), and the appendix (3%) (Zimmermann and Christman, 1995). Involvement of the small bowel proximal to Meckel's diverticulum is extremely rare, but there are a few reported cases involving Meckel's diverticulum or jejunum (Won, 1969; Bergemann Heuer, 1992). Exact diagnosis of cases with no symptoms is difficult before surgery, and ultrasound, CT, and magnetic resonance imaging (MRI) may be of limited benefit. Endoscopic biopsies usually yield insufficient tissue for a definitive pathologic diagnosis as endometriosis involves the deep layers of the bowel wall. Diagnostic laparoscopy is the gold standard in detecting lesions. Biopsy of a suspicious area should be performed for precise diagnosis and for removal of lesions. Microscopically endometriotic foci were composed of aggregates of small, often widely spaced endometrioid glands embedded within a variable amount of endometrial stroma (Langlois *et al.*, 1994). In conclusion, preoperative distinction of ileal endometriosis from other diseases of the ileocecal region is difficult in terms of clinical presentation, symptomatology, radiological appearances, and surgical and pathological findings. However, ileocaecal endometriosis should always be considered in the differential diagnosis in women of reproductive age and histopathological examination gives the exact diagnosis.

**Conflict of interest statement:**

**Source of funding:** There is no source of funding.

### Acknowledgement

Authors acknowledge the immense help received from the scholars whose articles are cited and included in references of this manuscript. The authors are also grateful to authors / editors / publishers of all those articles, journals and books from where the literature for this article has been reviewed and discussed.

### REFERENCES

- Bergemann W. and C. Heuer, 1992. "Extragenital endometriosis with multiple stenoses of the small intestine," *Fortschritte der Medizin*, vol. 110, no. 15, pp. 281–284.
- De Bree E, Schoretsanitis G, Melissa J, Christodoulakis M, Tsiftsis D. 1998. Acute Intestinal obstruction caused by endometriosis Mimicking sigmoid carcinoma. *Acta Gastroenterol Belg.*, 61(3):376-8.
- Dwoski WP, Rana N, Jafari N. 2001. Post laparoscopic small bowel obstruction secondary to endometriosis of the terminal ileum. *J Am Assoc Gynecol Laparosc.*, 8(1):161-6.
- Girona E, Niverio M, Palazon JM. 1998. Intestinal Obstruction secondary to endometriosis of colon. *Gastroenterol Hepatol.*, 21(9):441.
- Langlois, N. E. I., K. G. M. Park, and R. A. Keenan, 1994. "Mucosal changes in the large bowel with endometriosis: a possible cause of misdiagnosis of colitis?" *Human Pathology*, vol. 25, no. 10, pp. 1030–1034.
- Mussa FF, Younes Z, Tihan T, Lacy BE. 2001. Anasarca and small bowel obstruction secondary to endometriosis. *J Clin Gastroenterol.*, 32(2):167-71.
- Won, K. H. 1969. "Endometriosis, mucocele, and regional enteritis of Meckel's diverticulum. An unusual case report and experiences in 111 cases," *Archives of Surgery*, vol. 98, no. 2, pp.209–212.
- Zimmermann E. M. and G.M. Christman, 1995. "Approach to the female patient with gastrointestinal disease," in *Textbook of Gastroenterology*, T. Yamada, D. H. Alpers, C. Owyang, D. W. Powell, and F. E. Silverstein, Eds., pp. 1023–1043, Lippincott, Philadelphia, Pa, USA.

\*\*\*\*\*