



## RESEARCH ARTICLE

### LAPAROSCOPIC MANAGEMENT OF TWISTED FIMBRIAL CYST: A RARE CAUSE OF ACUTE ABDOMEN

**\*Deepa Ganesh, NiveditaGoverdhan, Venkatesan Guru and NateshBala**

Assistant Professor, Department of Gynaecology, Saveetha Medical College and Hospital, Chennai, Tamilnadu, India

#### ARTICLE INFO

##### Article History:

Received 22<sup>nd</sup> May, 2016  
Received in revised form  
25<sup>th</sup> June, 2016  
Accepted 27<sup>th</sup> July, 2016  
Published online 31<sup>st</sup> August, 2016

##### Key words:

Fallopian Tube,  
Fimbrial Cyst,  
Torsion,  
Acute abdomen.

#### ABSTRACT

**Introduction:** High prevalence of non-communicable diseases particularly hypertension is gaining much importance in developing countries. Associations between body mass index (BMI) and blood pressure (BP) have been consistently observed but the unresolved question is, whether there is a linear relationship across the entire BMI range. There is further need to study the relationship of anthropometry with hypertension to assess its applicability in all populations.

**Aims/Objectives:** To analyze the better anthropometric predictor of Hypertension.

**Results and discussion:** Of the 39 hypertensive we found in our study 8 showed family history of hypertension i.e. about 20.5%, this shows that familial hypertension is also a major cause of concern. WC > BMI > WHR as indicators of hypertension (relative p values- 0.001, 0.038, 0.94 for waist circumference, body mass index and waist hip ratio respectively).

**Conclusion:** The accuracy of anthropometric measurements as indicators showed that waist circumference was a better indicator than BMI which in turn is preferred over waist hip ratio.

**Copyright©2016, Deepa Ganesh et al.** This is an open access article distributed under the Creative Commons Attribution License, which permits unrestricted use, distribution, and reproduction in any medium, provided the original work is properly cited.

**Citation:** Deepa Ganesh, NiveditaGoverdhan, Venkatesan Guru and NateshBala, 2016. "Laparoscopic management of twisted fimbrial cyst: a rare cause of acute abdomen", *International Journal of Current Research*, 8, (08), 37329-37332.

## INTRODUCTION

Fimbrial cysts represent approximately 10% of adnexal masses. They are more common in women of child bearing age. Most of these cysts are small and asymptomatic, although occasionally large cysts may cause discomfort and pain. Isolated twisting of fallopian tubes is an uncommon event. The frequency is 1/1,500,000 women (Hansen, 1970). The signs, symptoms and physical findings mimic common diseases like acute appendicitis or ovarian torsion, therefore the diagnosis is never established before an invasive procedure like laparoscopy. Accurate and immediate diagnosis can lead to early intervention, avoid complications and may even save the organ. Here we present the case of a twisted fimbrial cyst which presented as an acute abdomen.

## CASE REPORT

A 43 year old para 2, presented with acute onset lower abdominal pain, more on the right side, radiating from loin to groin. She also had 3 episodes of vomiting.

##### \*Corresponding author: Deepa Ganesh,

Assistant Professor, Department of Gynaecology, Saveetha Medical College and Hospital, Chennai, Tamilnadu, India.

She had undergone 2 caesarean sections and tubal ligation in the past. Past menstrual cycles were regular. On examination, her vitals were stable, but there was tenderness in the right iliac fossa. On Per vaginal examination, there was tenderness in the right and posterior fornices. Laboratory investigations including haemoglobin, total leucocyte count, differential leucocyte count, and routine and microscopic examination of the urine were found to be normal. On suspicion of ureteric calculus, an ultrasound of the abdomen and pelvis was ordered, which revealed right adnexal cyst of around 8x5 cm, with reduced flow, s/o ovarian torsion and left ovary and uterus normal (Fig 1-2) A urine pregnancy test was done to rule out ectopic pregnancy, which was negative.

With a provisional diagnosis of right ovarian torsion, the patient was taken for an emergency laparoscopic cystectomy under general anaesthesia. Intra-operative findings were: a haemorrhagic fimbrial cyst of right fallopian tube of size 8x7cm (Fig-3). The cyst had undergone torsion and appeared markedly congested. Both the ovaries, uterus and left fallopian tube were within normal limits. Detorsion and cystectomy was done laparoscopically. An uneventful post-operative course followed, and the patient was discharged after 48 hours. Histopathology showed markedly congested fibromuscular tissue consistent with tubal origin.

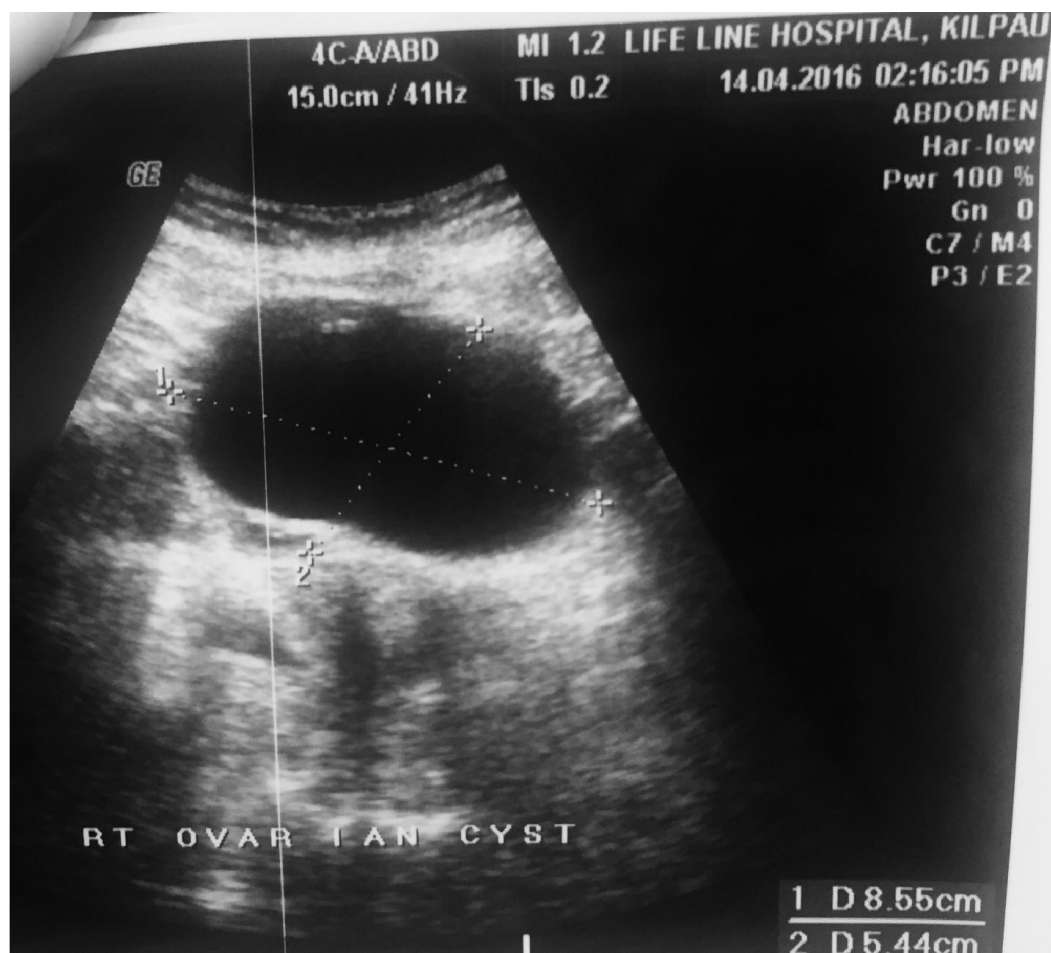

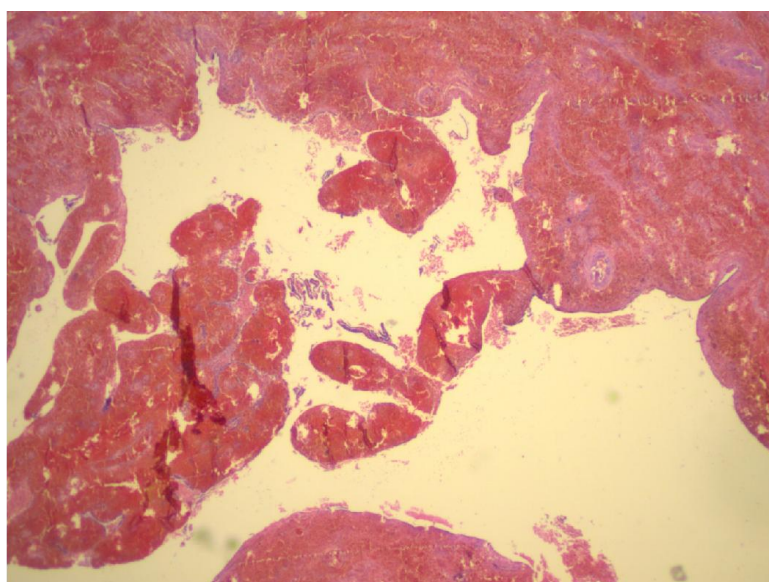
Fig. 1.

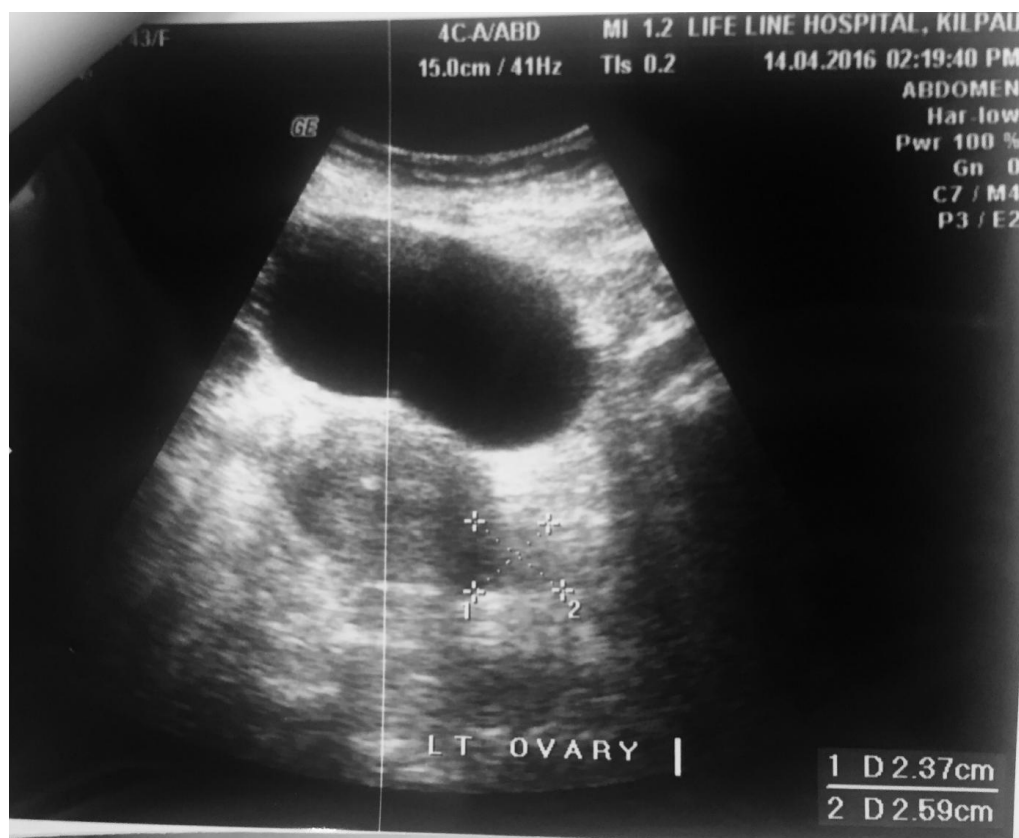
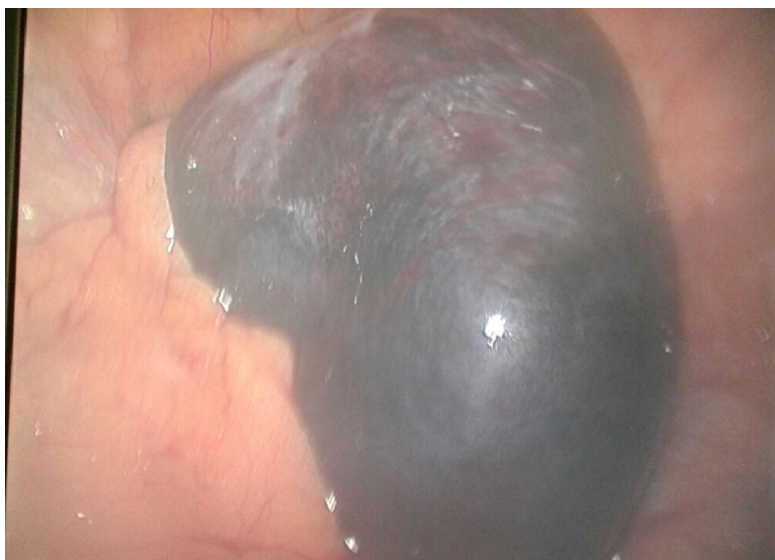
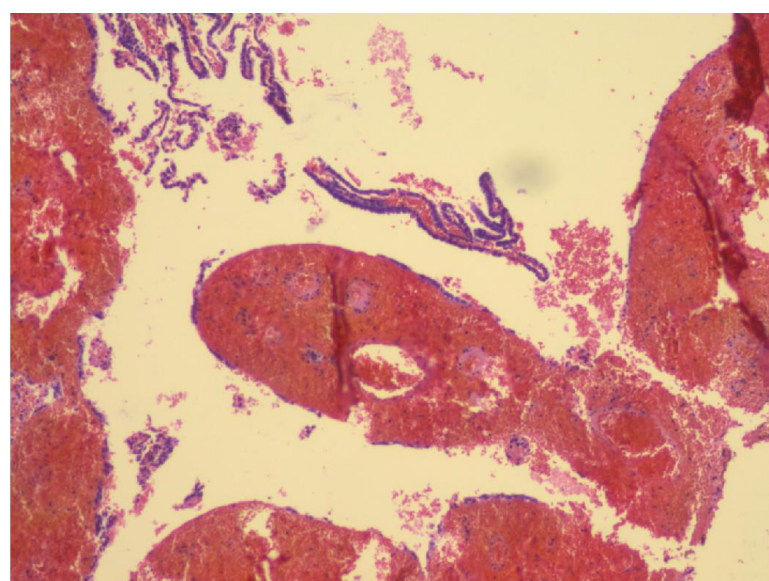
Fig. 2.



**Fig. 3.**



**Fig. 4.**



**Fig. 5.**

There was loss of plicae and flattening of the tubal epithelium. There was evidence of haemorrhage in the wall indicative of torsion (Fig4 -5).

## DISCUSSION

10% of adnexal masses are paraovarian or tubal in origin<sup>1</sup>. They arise from Müllerian or Wolffian structures. These cysts are usually small, unilateral, asymptomatic and mostly seen in adult women (Samaha and Woodruff, 1985). Larger cysts, probably mesothelial in origin, may be seen in younger patients (Parveen *et al.*, 2010). Complications seen with fimbrial cysts include torsion (2-16 %), haemorrhage, rupture, secondary infection and neoplastic transformation (2.9%) (Khawaja and Qazi, 2009). Torsion of fallopian tube or fimbrial cyst is rarely seen as an isolated event, which makes the diagnosis difficult and delayed. As an explanation of this uncommon phenomenon, a variety of theories have been proposed. Fallopian tube torsion may be due to anatomic anomalies including long mesosalpinx, hydrosalpinx and hydatis of morgagni. Physiologic variations include increased peristalsis or motility of the tube and tubal spasm due to drugs. There may also be haemodynamic abnormalities like venous congestion of the mesosalpinx, or trauma to the tube (Shukula, 2004).

Tubal ligation for sterilization, particularly if done by the Pomeroy method, like what was done in our patient, may be a potential aetiological factor in the formation of tubal cysts and if the cyst is in the fimbrial end, it may lead to torsion and present like an acute abdomen (Bishop and Nelms, 1930). The differential diagnosis of Fallopian tube torsion includes acute appendicitis, ectopic pregnancy, pelvic inflammatory disease, twisted ovarian cyst and degenerative subserosal pedunculated leiomyoma and renal or ureteric colic (Krissi *et al.*, 2001). The most common chief complaint is abdominal pain which usually begins in the affected side of the lower abdomen or pelvis but may radiate to the flank or thigh. The pain is sudden in onset and cramp like or colicky. Pelvic examination reveals a tender, tense adnexal mass associated with cervical motion tenderness. There may be a few episodes of vomiting. The patient may have fever, and white blood cell count may be slightly elevated (Imrana Masroor *et al.*, 2008).

It is very difficult to diagnose fimbrial cysts on ultrasound. Typically, the discovery is made accidentally during surgery for some other ailment, and such cysts are prophylactically excised as they have a tendency to undergo torsion or rapid enlargement (Genardy *et al.*, 1977). Our patient may have had an adnexal cyst for some time, but to us she presented as an acute abdomen. Ultrasound examination may show an elongated, convoluted cystic mass, and the ipsilateral ovary may be seen separate from the mass. Doppler evaluation can be of value by showing findings of high impedance or absence of flow in a tubular structure (Elchalal *et al.*, 1993).

The management of this condition consists of early surgery, either laparotomy or laparoscopy. Minimal access surgery is a better option, as in our case, when the patient is haemodynamically stable. It offers the advantages of less pain, less blood loss, smaller scar and early recovery (Imrana Masroor *et al.*, 2008).

## Conclusion

Fimbrial cysts have a common misdiagnosis as ovarian cysts on ultrasound. Although there have been published case reports, very often delay or error in making a preoperative diagnosis is inevitable, as isolated tubal torsion is a rare occurrence. Although atypical, torsion of fimbrial cyst should be considered as a differential diagnosis of acute abdomen in women, especially those who have history of bilateral tubal ligation.

## REFERENCES

- Barloon, T.J., Brown, B.P., Abu-Yusuf, M.M., Warnock, N.G. 1996. Paraovarian and paratubal cysts: preoperative diagnosis using transabdominal and transvaginal sonography. *J Clin Ultrasound.*, 24:22-117.
- Bishop, E.A., Nelms, W.F. 1930. A simple method of tubal sterilization. *NY State J Med.*, 30:214.
- Elchalal, U., Caspi, B., Schachter, M., Borenstein, R. 1993. Isolated tubal torsion: clinical and ultrasonographic correlation. *J Ultrasound Med.*, 12:115-7.
- Genardy, R., Parmley, T., Woodruff, J.D. 1977. The original and clinical behaviour of the paraovarian tumour. *Am J Obstet Gynecol*, 129:80-873.
- Hansen, O.H. 1970. Isolated torsion of the Fallopian tube. *Acta Obstet Gynecol Scand* 1970; 49:3-6.
- Imrana Masroor, Nadir Khan. 2008. Torsion of Fallopian Tube, Fimbrial Cyst. *J Pak Med Assoc*, Oct;5(10):571-3.
- Khawaja, B., Qazi, R.A. 2009. Twisted Right Fimbrial (Paraovarian) Cyst. *J Surg Pak.*, Oct-Dec;14(4):182-3.
- Krissi, H., Shalev, J., Bar-Hava, I., Langer, R., Herman, A. and Kaplan, B. 2001. Fallopian tube torsion: laparoscopic evaluation and treatment of a rare gynecological entity. *J Am Board Fam Pract.*, 14:274-7.
- Parveen, Z., Amna, A., Munir, A.A., Zehra, N. 2010. Torsion of Fimbrial Cyst. *Isra Med J.*, Aug;2(2):52-3
- Samaha, M., Woodruff, J.D. 1985. Paratubal cysts: frequency, histogenesis, and associated clinical features. *Obstet Gynecol*. 65:691-4.
- Shukula, R. 2004. Isolated torsion of the hydrosalpinx: a rare presentation. *Br J Radiol.*, 77:784-6.

\*\*\*\*\*