



RESEARCH ARTICLE

SPINAL CANAL DECOMPRESSION WITH SHORT SEGMENT STABILISATION IN THORACIC AND LUMBAR BURST FRACTURES OF SPINE – A RETROSPECTIVE ANALYSIS OF 38 CASES

<sup>1</sup>Dr. Ish K Dhammi, <sup>2,\*</sup>Dr. Amit Srivastava, <sup>3</sup>Dr. Anil K Jain and <sup>4</sup>Dr. Rehan Ul Haq

<sup>1</sup>Senior Specialist, Department of Orthopaedics, University College of Medical Sciences and Guru Teg Bahadur Hospital, Delhi-110095, India

<sup>2</sup>Senior Resident, Department of Orthopaedics, University College of Medical Sciences and Guru Teg Bahadur Hospital, Delhi-110095, India

<sup>3</sup>Professor and Head, Department of Orthopaedics, University College of Medical Sciences and Guru Teg Bahadur Hospital, Delhi-110095, India

<sup>4</sup>Associate Professor, Department of Orthopaedics, University College of Medical Sciences and Guru Teg Bahadur Hospital, Delhi-110095, India

ARTICLE INFO

Article History:

Received 22<sup>nd</sup> June, 2016  
Received in revised form  
25<sup>th</sup> July, 2016  
Accepted 17<sup>th</sup> August, 2016  
Published online 30<sup>th</sup> September, 2016

Key words:

Spine,  
Trauma,  
Indirect reduction,  
Fusion.

ABSTRACT

**Objective:** We report the efficacy of indirect spinal canal decompression by short segment pedicle screw fixation and distraction in burst fractures of thoracolumbar region of spine.

**Methods:** Thirty eight patients with mean age of 34.5 years of thoracolumbar burst fractures were operated by short segment pedicle screw fixation and indirect reduction. Patients in which – fracture pattern was not burst type, direct reduction for canal clearance was required, bone graft was used for fusion and more than one spinal level involved were excluded from the study. X ray of spine (antero-posterior and lateral view) were done in all patients, MRI and CT scan were also done. Neurological examination was done by Frankel's grading system. Patients were followed for the average period of 2.8 years, the change in vertebral height, kyphotic angle and neurological deficit were recorded postoperatively, at 3 months, 6 months and at final follow up.

**Results:** Twenty six patients (68%) had neurological deficit, till last follow up 23 patients had complete neurological recovery. In our series Denis Type B was the most common burst fracture pattern, seen in 63% of cases. The vertebral height was restored to 81% (60-88%) postoperatively and kyphotic angle improved to -1 degree (-10 to +14 degrees) from 14.1 degrees (0-28 degrees).

**Conclusion:** The short segment stabilization and indirect reduction of burst fracture provides stabilisation and reduction of retro pulsed fragment. More space for neural tissue is created after decompression, thus better chances of neural recovery.

Copyright©2016, Ish K Dhammi et al. This is an open access article distributed under the Creative Commons Attribution License, which permits unrestricted use, distribution, and reproduction in any medium, provided the original work is properly cited.

Citation: Dr. Ish K Dhammi, Dr. Amit Srivastava, Dr. Anil K Jain and Dr. Rehan Ul Haq, 2016. "Spinal canal decompression with short segment stabilisation in thoracic and lumbar burst fractures of spine – a retrospective analysis of 38 cases" *International Journal of Current Research*, 8, (09), 38882-38885.

INTRODUCTION

Fracture of the thoraco-lumbar region (T10 – L2) is most common amongst all cases of traumatic spine injury (Siebenga et al., 2006). Neurological involvement is seen in 17-66 per cent of cases and 66% of cases have AO type A burst fracture pattern (Roer et al., 2005). Appropriate treatment of thoraco-lumbar burst fracture is still controversial, with both non-operative and surgical treatment being advocated.

\*Corresponding author: Dr. Amit Srivastava,

Senior Resident, Department of Orthopaedics, University College of Medical Sciences and Guru Teg Bahadur Hospital, Delhi-110095, India.

The decision to treat conservatively depends on various parameters like – stability of the fracture, degree of canal compromise, deformity of the injured segment and neurological status (Chow et al., 1996; Mumford et al., 1993). Non operative treatment with bed rest, postural reduction and bracing avoids the surgical intervention and associated morbidity, the conservative treatment of stable fractures without neurological deficit have variable results (Shen and Shen, 1999; Weinstein et al., 1988; Tropiano et al., 2003). Various surgical options are available for the management of burst fracture in thoracolumbar region like – posterolateral decompression and instrumentation, long segment posterior instrumentation and short segment fusion, short segment

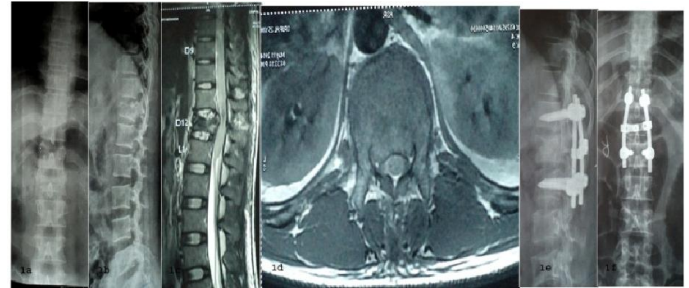
fixation and fusion, short segment fixation and distraction. Anterior decompression and stabilization was proposed for cases with severe canal compromise, non correctable deformities and neurological deficit, while posterior stabilization and indirect reduction was proposed for cases without neurological deficit and stable spine (Romero *et al.*, 1994; Jacobs and Casey, 1984; Dickson *et al.*, 1978; Aebi *et al.*, 1987; Doerr *et al.*, 1991). But it was established that posterior stabilization and reduction of burst fracture increases the spinal canal area by realigning the retropulsed fragment (Doerr *et al.*, 1991; Esses *et al.*, 1990). Indirect canal decompression is found to be effective within 3-4 days post trauma. Better prognosis is seen in Denis type A fractures with intact posterior longitudinal ligament which helps in reduction of fragments through ligamentotaxis (Doerr *et al.*, 1991; Esses *et al.*, 1990). In this study we report the efficacy of indirect spinal canal decompression by short segment pedicle screw fixation and distraction in Denis type A, B and D burst fractures with or without neurological deficit and to analyse the result in 38 such cases.

## PATIENTS AND METHODS

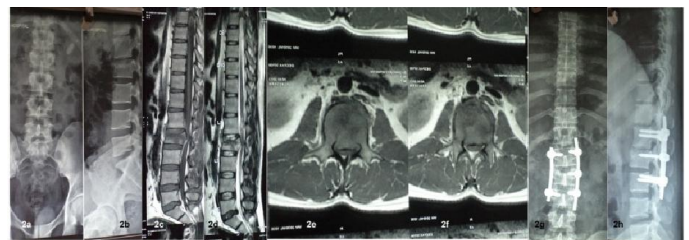
Thirty eight patients (29 males and 9 females) of thoracolumbar burst fractures operated were included in the study, from January 2008 to January 2014. The average age of patients was 34.5 years (17-59 years). Twenty three patients had history of fall from height and 15 patients had history of road traffic accidents. Primary and secondary survey of all patients was done and thorough neurological assessment was done after resuscitation. Patients in which- fracture pattern was not burst type, direct reduction for canal clearance was required, bone graft was used for fusion or more than one spinal level involvement, were excluded from the study. Neurological assessment was done in all cases and deficit was found in 26 cases, we used the Frankel's system grading system for defining neurological deficit (Frankel *et al.*, 1969). Twenty patient had Frankel D, five patients had Frankel C and one patient had Frankel B, none of the patient had complete paraplegia. There were associated fractures in 12 cases along with spine fracture. Eight patients had calcaneum fracture, 2 had proximal tibia fracture, 1 had fracture shaft of femur and 1 had Hoffa's fracture.

Radiological investigations were done and assessment of fracture and fracture pattern was done. The radiograph of thoracic and lumbar vertebra antero-posterior and lateral views were done in all cases, MRI was done in 29 cases and CT scan in 9 cases. All burst fractures were classified according to Denis classification. According to the classification, there were 12 Type A, 24 Type B (63% of cases) and 2 Type D fractures. D12 was fractured in 8 patients, L1 in 19 (50% of cases) patients, L2 in 6 patients, L3 in 3 patients and L4 in 2 patients. Along with this information on radiograph, Cobb's angle was calculated pre and post operatively and at the final follow up for measuring the change in kyphosis. The loss in vertebral height of the fractured spine was measured in plain X-ray lateral view, by taking the ratio of the vertebral body height to that of adjacent normal vertebral body. The informed consent was taken from all patients. They were operated within 2 weeks post trauma. Patients were taken in prone position and

posterior midline approach for spine was used, stabilisation was achieved by pedicle screw construct with fixation on adjacent vertebral bodies using standard technique. Distraction was done and an attempt was made to restore the vertebral body height and reduction of kyphotic deformity. Postoperatively patients were kept on bed rest for 2 weeks, physiotherapy and bed turning was allowed from second post operative day. Patients not having associated injury and neurological deficit were mobilised with spinal braces after 2 weeks. All patients were followed for the mean period of 2.8 years (8 months – 72 months), clinical examination and X-rays were done after 3 to 6 months and all assessments were recorded (Fig 1, Fig 2)



**Figure 1:** 1(a,b) Plain X ray AP and lateral view of dorsolumbar spine shows Denis type B burst fracture pattern of D 12 vertebral body, 1(c,d) shows the fractured superior end plate of vertebral body with the retropulsed fragment, 1(e,f) shows follow up after 3 years with the correction of vertebral height and kyphosis.

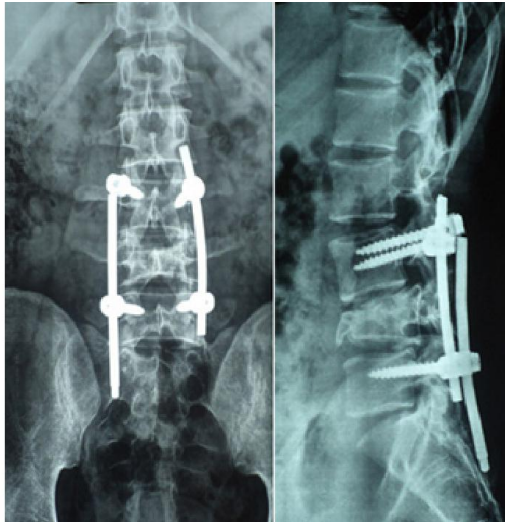


**Figure 2.** Shows plain X ray AP and lateral view of lumbosacral spine showing Denis type B fracture of L2 vertebral body, MRI shows the retropulsed fragment with kyphotic deformity. Fig 2(g,h) shows follow after 2.5 years with raft screw applied at the fractured vertebra

## RESULTS

All patients were followed up for 2.8 years (8 months to 72 months), clinical examination and X-rays were done at 3, 6 months and at final follow up all assessments were rerecorded. On neurological examination 26 (68 %) patients had deficit of variable degree as documented by Frankel's grading, 12 patients did not have any deficit. Neurological recovery was achieved in 23 patients postoperatively as examined subsequently on follow ups. Patients were followed with plain radiograph of spine on subsequent visits. CT scan and MRI were not done postoperatively because of financial constraints. Kyphotic deformity was measured by Cobb's angle; the measurement was done preoperatively, postoperatively and at the final follow up. The average kyphotic angle was 14.1 degrees (0-28 degrees) preoperatively and at final follow up it improved to -1 degree (-10 to +12 Degrees).

The change in vertebral height was measured by comparing the fractured vertebral body height with that of adjacent normal vertebra. Preoperatively vertebral body height reduced to 60 % of the normal vertebra, it was restored to 81% (60-88%) postoperatively. Some complications were encountered in the series till final follow up. Breakage of screw was reported in one case, loosening of rod in one case (Fig. 3), there was superficial surgical site infection in five cases. Three cases of infection responded to intravenous antibiotics while in two cases surgical site lavage was also done, all wounds healed subsequently.



**Figure 3. Plain X ray AP and lateral of lumbosacral spine shows the loosening of rod in one patient at final follow up (3 years).**

## DISCUSSION

Thoracolumbar burst fracture are caused by rapid compressive loading, it accounts for 15 % of all thoracolumbar injuries (Denis, 1983). These fractures are treated both conservatively and with operative intervention. The indication for surgical intervention depends on mechanical and neurological instability of the fracture. Instability is defined as the loss of ability of the spine under the physiological loads to maintain the relationship between vertebrae so that there is no additional neurological deficit, deformity or increase in pain intensity. In patients with stable fracture and without neurological deficit, conservative treatment with bed rest and bracing may give good results (Chow *et al.*, 1996; Mumford *et al.*, 1993; Shen and Shen, 1999; Weinstein *et al.*, 1988; Tropiano *et al.*, 2003). But in unstable fractures or stable fractures with neurological deficit surgical intervention is required (Romero *et al.*, 1994; Jacobs *et al.*, 1984; Dickson *et al.*, 1978; Aebi *et al.*, 1987; Doerr *et al.*, 1991; Esses *et al.*, 1990). There are various surgical approaches and stabilisation procedures which can be used for burst fractures in the thoracolumbar region. Burst fracture results from failure of anterior and middle column under axial load with variable sagittal moment. Hence axial distraction force is needed to reduce burst fracture & restore height. Short segment pedicle screw construct – allows direct reduction force to both anterior and middle column. Indirect reduction and posterior stabilisation is frequently procedure for the described fracture, as there is shorter operative time, less blood loss and early mobilisation (Fredrickson *et al.*, 1992).

In the current series 68% (N-26) of the patients had neurological deficit, none of the patients had complete paraplegia. It was found comparable to other studies (Muller *et al.*, 1999), where patients with thoracolumbar burst fracture had incomplete neurological deficits. The mechanism of neural injury and its relation with burst fracture and canal compromise is not clear. However, initial trauma to the neural tissue during the time of impact could be the cause for neurological deficit (Gertzbein *et al.*, 1992). There is chance of recovery in paraparesis, but chances of recovery after complete paraplegia are poor. In our series 26 patients had neurological deficit incomplete deficit, 23 (88%) patients recovered completely till final follow up and in three patients there was no recovery. Recent studies have established that posterior indirect reduction corrects the canal compromise adequately due to distraction ligamentotaxis and hyperextension (Siebenga *et al.*, 2006; Roer *et al.*, 2005; Aebi *et al.*, 1987). Apart from ligamentotaxis, Fredrickson *et al.* (1992) established the importance of outermost layer of the annular ligament in reduction of fracture fragment, the study established that by distraction of the spine fragments can be achieved. It also established that only posterior longitudinal ligament is not required for fragment reduction but symmetrical tightening of anterior longitudinal ligament and annulus fibrosus is also required. In our series indirect decompression and reduction of the fracture was achieved by short segment pedicle screw construct and distraction. There was marked improvement in vertebral height from 60% to 81% and reduction in kyphotic angle from 14 degrees (0-28 degrees) to -1 degree (-10 to -12 degree). The restoration of lumbar lordosis and vertebral height, also aided in fragment reduction and spinal canal decompression, as described by Fredrickson *et al.* (1992). The limitation of present series is that it is a retrospective study. Preoperative CT scan was done in 9 cases only and postoperative CT scan was not done to determine the canal encroachment and degree of canal compromise. Although MRI was done in 29 cases, it was not established if the posterior longitudinal ligament was intact. In conclusion, short segment stabilization with pedicle screws and indirect reduction gives stable fixation. It achieves reduction of burst fracture (restores height and reduces retropulsed fragment). More space and healthy environment for neural tissue after decompression with chance of neural recovery and early rehabilitation.

## REFERENCES

- Aebi, M., Etter, C., Kehl, T., Thalgott, J. 1987. Stabilization of the lower thoracic and lumbar spine with the internal spinal skeletal fixation system: Indications, techniques and first results of treatment, *Spine* 12,544-51.
- Chow, G.H., Nelson, B.J., Gebhard, J.S. 1996. Functional outcome of thoracolumbar burst fractures managed with hyperextension casting or bracing and early mobilization, *Spine* 21, 2170-5.
- Denis, F. 1983. The three column spine and its significance in the classification of acute thoracolumbar spinal injuries, *Spine*, 8, 817-31.
- Dickson, J.H., Harrington, P.R., Erwin, W.D. 1978. Results of reduction and stabilization of the severely fractured thoracic and lumbar spine. *J Bone Joint SurgAm.*, 60,799-805.

- Doerr, T.E., Montesano, P.X., Burkus, J.K., Benson, D.R. 1991. Spinal canal decompression in traumatic thoracolumbar burst fractures: Posterior distraction rods versus transpedicular screw fixation, *J Orthop Trauma*, 4,403-11.
- Esses, S.I., Botsford, D.J., Kostuik, J.P. 1990. Evaluation of surgical treatment for burst fractures, *Spine* 15,668-73.
- Frankel, H.L., Hancock, D.O., Hyslop, C. 1969. The value of postural reduction in the initial management of the spine with paraplegia and tetraplegia. *Paraplegia*, 7,179-92.
- Fredrickson, B.E., Edwards, W.T., Rauschnig, W., Bayley, J.C., Yuan, H.A. 1992. Vertebral burst fractures: An experimental, morphologic and radiographic study, *Spine*, 17, 1012-21.
- Gertzbein, S.D., Crowe, P.J., Schwartz, M., Rowed, D. 1992. Canal clearance in burst fractures using the AO internal fixator, *Spine*, 17,558-60.
- Jacobs, R.R., Casey, M.P. 1984. Surgical management of thoracolumbar spinal injuries: General principles and controversial considerations, *Clin Orthop*, 189,22–35.
- Muller, U., Berlemann, U., Sledge, J., Schwazerbanach, O. 1999. Treatment of thoracolumbar burst fractures without neurological deficit by indirect reduction and posterior instrumentation: Bisegmental stabilization with monosegmental fusion, *Eur Spine J.*, 8,284-89.
- Mumford, J., Weinstein, J.N., Spratt, K.F. 1993. Thoracolumbar burst fractures: the clinical efficacy and outcome of nonoperative management, *Spine* 18,955–70.
- Roer, N.V.D., Lange, E.S.M., Vet, H.C.W., Tulder, M.W. 2005. Management of traumatic thoracolumbar fractures: a systemic review of the literature, *Eur Spine J.*, 14,527-34.
- Romero, J., Vilar, G., Bravo, P. 1994. Fractures of the dorsolumbar spine with neurological lesions: a comparison of different treatments, *Int Orthop*, 18, 157–63.
- Shen, W.J., Shen, Y.S. 1999. Nonsurgical treatment of three-column thoracolumbar junction burst fractures without neurologic deficit, *Spine* 24,412–5.
- Siebenga, J., Vincent, J.M., Michiel, J.M., Elzinga, M.J., Bakker, F.C., Haarman, M.H. et al. 2006. Treatment of traumatic thoracolumbar spine fractures: A multicenter prospective randomized study of operative versus non surgical treatment, *Spine*, 31,2881-90.
- Tropiano, P., Huang, R.C., Louis, C.A. 2003. Functional and radiographic outcome of thoracolumbar and lumbar burst fractures managed by close orthopaedic reduction and casting, *Spine* 28, 2459–65.
- Weinstein, J.N., Collalto, P., Lehmann, T.R. 1988. Thoracolumbar ‘burst’ fractures treated conservatively: A long- term follow-up, *Spine*, 13, 33–8.

\*\*\*\*\*