



## CASE STUDY

### DIAGNOSING THE EFFECT OF FEMORAL ARTERIAL BLOOD FLOW UPON POPLITEAL ARTERIAL BLOOD FLOW USING ULTRASOUND

\*Muhammad Waqas Akhtar, Aalia Nazir and Zahida Batool

Department of Physics, The Islamia University of Bahawalpur, Pakistan

#### ARTICLE INFO

##### Article History:

Received 25<sup>th</sup> October, 2016  
Received in revised form  
24<sup>th</sup> November, 2016  
Accepted 10<sup>th</sup> December, 2016  
Published online 31<sup>st</sup> January, 2017

##### Key words:

MW study,  
Blood flow comparison,  
Lower limbs blood flow.

#### ABSTRACT

In lower limbs the femoral artery carries the oxygenated blood to the thigh region and hence leads the blood to the popliteal artery around the knee in human leg. This research was carried out to evaluate the blood flow through the popliteal artery in those cases in which the femoral artery shows monophasic type of waveform in ultrasound examination. Such five cases were chosen whose femoral artery showed monophasic pattern of waveform in ultrasound procedure and same cases were also diagnosed again for the blood flow through popliteal artery using a different ultrasound machine. Popliteal artery surrounds the knee portion and hence directly supplies the energy of the blood to the tissues of the knee. In obtained results it was observed that the Popliteal artery of such cases also showed monophasic type of waveform which lead this research study to the conclusion that the blood flow through the Popliteal artery depends upon the blood flow through the femoral artery of that particular case.

Copyright©2017, Muhammad Waqas Akhtar et al. This is an open access article distributed under the Creative Commons Attribution License, which permits unrestricted use, distribution, and reproduction in any medium, provided the original work is properly cited.

Citation: Muhammad Waqas Akhtar, Aalia Nazir and Zahida Batool, 2017. "Diagnosing the Effect of Femoral arterial blood flow upon Popliteal arterial blood flow using Ultrasound", *International Journal of Current Research*, 9, (01), 45665-45668.

## INTRODUCTION


Blood supply to different parts of the human leg is carried by numerous arteries. Among these one is femoral artery which carries blood in the thigh region of leg and the other is popliteal artery which surrounds the knee portion. Femoral artery starts from the common aorta as the common femoral artery and in entering to thigh region it is bifurcated as superficial femoral artery and deep femoral artery. Beside supply of blood to thigh region femoral artery carry blood further towards the knee region and is termed as popliteal artery which surrounds the knee in such a way to supply the energy of the oxygenated blood to knee tissues. In anatomy the Popliteal artery is basically the extension of femoral artery so it can be expected that blood flow in popliteal artery may depend upon the blood flow in femoral artery. In this research study the effect of blood flow in femoral artery upon the blood flow in popliteal artery have been explored. The use of Ultrasonography for the evaluation of blood flow in arteries was described by satomura in 1959. (Satomura 1959) Further Similar studies were carried later by Yao, Hobbs and Irvine by using ultrasound as a diagnostic tool for the assessment of blood flow through arteries (Yao, Hobbs et al., 1969).

Nayman also used Ultrasound as a diagnostic tool for the determination of vascular disease in 1974. (Nayman, 1974) In 1981 Demorais and Johnston studied the effect of arteriolic disease by the use of Doppler ultrasound. (Demorais and Wayne Johnston, 1981) Using ultrasound lateral studies were carried out by Evans, Persson, Gibbson and Griffey for the evaluation of arteriolic segments.(Evans, Macpherson et al. 1981) In 2014 Waqas studied the lower limb arterial blood flow for the assessment of blockages by using Doppler ultrasound technique. (Akhtar, 2014) Later in 2014 atherosclerotic changes in femoral artery were studied by Waqas using Doppler ultrasound. (Akhtar, 2014) In the continuation of these studies diseased Popliteal arteries were studied in 2015 by Waqas and Rao khan using Doppler ultrasound. (Akhtar and Khan, 2015) In these above mentioned studies since 2014 method of waveform analysis was used as an indicator and in this current study the same method has been employed as the continuation of previous studies.

## METHODS AND MATERIALS

Arterial blood flow in lower limb arteries can be assessed by the change in waveform obtained in the ultrasound image. In normal healthy condition the femoral artery and Popliteal artery shows a triphasic type of waveform in the ultrasound image (Akhtar, 2014) as in Figure 1:

\*Corresponding author: Muhammad Waqas Akhtar,  
Department of Physics, The Islamia University of Bahawalpur,  
Pakistan.



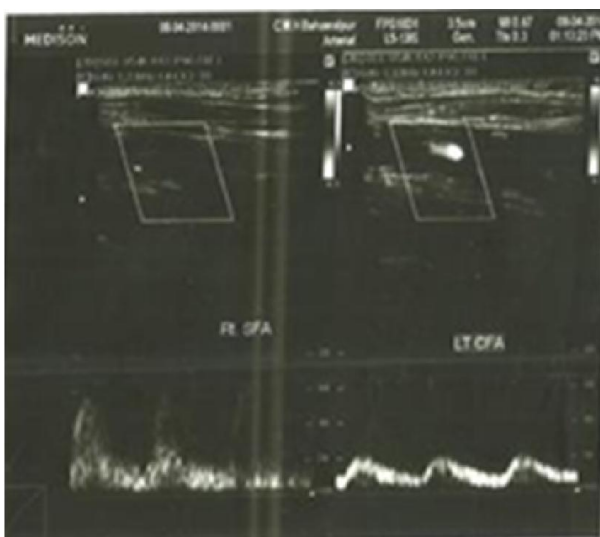
**Figure 1. Triphasic waveform**

In case of any kind of blockage or existence of stenosis or atherosclerosis the obtained waveform of femoral artery and Popliteal artery no longer remains triphasic, rather shows some changes which have been concluded in regular and previous studies of Waqas Akhtar since 2014. 05 cases were identified for showing the monophasic waveform by ultrasound examination of femoral artery. This monophasic waveform in ultrasound of femoral artery indicates the presence of some blockages in it. Same 05 cases were again undergone ultrasound examination of popliteal artery in order to detect any effect of blood flow through the femoral artery upon the blood flow in popliteal artery.

Method of detecting any change in the triphasic pattern of femoral was adopted to verify the blocked condition of femoral artery and same method was adopted to detect the effect on the blood flow through popliteal artery. GE Logic 500 ultrasound machine was used for the ultrasound examination of femoral artery and GE Logic 700 ultrasound machine was used for the assessment of popliteal artery.

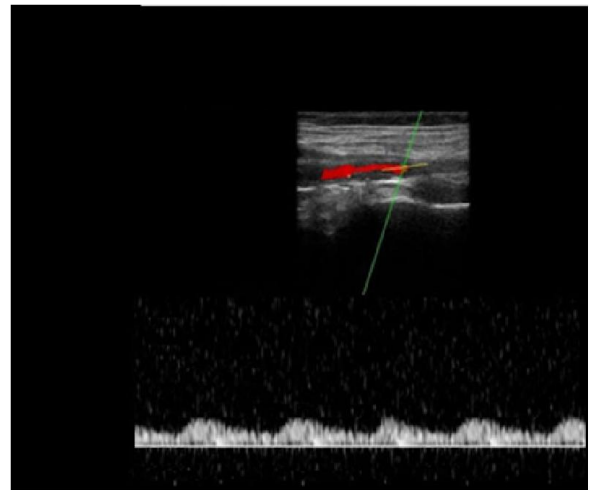
**RESULTS**

Femoral artery of case-1 showed monophasic pattern of waveform (see image-1A) instead of triphasic and hence displaying the blockage to blood flow through this artery. (Akhtar, 2014)



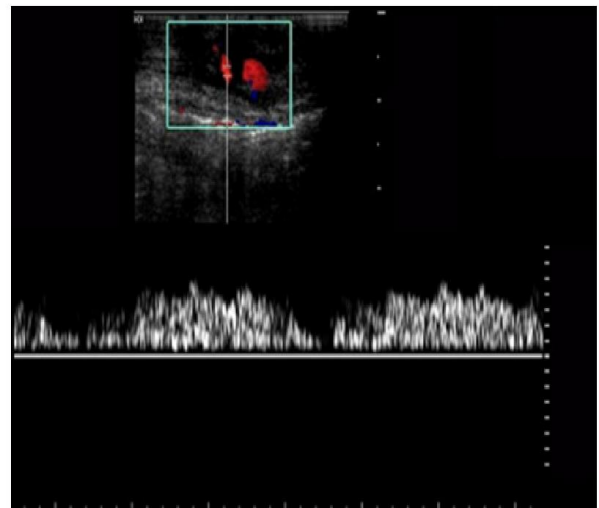
**Image 1A. monophasic pattern of Femoral artery**

Similarly the Popliteal artery of case-1 showed the monophasic type of waveform (see image-1B) indicating the blockage to blood flow within this artery (Akhtar, 2014).



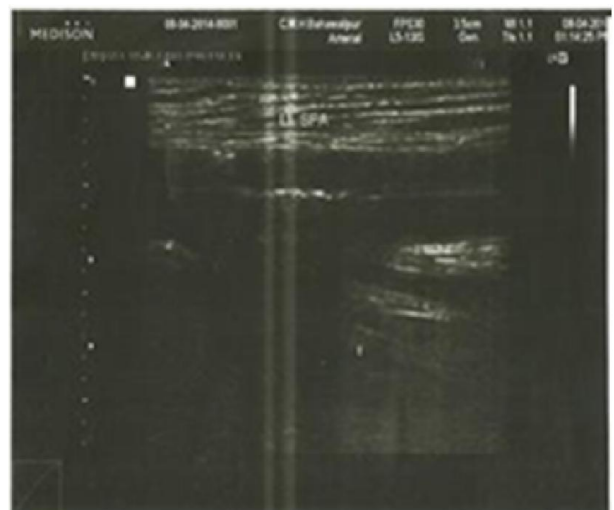
**Image 1B. monophasic pattern of popliteal artery**

Monophasic waveform (see image-2A) was obtained for case-2 indicating the blockage in blood flow through femoral artery (Akhtar, 2014).



**Image 2A. blocked femoral artery monophasic waveform**

Case-2 showed no waveform (See image 2B) for the Popliteal artery showing the high level of blockage in blood flow through this artery. (Akhtar, 2014)



**Image 2B. Blocked popliteal artery**

Case -3 showed monophasic waveform (see image 3A) to indicate the blocked femoral artery. (Akhtar, 2014)

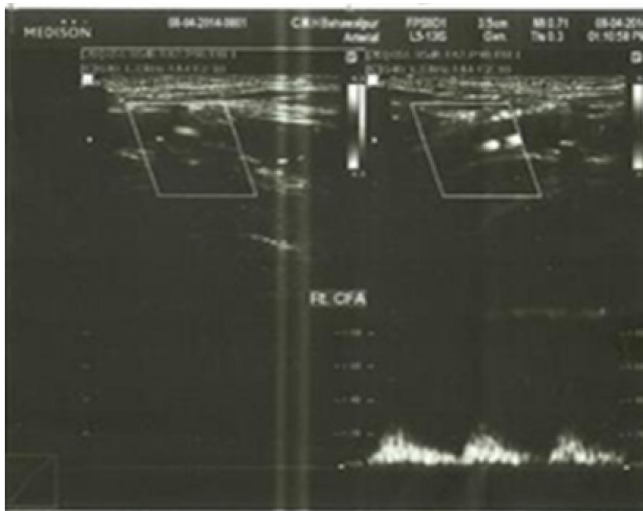


Image-3A. monophasic pattern of blocked femoral artery

Popliteal artery of case -3 showed blockage of blood flow (see image-3B) by displaying the monophasic waveform. (Akhtar, 2014)

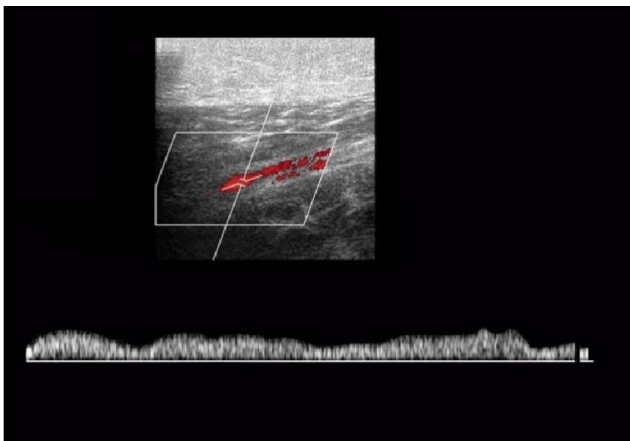


Image 3B. Monophasic waveform of blocked popliteal artery

Blockage of blood flow in femoral artery (see image-4A) was indicated by the monophasic type of waveform. (Akhtar, 2014)

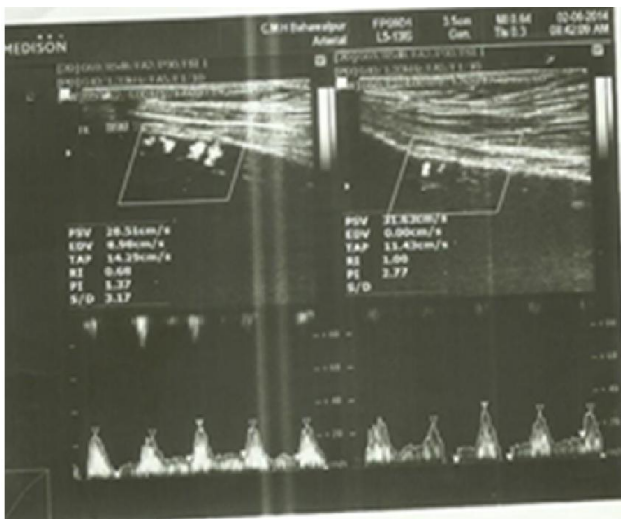


Image-4A. blocked femoral artery monophasic waveform

Similarly the Popliteal artery of case-04 showed monophasic waveform (See image-4B) to indicate the blockage of blood through this artery (Akhtar, 2014).

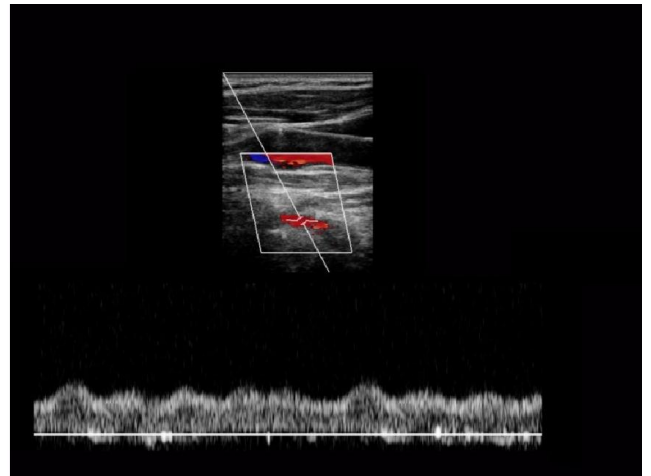


Image 4B. Monophasic waveform of blocked popliteal artery

Case-5 showed the monophasic waveform (see image-5A) to indicate the blockage in the femoral artery (Akhtar, 2014).

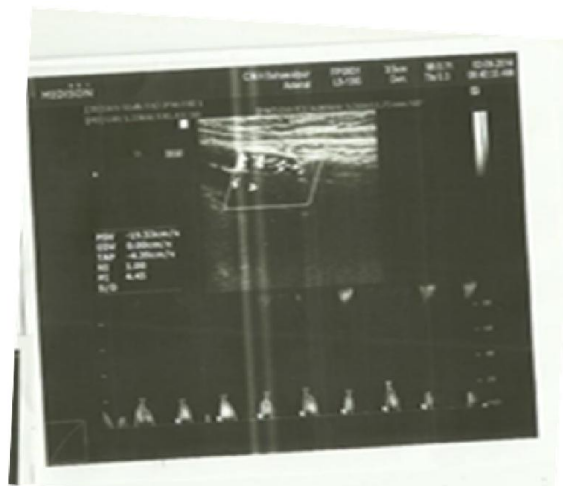

Image 5A. blocked femoral artery monophasic waveform

Similarly the Popliteal artery of case-5 showed the blockage (See image-5B) in it by displaying the monophasic waveform (Akhtar, 2014).

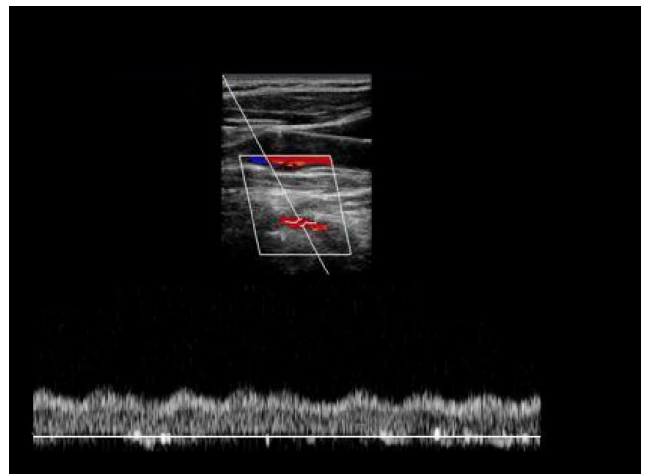


Image 5B. monophasic waveform of blocked popliteal artery

## DISCUSSION

When the radius of femoral artery is reduced due to some blockage which can be any stenosis or cholesterol then there is a chance that blood will follow the turbulent flow in sudden as passing from that particular point which will increase the speed of blood flow. This increase in speed of blood may also affect the speed of blood through the popliteal artery. Hence the ultrasound pattern of popliteal artery may also show divergence from the normal triphasic type of waveform. Above mentioned cases belongs to that class in which femoral artery shows monophasic pattern of waveform and hence indicating the blockage in blood flow or increase in the speed of blood flow or decrease in radius of femoral artery through the particular region. When such cases were also diagnosed for the blood flow through the Popliteal artery it was seen that Popliteal artery showed the divergence from the normally obtained ultrasound waveform and producing the monophasic type of waveform. From this observation it appears as if the femoral artery of any case is carrying some kind of blockage then it may also effect the blood flow through the Popliteal artery which is the very next of femoral artery or in other words it can also be suggested that the condition of blood flow through the Popliteal artery depends upon the conditions of blood flow through the femoral artery.

## Conclusion

From the above mentioned observations and discussion it can be concluded that if femoral artery of human leg is carrying some blockage then this will not only affect the blood flow

through itself but also to the blood flow in Popliteal artery. Hence it can be deduced that the blood flow through popliteal artery depends upon the blood flow through the femoral artery.

## REFERENCES

- Akhtar, M. W. 2014. "Diagnostic Ultrasound for the detection of Atherosclerotic changes inside Femoral arteries of lower limb" *IJTRA*, 2(6):98-101.
- Akhtar, M. W. 2014. "Doppler Ultrasound for the Existence of Blockage in Lower Limb Arteries." *IJSF*, 2(3): 73-79.
- Akhtar, M. W. and R. A. Khan 2015. "Diagnostic study of diseased Popliteal arteries of human leg." *IJMRD*, 2(2): 506-510.
- Demorais, D. and K. Wayne Johnston 1981. "Assessment of aorto-iliac disease by non-invasive quantitative Doppler waveform analysis." *British Journal of Surgery*, 68 (11): 789-792.
- Evans, D. and D. Macpherson 1981. "The effect of proximal stenosis on Doppler waveforms: a comparison of three methods of waveform analysis in an animal model." *Clinical Physics and Physiological Measurement*, 2(1): 17.
- Nayman, J. 1974. "The use of the ultrasonic flow meter in peripheral vascular disease." *Australian and New Zealand Journal of Surgery*, 44(2): 157-167.
- Satomura, S. 1959. "Study of the flow patterns in peripheral arteries by ultrasonics." *J. Acoust. Soc., Japan* 15: 151-155.
- Yao, S. and J. Hobbs 1969. "Ankle systolic pressure measurements in arterial disease affecting the lower extremities." *British Journal of Surgery*, 56(9): 676-679.

\*\*\*\*\*