



## RESEARCH ARTICLE

### MULTIPLE IMPACTED SUPERNUMERARY TEETH IN A NON SYNDROMIC PATIENT: A CASE REPORT AND REVIEW OF LITERATURE

**\*Dr. Nithya Annie Thomas, Dr. Priya Shetty, Dr. Charvi Chawla, Dr. Ann Thomas and Dr. Sowmya B. Shetty**

Department of Pedodontics and Preventive Dentistry, A.J. Institute of Dental Sciences, Mangalore, India

#### ARTICLE INFO

##### Article History:

Received 03<sup>rd</sup> November, 2016

Received in revised form

16<sup>th</sup> December, 2016

Accepted 15<sup>th</sup> January, 2017

Published online 28<sup>th</sup> February, 2017

##### Key words:

Supernumerary teeth,

Non syndromic, Multiple

#### ABSTRACT

Supernumerary teeth are considered as a bizarre rise in the number of naturally occurring teeth. Only some examples of nonsyndromic multiple supernumerary teeth have been reported in literature. In this report, we present a case of multiple unerupted bilateral supernumerary teeth without any associated syndrome in a seven year old child as a result of a casual finding during routine X ray study. A panoramic radiograph revealed multiple impacted supernumerary teeth which were diagnosed during routine radiographic evaluation. Based on the clinical examination and radiographic investigation, a diagnosis of idiopathic hyperdontia was given. In such cases, management should be planned by a multidisciplinary approach.

Copyright©2017, Nithya Annie Thomas et al. This is an open access article distributed under the Creative Commons Attribution License, which permits unrestricted use, distribution, and reproduction in any medium, provided the original work is properly cited.

Citation: Dr. Nithya Annie Thomas, Dr. Priya Shetty, Dr. Charvi Chawla, Dr. Ann Thomas and Dr. Sowmya B. Shetty, 2017. "Multiple impacted supernumerary teeth in a non syndrome patient : a case report and review of literature", *International Journal of Current Research*, 9, (02), 46331-46335.

## INTRODUCTION

Supernumerary teeth, also called hyperdontia are those odontostomatologic anomalies that are present in excess of the normal set of teeth. It was first reported between 23 and 79 AD (WZ, 1990). Supernumerary teeth may be defined as any teeth or tooth substance in excess of the usual configuration of 20 deciduous and 32 permanent teeth. A supernumerary tooth is also defined as one that is additional to the normal series and can be found in almost any region of the dental arch (Garvey, 1999). Hyperodontia maybe single, double, or multiple teeth, that occur in one or both jaws; erupted or unerupted and unilateral or bilateral. Supernumeraries are less frequently observed in primary dentition (Szu-Ting Chou, 2015). In majority of the cases, multiple supernumerary teeth are related with other conditions such as cleft lip and palate, or with syndromes like Cleidocranial dysostosis, Gardner's syndrome, Fabry – Anderson's syndrome, chondroectodermal dysplasia, Rothmund – Thompson syndrome and Nance – Horan syndrome (Deepti Amaral, 2015). Sometimes it can occur without being associated with any syndromes. This is an uncommon condition and mostly asymptomatic. The diagnosis is usually made as a result of a random finding during routine panoramic X-ray studies (Subhadeep Maity, 2015). It can be characterised as "real" if determined by an increased number of teeth and is considered "false" if caused by a delay in shedding of primary teeth beyond the transition period

(Thiago de Santana Santos1, 2014). In a study by M. Nazargi Mahabob *et al.*, (2012) in South India, the prevalence of supernumerary teeth was found to be 1.2%, with a greater incidence in males (1.49%) than in females (0.85%). The greatest frequency of supernumerary teeth was found in the maxillary anterior region (77.8%) out of which 85.7% were categorised as mesiodens based on their position (Nazargi Mahabob, 2012). The estimated prevalence in the sub-Saharan Africa and Asian population is reported between 2.7% and 3.4 % with Asians showing a reasonably higher frequency (Ferrés-Padró, 2009). Only 1% of non-syndromic cases have multiple supernumerary teeth, which occur most commonly in the mandibular premolar area, followed by the molar and the anterior regions, respectively (Subhadeep Maity, 2015). Supernumerary teeth are more often found in males than in females. Many authors have reported a male–female ratio of 2:1 (Rajab, 2012). Supernumerary teeth maybe malformed morphologically or normal in size and shape, straight or inverted in position. Cases involving one or two supernumerary teeth show a predilection for the anterior maxilla, followed by the mandibular premolar region. In other regions, differences have been reported in the relative frequency of these teeth. Cases involving multiple supernumeraries (more than five) tend to be commonly seen in the mandibular premolar region (Rajesh, 2014). Chronologically, they are classified as pre-deciduous, similar to permanent teeth, and post permanent or complementary. Topographically, they are described as mesiodens, paramolar, distomolar and para-premolar, and according to orientation as vertical, inverted and transverse; morphologically, they are

\*Corresponding author: Dr. Nithya Annie Thomas,  
Department of Pedodontics and Preventive Dentistry, A.J. Institute of Dental Sciences, Mangalore, India.

classified as conical, tuberculate, supplemental (eumorphic) and odontome (Parolia Abhisek, 2011). In primary dentition, the typical morphology is normal or conical. In permanent dentition, morphological variation is greater (Szu-Ting Chou, 2015). Both genetic and environmental factors have been considered to play a role in the etiology of supernumerary teeth. The theories put forward are as follows:

- *Atavism theory*, which suggests that supernumerary teeth are a result of phylogenetic reversion to extinct primates with three pairs of incisors- (evolutionary throwback). However, this theory has been largely discounted.
- *Dichotomy theory*, which suggests that the tooth bud splits into two equal or different-sized parts, resulting in the formation of two teeth of equal size, or one normal and one dysmorphic tooth respectively. This theory has also been discounted.
- *Dental lamina hyperactivity theory*, which suggests localized, independent, conditioned hyperactivity of the dental lamina. According to this theory, a supplemental form develops from the lingual extension of an accessory tooth bud, whereas a rudimentary form develops from the proliferation of epithelial remnants of the dental lamina. Though all theories are hypothetical because of the inability to obtain sufficient embryological material, this is the most accepted theory (Deepti Amaral, 2013).
- Current genetic studies have also recognized the presence of ectodine, described as a third dentition inhibitor protein (Thumati, 2014; Venkataraghavan, 2011).

The clinical complication associated with supernumerary teeth are eruption failure, rotation or displacement of the adjacent teeth, dilacerations, root resorption, crowding, malocclusion, fistulas and cystic formation, diastema, retention or delayed/ectopic eruption, delayed or abnormal root development of permanent teeth and dental caries and periodontal lesions due to compression of adjacent roots and pulp necrosis (Subasioglu, 2015). Radiographic data for supernumerary teeth are conventionally obtained by periapical, occlusal, panoramic, or cephalometric radiographs. Panoramic radiographs are unreliable for identifying supernumerary teeth as they are located outside the focal trough and are not clearly depicted in the panoramic view. In previous studies, three-dimensional images obtained by cone beam computed tomography clearly depicted the orientation of supernumerary teeth, their sagittal position, local disorders, and neighbouring anatomic structures which are useful for pre-treatment evaluation of supernumerary teeth. For these reasons, the routine use of CBCT (cone beam computed tomography) is recommended in patients with supernumerary teeth (Szu-Ting Chou, 2015).

## CASE REPORT

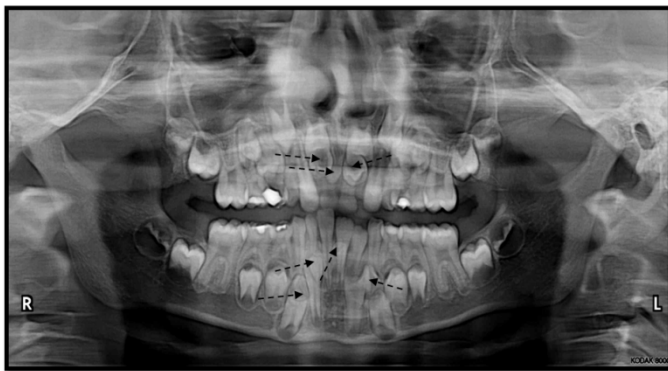A 7 year old boy reported to the department of Pedodontics and preventive dentistry, A.J. Institute of Dental Sciences, Mangalore complaining of decay in his primary teeth in the upper right quadrant. The patient had no complaint of pain or signs of infection and was in good general health. The patient had a normal facial appearance and did not exhibit any physical or skeletal abnormality.

Intra oral examination revealed presence of mixed dentition with class I molar relationship and class I canine on the right and left side. Since the parent was concerned about the delayed eruption of the child's permanent upper incisors, an investigative intra oral peri apical radiograph was taken to assess the status of development of 11 and 21. Surprisingly, three radiolucencies which resembled supernumerary teeth were seen in the region anterior to the 11 and 21. An OPG was taken to rule out any unerupted supernumerary teeth (Figure 1) which showed multiple unerupted supernumerary teeth- three in the maxilla and four in the mandible. The OPG revealed normal bilateral condyle and coronoid process with the presence of mixed dentition. There was the presence of erupting tooth buds of maxillary and mandibular canines, premolars, second and third molars and maxillary incisors and mandibular lateral incisors.

The radiograph also revealed the presence of a mesiodens located between the roots of the maxillary primary incisors. There were two supplemental teeth located adjacent to the mesiodens, below the tooth buds of the permanent incisors in the maxilla. There were four impacted supernumerary teeth in the mandible - two canine like supplemental teeth located bilaterally in relation to the developing tooth buds of the mandibular lateral incisors, one supplemental tooth in relation to the erupting 33 and one incisor like supplemental tooth between the roots of 31 and 41. In view of the multiple impacted supernumerary teeth, a clinical examination was done to rule out syndromes associated with multiple impacted supernumerary teeth. Family history revealed that the father had supernumerary teeth. The patient was hence diagnosed with nonsyndromic multiple supernumerary teeth. After a period of 6 months, the patient was recalled to evaluate the status of eruption of the permanent central incisors and the supernumerary teeth. 8X8 CBCT (New Tom 9000) was carried out to evaluate the current status of the teeth and to rule out any fusion of the supernumeraries to the permanent teeth in the maxillary and mandibular regions (Figure 4). The CBCT revealed that the supernumerary teeth (2 supplemental and 1 mesiodens) in the maxillary portion were located palatal to the central incisors and there was no fusion of any of the teeth or signs of disturbance to the path of eruption of the permanent teeth. There was no bone coverage with respect to the permanent central incisors. Controversy exists regarding the optimal treatment time and treatment modality for impacted supernumerary teeth. Inverted and transverse supernumerary teeth would be suggested for surgical removal on first diagnosis and normally oriented supernumerary teeth would be monitored for eruption, in which case simple extraction should be performed (Mallineni and Nuvvula, 2015). According to Garvey *et al.*, extraction is not always the treatment of choice for supernumerary teeth. They may be monitored without removal when satisfactory eruption of related teeth has occurred if there is no orthodontic treatment required, if there is no associated pathology and if removal would prejudice the vitality of the related teeth. In our case, there were no other findings noted on intra-oral examination in terms of any disturbances to the adjacent dentition. The patient was informed about the presence of supernumerary teeth, and a periodic follow up was planned to review the status every six months. Furthermore, extraction was advised with respect to the retained maxillary deciduous incisors. Several authors opted to leave the supernumerary teeth in situ due to the absence of any signs or symptoms that indicated their extraction (Thiago de Santana Santos, 2014).

**Table 1. Recently reported non Syndromal Multiple Supernumerary teeth**

S.No.	Author	Year	Age/ Sex	No of supernumerary teeth
1	Katsu Takahashi	2016	13/M	6
2	Katsu Takahashi	2016	10/M	5
3	Brigette Wendl	2016	11/M	3
4	C V Cruz	2016	10/M	9
5	Asutay	2015	13/M	11
6	T S Santos	2014	12/F	14
7	Ma Y	2014	14/F	13
8	Lei Yan	2014	14/F	19
9	Mine Bozkurt	2014	10/F	11
10	David Ditto S	2014	11/M	5
11	Dai Juan and Feng Xue	2013	14/M	5
12	Afroz Alam Ansari	2013	14/M	13
13	Ledesma Brauer	2012	12/F	12
14	Yeluri	2012	11/M	6
15	Garcés-Ortiz LM	2012	12/F	12
16	Marilia Nalon Pereira	2011	11/F	31
17	Brauer HU	2010	14/M	13
18	Gomes, Carlos de Oliveira	2008	3 patients, 8-12 years	3 patients collectively developed a total of 17 ST, with 9 found in a single patient

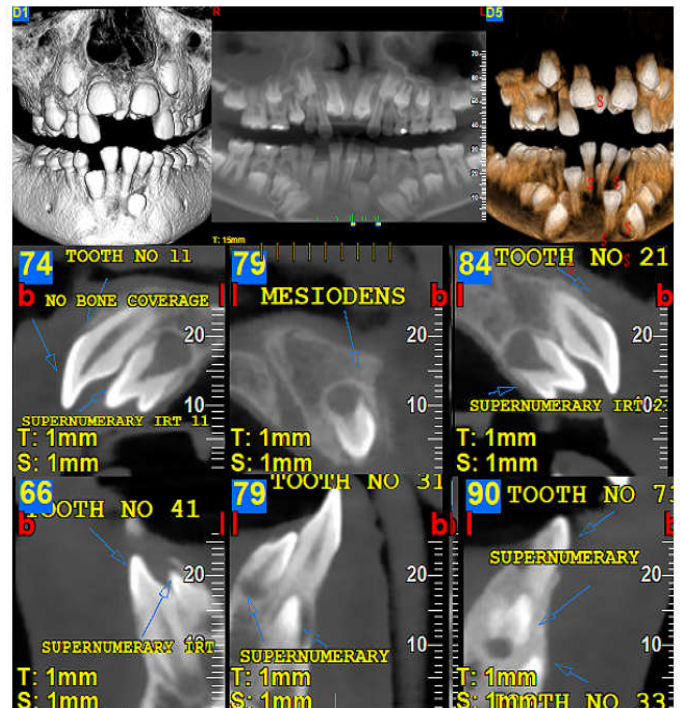


**Figure 1. Digital panoramic radiograph showing the presence of 7 supernumerary teeth- three supernumerary teeth seen in the maxillary canine-canine area bilaterally and four in the mandibular canine- canine region bilaterally. The arrows represent the supernumerary teeth**

The proposed treatment plan consisted of extraction of the retained deciduous incisors and periodic check-ups. Following administration of local anaesthesia, extraction of the deciduous maxillary incisors was performed to allow the impacted mesiodens to erupt spontaneously or to facilitate its eruption. It has been found that 75% of impacted teeth may erupt within 18 months of removal of the supernumerary tooth (Di Biase, 1969). Presently, the patient is being followed up through semi-annual recall examinations. The decayed teeth were restored followed by preventive oral health measures. Thus, it was decided to allow for the spontaneous eruption of the permanent central incisors and the supernumerary teeth following which the extraction of the supernumeraries would be carried out.

## DISCUSSION

A systematic search based on the keywords “Non-syndromic multiple supernumerary teeth” and “multiple supernumerary teeth not associated with syndrome” from of children between 6-14 years having more than 5 supernumerary teeth without any syndromic trait between 2006-2016 yielded 18 favourable results.



**Figure 4. Cone beam computed tomography images showing location of supernumerary teeth. (a) Three supernumerary teeth seen in the maxillary anterior cross sectional view (b) Four supernumerary teeth seen in the mandibular cross sectional view, as a cluster of two impacted teeth on each side all of which were anteriorly located; (c and d) Three dimensional reconstruction of the anterior portion of the maxilla and mandible showing a total of 7 supernumerary teeth all of which were unerupted**

According to a study by Yusof *et al.*, the prevalence for non-syndromic multiple supernumerary teeth, five or more in number, is >1% with a male to female ratio of 9:2 (Thumati, 2014). In this case, the supernumerary teeth were found in the mandibular and maxillary canine - canine region. In the patient reported herein, supernumerary teeth were not related to any syndromes nor associated with any systemic condition. The hereditary factor is believed to be important for the development of supernumerary teeth. There may be transmission of a recessive or dominant autosomal trait with

incomplete penetrance, or the condition may be associated with an X chromosome (Thiago de Santana Santos, 2014). It has been stated that in cases of hyperdontia with one to four supernumerary teeth, the supernumerary teeth are localized in the upper anterior and molar region, while multiple supernumerary teeth (i.e. five or more) are seen in the lower jaw and generally in the premolar region. However, where “multiple supernumerary teeth” is taken to mean five or more supernumerary teeth, the prevalence has been reported as 0.06% according to Acikgoz *et al.*, 2006.

Multiple supernumerary teeth are rare, with a reported prevalence of 0.2 to 0.8% in deciduous dentition and 0.5 to 5.3% in permanent dentition with geographic variations (Thiago de Santana Santos, 2014). In addition, the occurrence of multiple supernumerary teeth is less common than the occurrence of a single supernumerary tooth and is even rarer in the absence of a systemic condition or syndrome (Rajabm, 2002; Moraes, 2007). Studies show that 76 - 86% of non syndromic cases involve only one supernumerary tooth and that 12 to 23% of cases present two supernumerary teeth. Analysis of supernumerary teeth cases shows that the variation is small, with the presence of one or two supernumerary teeth being more frequent. A single supernumerary tooth occurs in 72 to 77% of cases, two occur in 18 to 27%, and three in only 1 to 5% (Thiago de Santana Santos, 2014). The incidence of supernumerary teeth is generally higher in males (Wan Hassan, 2012), affecting premolars in approximately 10% of cases and almost 75% of these cases occur in the mandible. Only 1% of nonsyndromic cases present multiple supernumerary teeth, which occur more frequently in the area of the mandibular premolars and in the anterior region (Thiago de Santana Santos, 2014). CBCT is the method of choice for this owing to its lower radiation dose and cost compared to CT. The karyotype determination is another useful method for excluding a chromosomal pathogenesis in cases of multiple nonsyndromic supernumeraries (Thumati, 2014). Management of supernumerary teeth should be a part of a comprehensive treatment plan. There are several controversies and variety of opinion among the authors regarding the timing of removal of supernumerary teeth. Rotberg *et al.* (1984) suggested that extraction should be initiated before 5 years of age, so that root formation of permanent incisors is incomplete. According to Hogstrum and Andersson *et al.* (1987) supernumerary teeth should be removed as soon as diagnosed. Later they suggested it could be left until the root development of the adjacent tooth is complete. In the year 2008, Shah *et al* suggested that if the supernumerary teeth causes no complications and are not likely to interfere with orthodontic tooth treatment, they can be monitored with the yearly radiographic review. Omar *et al.* (2010) suggested that if there is no adverse effect associated with supernumerary teeth and if no future orthodontic intervention is foreseen; immediate surgical intervention is not recommended (Deepti Amaral, 2013; Subhadeep Maity, 2015).

## Conclusion

Different management options are available for patients with multiple hyperdontia not associated with complex syndromes, which may include extraction, followed by orthodontic treatment to ensure proper occlusion or continuous periodic monitoring of such teeth to minimize the risk of complications secondary to them. On diagnosis, each case should be managed

appropriately in order to minimize complications to the adjacent dentition.

## REFERENCES

- A Acikgoz GAUTFO. Characteristics and prevalence of non-syndromic multiple supernumerary teeth: a retrospective study. *Dentomaxillofacial Radiology*. 2006;(35): p. 185–190.
- Ansari AA, Malhotra S, Pandey RK, Bharti K. Non-syndromic multiple supernumerary teeth: report of a case with 13 supplemental teeth. *BMJ case reports*. 2013 Mar 6; 2013: bcr2012008316. .
- ARATHI R AR. Supernumerary teeth: A case report. *J Indian Soc Pedod Prev Dent.*, June 2005.
- Asutay F, Acar AH, Kirtay M, Alan H, Atalay Y. Multiple Bilateral 11 Supernumerary Teeth with Forth Molars in a Non-Syndromic Patient: An Unusual Case Report. *J Dent App.*, 2015;2(4):207-9.
- Bozkurt M, Bezzin T, Tüzüner Öncül A, Göçer R, Sarı Ş. Late developing supernumeraries in a case of nonsyndromic multiple supernumerary teeth. *Case reports in dentistry*. 2015 Jan 11.
- Brauer HU. Case report: non-syndromic multiple supernumerary teeth localized by cone beam computed tomography. *Eur Arch Paediatr Dent.*, 2010 Feb; 11(1):41-3.
- Ledesma-Montes, C, J.F. Salcido-García, F. Hernández-Flores, and M. Garcés-Ortiz, 2012. Multiple Supernumeraries in a Non-Syndromic Patient. *Journal of Clinical Pediatric Dentistry*, December 2012, Vol. 37, No. 2, pp. 193-197. .
- C. S. Developmental abnormalities of teeth and jaws. In In Gorlin RJ GH. Thoma's Oral Pathology St Louis.: CV mosby, 1970. p. 112-122.
- Cruz, C.V., Soares, A.L., Braga, D.N., Costa, M.C. 2016. Diagnosis and Surgical Management of Nonsyndromic Nine Supernumerary Teeth and Leong's Tubercle. *Case reports in dentistry*, Mar 15.
- David Ditto, S., Akhila, R. 2014. Management of Multiple Impacted Supernumerary Teeth in a Non-Syndromic Patient using Cone Beam CT. *Dentistry*, 4(190):2161-1122.
- Deepti Amaral, M.M. 2013. Supernumerary teeth: Review of literature and decision support system. *Indian J Dent Res.*, 24(1).
- Di Biase, D.D. 1969. Midline supernumeraries and eruption of the maxillary central incisor. *The Dental practitioner and dental record*, Sep; 20(1):35.
- Ferrés-Padró E PAJFAE. A descriptive study of 113 unerupted supernumerary teeth in seventy-nine pediatric patients in Barcelona. *Med Oral Patol Oral Cir Bucal.*, 2009; 14(3): p. 46-52.
- Garvey MT BIBM. Supernumerary teeth – an overview of classification, diagnosis, and management. *J Can Dent Assoc.*, 1999; (65): p. 612 6.
- Katsu Takahashi YTKSHKBHHTKFKB. Two non-syndromic cases of multiple supernumerary teeth with different characteristics and a review of the literature. *Journal of Oral and Maxillofacial Surgery, Medicine, and Pathology*. 2016 May; 28(3): p. 250–254.
- Ledesma-Montes, C., Salcido-García, J.F., Hernández-Flores, F., Garcés-Ortiz, M. 2012. Multiple supernumeraries in a non-syndromic patient. *Journal of Clinical Pediatric Dentistry*, Dec 1;37(2):193-7.
- Nazargi Mahabob, M. GJABSKSRSK. Prevalence rate of supernumerary teeth among non-syndromic South Indian

- population: An analysis. *J Pharm Bioall Sci.*, 2012; 4: p. 373-5.
- Ma, Y., Lin, C.X., Zhu, X.H., Ding, X. 2014. The Multidisciplinary Management of a Nonsyndromic Patient With 13 Supernumerary Teeth and Dentigerous Cyst. *Journal of Craniofacial Surgery*, Nov 1;25(6):2255-7.
- Mallineni, S.K., Nuvvula, S. 2015. Management of supernumerary teeth in children: A narrative overview of published literature. *Journal of Cranio-Maxillary Diseases*, Jan 1;4(1):62.
- MJ K. Unerupted premaxillary supernumerary teeth. A study of their occurrence in males and females. *Br Dent J.*, 1982;(153): p. 110.
- Mopager V SPARKSTA. Supplemental premolars in a 13 year old child - a case report. *J Indian Soc Pedod Prev Dent*, 2002; (20): p. 169-172.
- Moraes MEL MLDGDPSL. Dental anomalies in patients with Down syndrome. *Braz Dent J.*, 2007; 18: p. 346-50.
- Ozlem Marti Akgun FSAACA. Non-syndrome patient with bilateral supernumerary teeth: Case report and 9-year follow-up. *European Journal of Dentistry*, 2013 January; 7: p. 123-6.
- Parolia Abhisek KM, DMMMaTMS. Management of Supernumerary Teeth. *Journal of Conservative Dentistry*. 2011; 14(3): p. 221-224.
- Pavithra S AN. Mesiodens with an unusual morphology and multiple impacted supernumerary teeth in a non-syndromic patient. *Indian J Dent Res.*, 2007; (18): p. 138-40.
- Pereira MN, de Almeida LE, Martins MT, da Silva Campos MJ, Fraga MR, Vitral RW. Multiple hyperdontia: Report of an unusual case. *American Journal of Orthodontics and Dentofacial Orthopedics*, 2011 Oct 31; 140(4):580-4.
- Rajab LD HM. Supernumerary teeth: Review of the literature and a survey of 152 cases. *Int J Paediatr Dent.*, 2002; (12): p. 244-54.
- Rajesh T Anegundi VSTPBATSP. Prevalence and characteristics of supernumerary teeth in a non-syndromic South Indian pediatric population. *J Indian Soc Pedod Prev Dent.*, 2014; 32(1): p. 9-12.
- Russell KA FM. Mesiodens-diagnosis and management of a common supernumerary tooth. *J Can Dent Assoc.*, 2003: p. 362-6.
- Subasioglu A SSKEKSYADM. Genetic background of supernumerary teeth. *Eur J Dent.*, 2015; 9(1): p. 153-8.
- Subhadeep Maity RRKVNRRKaNB. Multiple Permanent Impacted Supernumerary Teeth in a Non-Syndromic Patient- A Case Report with a Review of Literature. *International Journal of Advanced Dental Science and Technology*, 2015; 2(1): p. 47-52.
- Szu-Ting Chou HPCYHYLYCTCYPJHC. Characteristics of supernumerary teeth among nonsyndromic dental patients. *Journal of Dental Sciences*, 2015 March; 10(133-138): p. 133-138.
- Thiago de Santana Santos1 ERSACFFdMFSPX. Multiple Supernumerary Teeth in a Nonsyndromic 12-Year-Old Female Patient - A Case Report. *Brazilian Dental Journal*, 2014; 25(1) 25(1): p. 79-82.
- Thumati, P DCTR. Non-syndromic multiple supernumerary teeth: A case report and review of literature. *IJSS Case Reports & Reviews*, 2014; 1(5): p. 1-5.
- Venkataraman K. Mandibular Mesiodens with Agenesis of Central Incisors (Hypohyperdontia): A Case Report & Review. *International Journal of Contemporary Dentistry*, 2011 Aug 16;2(4).
- Wan Hassan, W.N. NAR. Non-syndromic familial supernumerary teeth: case report and review of their phenotypic characteristic. *Ann Dent Univ Malaya*. 2012; 19(1): p. 28-35.
- Wendl, B., Muchitsch, A.P., Droschl, H., Santler, G., Truschnegg, A., Jakse, N.A. 2016. Therapeutic Approach for Two Patients with Multiple Supernumerary and Impacted Teeth. *JCR*, 6:51-57.
- WZ Y. Non syndrome multiple supernumerary teeth: Literature review. *J Can Dent Assoc.*, 1990; 56:147-9: p. 147-9.
- Xue, D.J. 2013. Combined Orthodontic-surgical Treatment for Skeletal Class III Malocclusion with Multiple Impacted Permanent and Supernumerary Teeth: Case Report. *The open dentistry journal*, Dec;8:43-8.
- Yan, L., Yu, L.W., Bhandari, K., Shan, C.L. 2014. Report of a case with 19 supernumerary teeth in a non-syndromic patient. *Indian Journal of Dentistry*, Aug 31;5:90-3.
- Yeluri, R., Hegde, M., Baliga, S., Munshi, A.K. 2012. Multiple supernumerary teeth associated with an impacted maxillary central incisor: Surgical and orthodontic management. *Contemporary clinical dentistry*, Apr;3(2):219.

\*\*\*\*\*