



## RESEARCH ARTICLE

### ORO-FACIAL-DIGITAL SYNDROME

<sup>1,\*</sup>Pramila Padmini Mishra and <sup>2</sup>Narasinga Rao Bhattam

<sup>1</sup>Associate Professor, Department of Anatomy, Gitam Institute of Medical sciences and Research, Rushikonda, Visakhapatnam, Andhra Pradesh, India

<sup>2</sup>Professor, Department of Anatomy, Gitam Institute of Medical sciences and Research, Rushikonda, Visakhapatnam, Andhra Pradesh, India

#### ARTICLE INFO

##### Article History:

Received 05<sup>th</sup> December, 2016

Received in revised form

17<sup>th</sup> January, 2017

Accepted 25<sup>th</sup> February, 2017

Published online 31<sup>st</sup> March, 2017

#### ABSTRACT

Oral-facial-digital syndrome affects maxillofacial regions, hands and feet. Type 1 (OFD1) is a rare condition with X-linked dominant inheritance caused by mutations in the *Cxorf5* (OFD1) gene. This condition almost always causes intrauterine lethality in males. A still born male foetus was procured as a part of research work in the department of anatomy. The foetus presented bilateral cleft lip and palate, polydactyly of hands and feet and clinodactyly of right hand and gastroschisis. Different types of OFD's overlap and genetic evaluation is required to place it in a particular type of OFD's.

#### Key words:

Cleft Palate, Clinodactyly,  
Polydactyly,  
Oro Facial Digital Syndrome,  
X-Linked Inheritance.

Copyright©2017, Pramila Padmini Mishra and Narasinga Rao Bhattam. This is an open access article distributed under the Creative Commons Attribution License, which permits unrestricted use, distribution, and reproduction in any medium, provided the original work is properly cited.

Citation: Pramila Padmini Mishra and Narasinga Rao Bhattam. 2017. "Oro-facial-digital syndrome", *International Journal of Current Research*, 9, (03), 47293-47295.

## INTRODUCTION

Oral-facial-digital syndromes (OFDS) represent a group of rare developmental disorders characterized by abnormalities of the face, oral cavity and digits. Additional signs involving the central nervous system (CNS), and visceral organs, such as the kidney, are also frequently observed. The first case presenting this condition was reported in 1941 (Mohr, 1941) and since then a number of different OFDS types with overlapping phenotypes have been described (Toriello 1992, Gurrieri *et al.*, 2007). Among the different types, OFD type I is the most frequently observed and can be easily recognized by its typical X-linked dominant male-lethal pattern of inheritance in familial cases. Most of the other OFDS are transmitted as autosomal recessive syndromes or represent sporadic cases. In the last few years, 11 genes responsible for OFDS have been identified allowing a better clinical and genetic definition for this heterogeneous condition.

#### Case report

In the present case, a still born male foetus of 34 wks of gestation was procured as a part of research work from local private hospital.

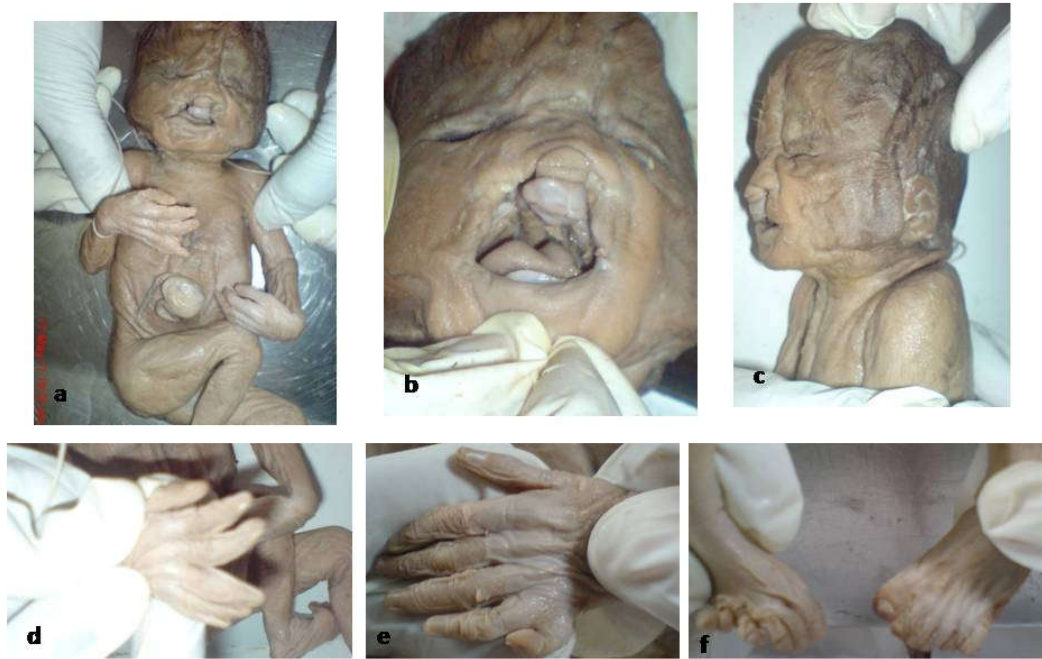
\*Corresponding author: Pramila Padmini Mishra,

Associate Professor, Department of Anatomy, Gitam Institute of Medical sciences and Research, Rushikonda, Visakhapatnam, Andhra Pradesh, India.

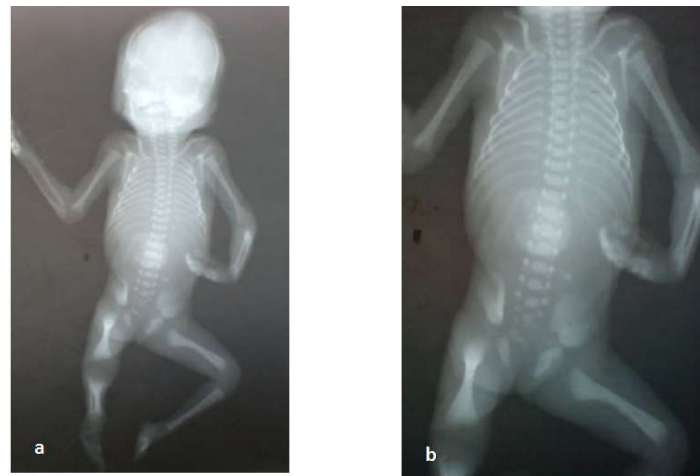The foetus presented dysmorphic features of the face and bilateral cleft lip and palate (fig.1b), low set malformed ears (fig.1c), gastroschisis (fig.1a), bilaterally polydactyly of hands (fig.1d&e) and feet (fig.1f) with clinodactyly of right hand (fig.1d). A radiograph of the still born foetus showing decreased length of forearm bones on the left side (fig.2a) and cubbed left hand (fig.2b)

## DISCUSSION

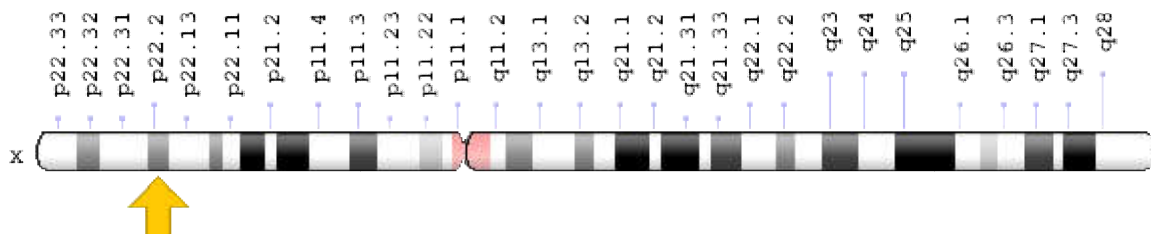
Dysmorphic features affecting the head are described as 'remarkably characteristic' (Toriello H.V 1992) and include facial asymmetry, frontal bossing, hypertelorism, micrognathia, broadened nasal bridge and facial milia. The digital abnormalities, which affect the hands (50–70%) more often than the feet (25%), include syndactyly, brachydactyly, clinodactyly and, more rarely, pre- or post-axial polydactyly. These clinical features overlap with those reported in the other seven oral-facial-digital syndromes (Toriello, 1992). The first oral-facial-digital syndrome was described in 1941 by Mohr, followed by a report by Papillon-Léage and Psaume of another case in 1954. Ironically, these became known as oral-facial-digital syndrome (OFDS) II and I, respectively. Since then, numerous other examples of OFDS have been published (Toriello 2009). Thirteen types have been distinguished based on characteristic clinical manifestations (Gurrieri *et al.*, 2007).



**Fig.1. Showing a. gastroschisis b. bilateral cleft lip and palate c. low set malformed ears d. polydactyly and clinodactyly of right hand e. polydactyly of left hand f. polydactyly in both feet**



**Fig. 2. Showing a. radiograph OFD foetus showing short forearm bones on the left side b. showing clubbed left hand**



**Fig.3.**

OFD1 is characterized by craniofacial anomalies, such as facial skin milia, alar hypoplasia (broadened nasal ridge), and facial asymmetry; oral anomalies include hamartomas, clefts of lip and palate, and dental abnormalities. Consistently, expression of *Ofd1* is detected in the olfactory and respiratory epithelium of the nasal cavities and nasopharynx, in several ectodermally derived structures of the mouth and palate (upper lips, the surface epithelium of the gum region of the mouth, and tooth primordia), and in the endoderm-derived surface epithelium of the tongue and oropharynx.

OFD1 is also characterized by an involvement of the CNS in as many as 40% of the cases with reports of mental retardation, seizures, and other neurological defects (Towfighi *et al.* 1985; Connacher *et al.* 1987). Cytogenetic Location: Xp22.2, which is the short (p) arm of the X chromosome at position 22.2 (fig.3) (Maria I. Ferrante *et al.*). Molecular Location: base pairs 13,734,713 to 13,769,361 on the X chromosome (Homo sapiens Annotation Release 108, GRCh38.p7) (<https://ghr.nlm.nih.gov/gene/OFD1#location> NCBI).

### Other names of this gene are

71-7A, CXorf5, JBTS10, MGC117039, MGC117040, OFD1\_HUMAN, oral-facial-digital syndrome 1, SGBS2 (<https://ghr.nlm.nih.gov/gene/OFD1#location>) In a case report (Rabah *et al.*, 2013), a 2 months old boy, the first in order of birth of non-consanguineous parents, with several typical features of oral-facial-digital syndrome type II (OFDS II) including cleft lip, high arched palate, retromicrognathia, preaxial polysyndactyly of hands and feet, duplication of thumb and hallux. Interestingly, the patient also had mesoaxial polydactyly of the left hand with extra metacarpal bones characteristic of OFDS.

### Conclusion

In the present case external abnormalities of maxillofacial regions, limbs and anterior abdominal wall were observed. For further evaluation genetic analysis should be done to place the case in one of the OFD classification. OFD-1 has X linked dominant (XLD) inheritance whereas the other types of OFDS show autosomal recessive (AR) inheritance.

**Conflict of Interest:** The authors declare that they have no conflict of interest.

### REFERENCES

Connacher, A.A., Forsyth, C.C., Stewart, W.K. 1987. Orofaciodigital syndrome type 1 associated with polycystic kidneys and agenesis of the corpus callosum. *J Med Genet.*, 24:116–122

Gurrieri, F., Franco, B., Toriello, H., Neri, G. 2007. *Oral-facial-digital syndromes: a review and diagnostic guidelines. Am J Med Genet.*; 143A(24):3314–23.)

<https://ghr.nlm.nih.gov/gene/OFD1#location> NCBI

Maria, I. Ferrante, Giovanna Giorgio, Sally A. Feather, Alessandro Bulfone, Victoria Wright, Michela Ghiani, Angelo Selicorni, Linda Gammara, Francesco Scolari, Adrian S. Woolf, Odent Sylvie, Le Marec Bernard, Sue Malcolm, Robin Winter, Andrea Ballabio, and Brunella Franco(2001). Identification of the Gene for Oral-Facial-Digital Type I Syndrome *Am J Hum Genet* . Mar; 68(3): 569–576. Published online 2001 Feb 13.)

Mohr, O.1941. *A hereditary lethal syndrome in man. Avh Norske Videnskad Oslo.* ;14:1–18.

Rabah, M. Shawky, Solaf M. Elsayed, Heba S. Abd-Elkhalek, Shimaa Gad, 2013. Oral-facial-digital syndrome type II: Transitional type between Mohr and Varadi *Egyptian Journal of Medical Human Genetics*, Volume 14, Issue 3, July, Pages 311–315

Toriello, H.V. 1993. *Oral-facial-digital syndromes, 1992. Clin Dysmorph.*, 2:95–105.

Toriello, H.V. 2009. Are the oral-facial-digital syndromes ciliopathies? *Am J Med Genet A*, 149A, pp. 1089–1095

Towfighi, J., Berlin, C.M., Jr., Ladda, R.L., Fraenhoffer, E.E., Lehman, R.A. 1985. Neuropathology of oral-facial-digital syndromes. *Arch Pathol Lab Med.*, 109:642–646

\*\*\*\*\*