



RESEARCH ARTICLE

PREVALENCE OF ANATOMICAL VARIATIONS AND INCIDENTAL PATHOLOGIES IN ANTRUM OF HIGHMORE DETECTED BY CONE BEAM COMPUTED TOMOGRAPHY

¹Dr. Saraswathi Gopal, K., ^{*}²Dr. Supriya Manoharan and ³Dr. Sumathy, C.

¹Professor & Head, ²Post Graduate Student, ³Reader, Department of Oral Medicine and Radiology, Meenakshi Ammal Dental College, Chennai, Tamilnadu, India

ARTICLE INFO

Article History:

Received 16th December, 2016
Received in revised form
14th January, 2017
Accepted 04th February, 2017
Published online 31st March, 2017

Key words:

Cone-beam computed tomography (CBCT),
Maxillary sinus, Anatomical variations,
Incidental pathologies, Sinus septa,
Sinus hypoplasia, Antral polyp,
Mucosal thickening, Sinus opacification
and Mucous retention cyst.

ABSTRACT

Objectives: The aim of the present study was to infer and record the prevalence of anatomical variations and incidental pathologies of maxillary sinus in patients presenting with dental and ENT problems who were subjected to Cone Beam Computed Tomography scans performed for Maxillofacial diagnostic purpose.

Materials and Methods: In this retrospective study we have evaluated 70 CBCT images (140 maxillary sinus bilaterally) from age group ranging between 14-65 years for anatomical variations and maxillary sinus pathologies. 140 CBCT images were acquired using PLANMECA MID PROMAX 3D machine and the images were analysed using Romexis Software.

Results: The anatomical variations like prevalence of septa was found in 17.14% , sinus hypoplasia in 6.42% and pathological findings grouped as mucosal thickening was found in 16.42%, mucosal retention cysts in 7.14%, antral polyps in 9.28% and sinus opacification in 3.57% were observed.

Conclusion: The high occurrence of pathologies in asymptomatic maxillary sinus emphasizes how important it is for the dentists to identify these potential pathologies of maxillary sinus in CBCT images. It is the duty of the dental radiologists to be keen enough to detect these pathologies and refer the patients with such pathologies to the concerned specialists for providing an early diagnosis, better prognosis and a comprehensive health care for the patients.

Copyright©2017, Dr. Saraswathi Gopal et al. This is an open access article distributed under the Creative Commons Attribution License, which permits unrestricted use, distribution, and reproduction in any medium, provided the original work is properly cited.

Citation: Dr. Saraswathi Gopal, K., Dr. Supriya Manoharan and Dr. Sumathy, C. 2017. "Prevalence of anatomical variations and incidental pathologies in Antrum of Highmore detected by cone beam computed tomography", *International Journal of Current Research*, 9, (03), 48029-48034.

INTRODUCTION

Historically, paranasal sinuses were first identified by ancient Egyptians followed later by Greek physicians. The Latin word "sinus" stands for a curve, hollow in land, or a bay or gulf. It can also mean the innermost part of something deep. Humans possess four paired paranasal sinuses, which are named according to the bones within which the sinuses are present. The maxillary sinus is the largest of the paranasal sinuses, maxillary sinus anatomy was first described by Nathaniel Highmore's and hence maxillary sinus is also termed as Antrum of Highmore. The pyramid-shaped maxillary sinus (or Antrum of Highmore) present in the body of maxilla drains into the middle meatus of the nose. They reduce skull weight, produce mucous, and affect the tone quality of a person's voice. Maxillary sinus can be visualized using panoramic radiograph and paranasal sinus views. Other imaging modalities like computed tomography (CT) are employed, Though CT is considered as the "gold standard" technique for the examination of the maxillary sinuses, but

Though CT is considered as the "gold standard" technique for possess certain limitations, which includes their high cost and high radiation exposure whereas latest imaging modalities (CBCT) are used these days to detect the anatomical variations and wide array of pathologies of Antrum of Highmore or maxillary sinus as these techniques addresses the limitations of CT. CBCT helps in identifying the anatomical variations like prevalence of sinus hypoplasia and prevalence of sinus septa. Prevalence of pathological variations like sinus opacification can also provide valuable information on inflammatory conditions of paranasal sinuses like mucosal thickenings, antral polyps, mucous retention cysts, and inflammatory conditions of frontal sinuses can be evaluated without additional exposure (Anitha Raghunathan et al., 2016).

MATERIALS AND METHODS

This retrospective study was carried out in the Department of Oral Medicine and Radiology, Meenakshi Ammal Dental College and Hospital, Chennai, India. The CBCT indicated for these patients were for diagnosis, treatment planning and implant assessment from various departments like Orthodontic, Endodontics, ENT, Oral and Maxillofacial

*Corresponding author: Dr. Supriya Manoharan,
Post Graduate Student, Department of Oral Medicine and Radiology,
Meenakshi Ammal Dental College, Maduravoyal, Chennai.

Surgery. CBCT images were acquired using PLANMECA MID PROMAX 3D machine and the images were analysed using Romexis Software. The archived CBCT images of 70 patients (140 maxillary sinus consecutive CBCT) were retrieved and evaluated. The age group of patients whose images were evaluated ranged between 14-65 years out of which 46 images were of males and 24 images were of female patients, which were sub divided into five groups according to the age as group I - (14 to 20 years), group II - (20 to 30 years), group III - (30 to 40years), group IV- (40 to 50) and group V- (50 to 65 years).

Inclusion criteria

This present study included CBCT images in which Maxillary sinuses of both sides were completely visible.

Exclusion criteria

The exclusion criteria of the study comprised of images with metallic artefacts, low resolution quality which hampered sinus visualization and patient's images below the age of 14 years who lacked complete sinus development.

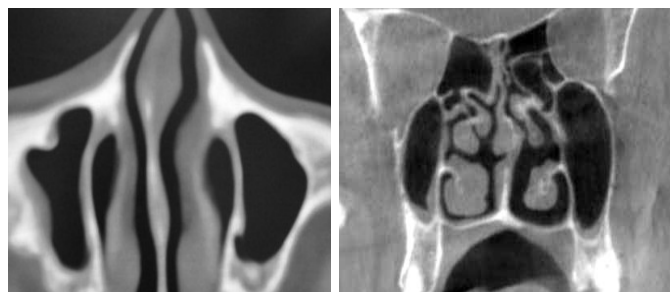Statistical analysis

The statistical analysis was done with SPSS version 16 software.

RESULTS

CBCT images of 70 patients (140 maxillary sinus consecutive CBCT) were retrieved and evaluated from which the incidence of anatomical variations and incidental sinus pathologies of the maxillary sinus varied between 23.56% and 36.42% respectively. The basic statistical analysis was performed. The anatomical variations (Fig.1) were grouped as prevalence of sinus septa and sinus hypoplasia TABLE -1 AND GRAPH -1. The anatomical variations were evident in 23.56% out of which septated sinus was prevalent in 17.14% and sinus hypoplasia was evident in 6.42% of the patients and their prevalence among different age groups were tabulated in TABLE- 2 under five categories and our study found that higher percentage of anatomical variations which was evident in patients who were in fifth and sixth decade followed by patients who were in their second decade of their lives and their percentages being 40, 39.13 and 33.3 respectively. The prevalence of anatomical variations among gender were tabulated in TABLE-3 AND GRAPH - 3 which indicated that sinus septa was found in 75% males and 25% females and sinus hypoplasia in 44.44% of males and 55.55% in females patients. The incidental sinus pathologies (Fig-2) were categorised as mucosal thickening, mucous retention cyst, sinus opacification and antral polyp. TABLE 4 AND GRAPH 4. Pathological findings of maxillary sinus grouped as Mucosal Thickening was found in 16.42%, Mucosal retention cysts in 7.14 %, Antral polyps in 9.28% and Sinus opacification in 3.57% were observed in our study. Their distribution among the different age groups in TABLE 5 AND GRAPH 5 indicated the pathologies were evident in patients in the age group between 50 to 65 years with a percentage of 60, followed by patients in the fifth decade and second decade almost sharing an equal prevalence of about 58.33 and 57.89% respectively. Patients who were in their third decade had a prevalence of 45.45% and patients in their second decade had a

least prevalence of 30.43% among the various age groups. The prevalence of incidental sinus pathologies among gender were tabulated in TABLE-6 AND GRAPH-6 which implied that male predominance were observed in our study. Mucosal thickening was evident in 69.56% of males and 30.43% of females. Mucosal retention cysts were identified in 80% of males and 20% of females. Antral polyps were evident in 60% of males and 40% of females. Sinus opacification was prevalent in 69.23% of males and 30.76% of female patients.

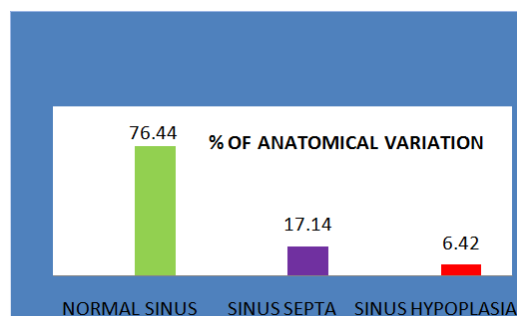


Sinus septa (left and right sides) Sinus hypoplasia (right side)

Figure 1. Anatomical variations

Table 1.

Percentage of anatomical variation	
Normal sinus	76.44 %
Sinus septa	17.14 %
Sinus hypoplasia	6.42 %

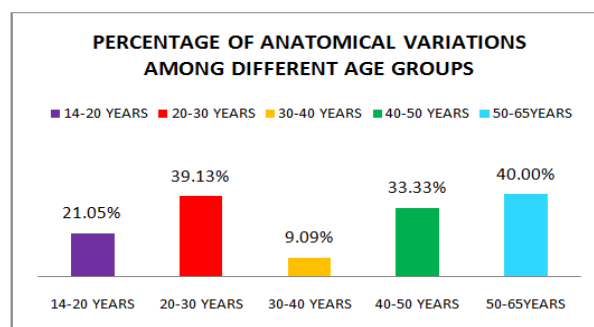


Graph 1.

Prevalence of Anatomical variations among the different age groups

Table 2.

Age group	14-20 Years	20-30 Years	30-40 Years	40-50 Years	50-65 Years
Total No of patients	19	23	11	12	5
Count	4	9	1	4	2
Percentage	21.05%	39.13%	9.09%	33.33%	40.00%

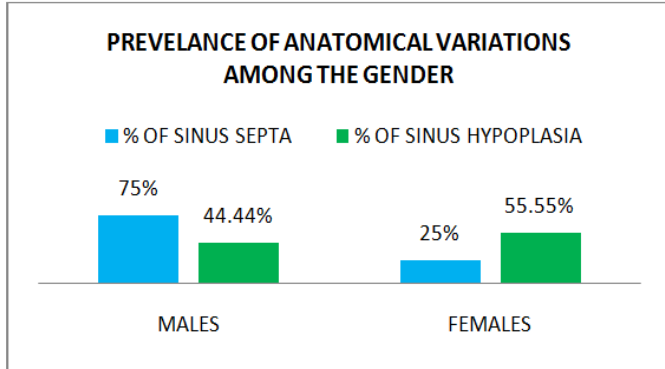


Graph 2.

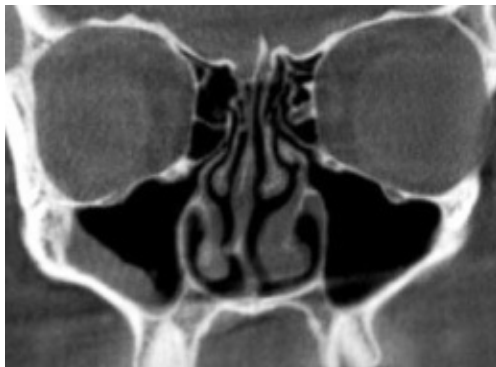Prevalence of Anatomical variations among the gender

Table 3.

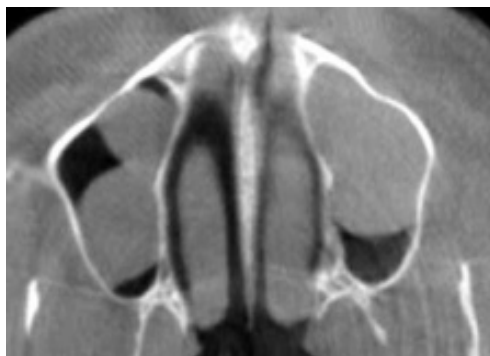
Criteria	Males	Females
% Of sinus septa	75	25
% Of sinus hypoplasia	44.44	55.55



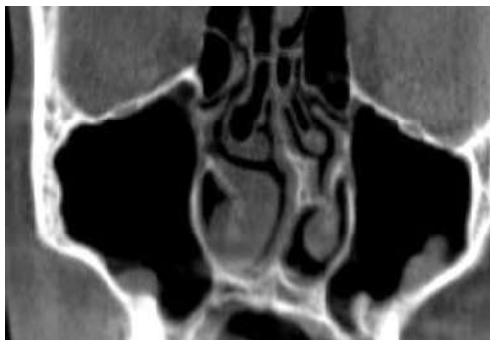
Graph 3.



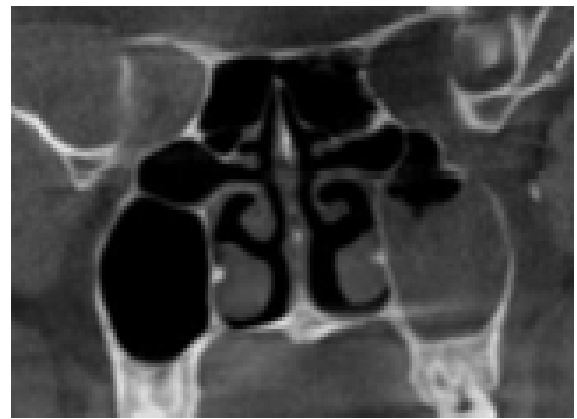
Mucosal thickening right side



Mucous retention cyst right and left sides



Antra polyp right and left sides



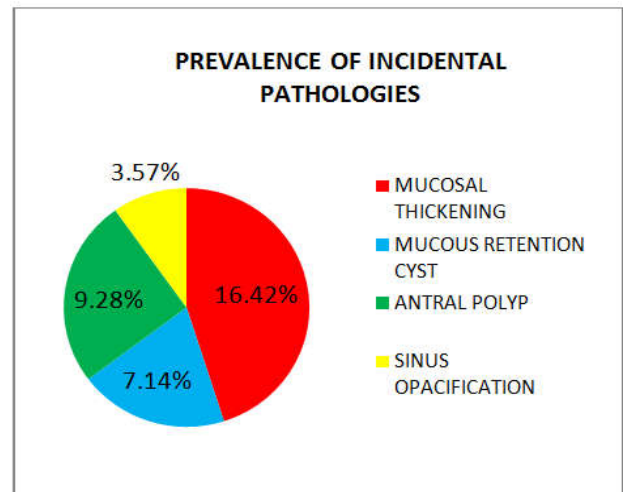
Sinus opacification left side

Figure 2. Incidental pathologies

Percentage of incidental pathologies

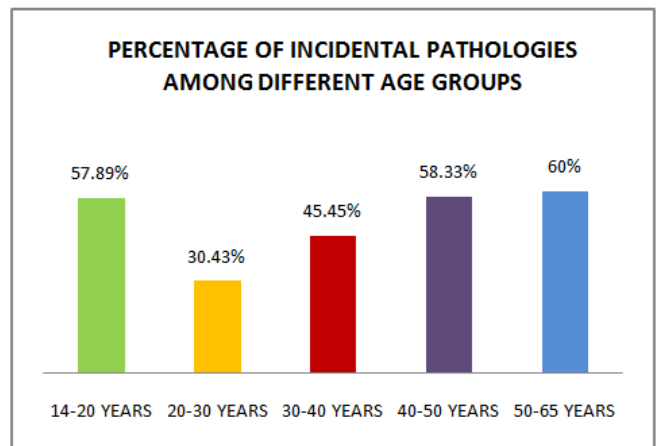
Table 4.

Percentage of incidental pathologies	
Mucosal thickening	16.42%
Mucous retention cyst	7.14%
Antral polyp	9.28%
Sinus opacification	3.57%



Graph 4.

Prevalence of Incidental Pathologies among the different age groups



Graph 5.

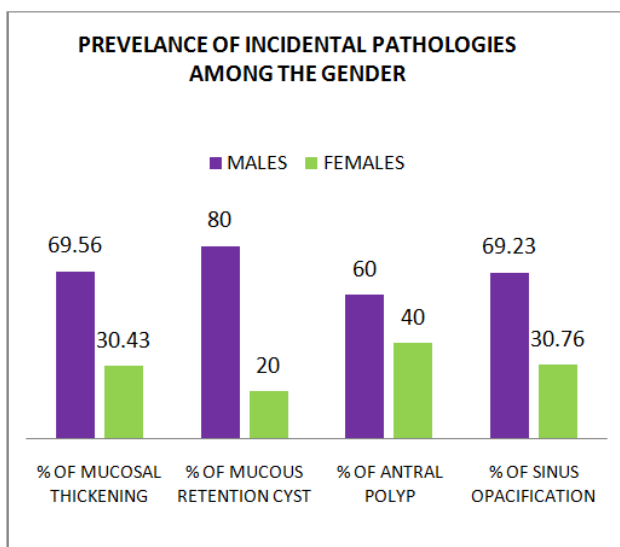
Table 5.

Age group	14-20 Years	20-30 Years	30-40 Years	40-50 Years	50-65 Years
Total					
No of patients	19	23	11	12	5
Count	11	7	5	7	3
Percentage	57.89%	30.43%	45.45%	58.33%	60%

Prevalence of incidental pathologies among the gender

Table 6.

Criteria	Males	Females
% Of mucosal thickening	69.56	30.43
% Of mucous retention cyst	80	20
% Of antral polyp	60	40
% Of sinus opacification	69.23	30.76



Graph 6

DISCUSSION

The maxillary sinuses are the largest of the air filled spaces surrounding the nose. They are paired structures located in the body of maxilla, they are mirror images of one another and are pyramidal in shape. It is the first paranasal air sinus to develop. It is also called as "The Antrum of Highmore" The multiplanar imaging slices acquired by CBCT provide an opportunity for radiologists to identify the anatomical variations and lesions of the maxillary sinus. Over the last decade, CBCT was available for maxillofacial radiographic imaging in western countries, but it is explored in our country only during the recent decade and numerous software systems are in use now. No other imaging modality in dentistry has made a great impact on dental procedures in a short span of time as that of CBCT. The field of maxillary sinus can be appreciated when the CT/CBCT is indicated for various reasons such as assessment of dental implant site, impacted supernumerary teeth, inflammatory pathologies involving periapical areas, endodontic lesions, sinus augmentation and pre orthodontic evaluations. Hence, the incidental findings are frequently viewed in the area of the maxillary antrum by the maxillofacial radiologists. The increase in use of CBCT by dentists, maxillofacial surgeons and few medical specialities opens up an opportunity for assessment of the prevalence of anatomical variations and

incidental pathologies of maxillary sinus. These can be either incidental or of direct significance for further treatment planning (Anitha Raghunathan *et al.*, 2016).

Maxillary sinus septa was relatively a common finding but were typically considered to be asymptomatic conditions. They were classified as either primary occurring after eruption of the tooth, or secondary occurring after edentulous state. The septa may be present in an obstructive relationship with that of the osteomeatal unit posing a derangement in the draining of the sinus leading to chronic rhino sinusitis. The presence of septa relates to the risks and complications during preimplant surgeries like sinus lift and LeForte's osteotomy as neglecting the information about the presence of septa may end up in sinus perforation. According to a study by *Corbin D Sullivan et al.* (2012), patients of western origin had sinus septa which ranged from 21.6 to 66.7 percentage as this study has included patients under 14 years of age, which is slightly more when compared with our study conducted in Indian population which accounted for only 17.14 percentage, as our study excluded patients who lacked complete sinus development. *Krennmair et al.* (1999) found that panoramic radiograph can lead to false diagnosis regarding the positive or negative identification of septa. Their study documented the prevalence in 21.3% of cases, hence suggested CT to be the preferred modality for scanning maxillary sinus accurately. *González-Santana et al.* (2007) evaluated 60 maxillary sinuses of 30 patients using panoramic radiographs and helical CT scan. The authors founded that 25% of patients had sinus septa which is slightly higher than our study. According to a study by *Marcelo lupion poleti et al.* (2014) reported that CBCT was important for the confirmation of the presence of maxillary sinus septum. Sinus hypoplasia is condition where one side of the maxillary sinus appears to be of a smaller size when compared with the contra lateral side. Hypoplasia of maxillary sinus can occur due to arrest of its development as in the case of congenital first arch syndrome or may be secondarily due to infection, injuries, irradiation, and developmental anomalies. Other acquired causes of hypoplasia may include trauma leading to deformity due to fracture or surgery in the sinus region, thalassemia, cretinism, Wegener's granuloma and neoplasms that cause osteitis. The incidence of maxillary sinus hypoplasia ranged between 1.5 to 10% as per, the earlier OPG and Computed Tomographic studies done at different period of time by (*Karmody et al.*, 1977; *Bassiouny et al.*, 1982; *Bolger et al.*, 1990; *Khanobthamchai et al.*, 1991; *Sirikci et al.*, 2000). *Thiagarajan et al.* (2012) which is in accordance with our study that elicited a prevalence of 6.42%. *Anitha Raghunathan et al.* (2016) in her CBCT study found that sinus hypoplasia was evident in 9.6% which was slightly higher than our study. Several studies have reported a great variability in the prevalence of abnormalities of maxillary sinuses when multiplanar images were used. CT scanning studies found sinus abnormalities in 30% of the cases and a study by *Christopher et al.* (2012) revealed CBCT studies reported a prevalence ranging from 22.6% to 56.3%. In our study we detected anatomical variations in 23.56% which is in accordance with the earlier study.

Pathological findings of maxillary sinus grouped as Mucosal Thickening was found in 16.42%, Mucosal retention cysts in 7.14%, antral polyps in 9.28% and sinus opacification in 3.57% were observed in our study. *Havas et al.*, (1988) and *Cooke et al.* (1991) found a male predominance in the prevalence of incidental pathologies and attributed smoking

habit as the reason behind it in their study. Song Ren et al. (2005) detected mucosal thickening in 48.9% of the patients which appears to be higher when compared with our study. As per a MRI based study done by Tarp et al. in (2000) stated that mucosal thickening was observed more in males than females which appears to be in accordance with our study done using CBCT. Anitha Raghunathan et al. (2016) in her CBCT study reported mucosal thickening in 37.5% of the patients.

Graco et al., (2010) concluded that age is a significant predictor of mucosal thickening, in a way subjects aged 41-60 years showed 40.1% higher occurrence of mucosal thickening than subjects under 12-18 years in Italian population whereas our study revealed mucosal thickening in 16.47% of the cases.

Mamta et al. (2010), and Gina et al. (2016) found a higher frequency of pathologic findings in males, which was in concordance with our study.

Mucous retention cyst results from the accumulation of mucous within the soft tissue that lines the sinus as a result of obstruction of the duct or gland within the epithelial layer which appears as a dome shaped radio opacity. The reported incidence is 13% in earlier CT and MRI studies conducted by Hoang, (2000). Anitha Raghunathan et al. (2016) in her CBCT study found only 4% whereas in our study the prevalence of mucous retention cyst was very much higher than the earlier studies which was recorded to be 16.42%. Antral polyps are inflammatory conditions of paranasal sinus mucosa that leads to a typical polypoid appearance. Cystic fibrosis and Kartagener's syndrome were found to predispose the polyp formation. Chandramani B. More et al., (2016) concluded that 93.10% of participants had bilateral polyp and 6.90% had unilateral polyp in their retrospective CT study which included images which had only mucosal polyp. Anitha Raghunathan et al. (2016) reported only 4% of the prevalence of antral polyps whereas our study had a higher incidence of 9.28% of antral polyps.

Sinus opacification which is one of the symptoms of acute sinusitis can be caused by an infection, structural variations in the nasal cavity, allergic responses or nasociliary malfunction. It was found to be one of the features of Silent sinus syndrome. Our study revealed sinus opacification in 3.57% of the cases which is slightly higher than the results of the study conducted by Ilze Doble et al. (2016) which had only 2.9% of opacified sinus. On comparing the pathological findings and anatomical variations among the male and female patients the p value found was significant (0.5) which implies that male patients had a higher prevalence of anatomical variations and incidental pathologies. Discrepancies in abnormality rates may be due to several factors, such as dissimilarities in the sampling criteria, variations in image interpretation and diagnostic criteria and influence of the climate among geographical areas.

Conclusion

The knowledge about the anatomical variations like sinus septa in the maxillary sinus is of great importance in deciding whether it is safe or not to do preimplant procedures like sinus lift. The high occurrence of the pathologies in Maxillary sinus emphasizes how important it is for the dentomaxillofacial radiologist to undertake a comprehensive interpretation of the CBCT images. All though oral radiologists and dentists were not expected to treat conditions outside the professional

knowledge and expertise, they are not exempted from the moral responsibility of identifying these pathologies of maxillary sinus in the CBCT scans. Hence the dental radiologists should be keen enough to detect these pathologies and refer the patients with such pathologies to the concerned specialists for providing an early treatment, better prognosis and a comprehensive health care for the patients.

REFERENCES

- Anitha Raghunathan, Saraswathi Gopal S, Sumathy.C. 2016. Occurrence of abnormalities and anatomical variations in maxillary sinus detected by CBCT. *International Journal of Oral Health and Medical Research*, Vol. 2, Issue 6 :ISSN2395-7387
- Bassiouny A, Nexlands WC, Hussein A, Yehia Z. 1982. Maxillary sinus hypoplasia and superior orbital fissure asymmetry. *Laryngoscope*, 92: 441-448.
- Bolger WE, Woodruff WW, Morehead J, Parsons D. 1990. Maxillary sinus hypoplasia: Classification and description of associated uncinat process hypoplasia. *Otolaryngol Head Neck Surg.*, 103: 759-765.
- Britta Tarp, Bente Fiirgaard, Thorkil Christense², Jens Jørgen Jensen², Finn Trunk Black, 2000. The prevalence and significance of incidental paranasal sinus abnormalities on MRI. *Articles in Rhinology.*, 38, 33–38, 2000
- Chandramani B. More, Nairita Saha, 2016. Maxillary Sinus Polyp: An Analysis on Computed Tomography *International Journal of Maxillofacial Imaging*, 2(2):46-50 48.
- Christopher G.T. and Manfred Spanger, 2012. Incidental maxillary sinus findings in patients referred for head and neck CT angiography. *Singapore Dental Journal*, Vol. 33, issue 1 pg 1-4.
- Cooke LD. and Hadley DM 1991. MRI of the paranasal sinuses: Incidental abnormalities and their relationship to symptoms. *J Laryngol Otol.*, 105:278-281.
- Gina D.Rouque Torres, Laura Ricardina Ramirez-Sotelo, Sergio Lins de Azevedo vas, Solange Maria de Almeida de Boscolo, Frab Norberto Boscolo, 2016. Association between maxillary sinus pathologies and healthy teeth. *Brazilian Journal of Otorhinolaryngology*, Vol 82, Issue 133-38.
- González-Santana.M, Peñarrocha-Diago, J. Guarinos-Carbó, and M. Sorní-Bröker, 2007. "A study of the septa in the maxillary sinuses and the sub antral alveolar processes in 30 patients," *The Journal of Oral Implantology*, vol. 33, no. 6, pp.340–343, 2007.
- Gracco A, Tracey S, Baciliero U, 2010. Miniscrew insertion and the maxillary sinus: an endoscopic evaluation. *Journal of Clinical Orthodontia*, 44:439-443.
- Havas TE, Motbey JA, Gullane PJ. 1988. Prevalence of incidental abnormalities on computed tomographic scans of the paranasal sinuses. *Arch Otolaryngol Head Neck Surg.*, 114:856-859.
- Izido Bebe, Ligija Kise, Peteris Apse, Gints Kragis, Andris Bigestans, 2013. Radiographic assessment of findings in the maxillary sinus using cone-beam computed tomography. *Stomatologija, Baltic Dental and Maxillofacial Journal*, Vol.15, Issue 4;119-122.
- Jafari-Pozve N, Sheikhi M, Ataie-Khorasgani M, Jafari-Pozve S. 2014. Aplasia and hypoplasia of the maxillary sinus: A case series. *Dental Research Journal*, 11(5):615-617.

- Karmody CS, Carter B, Vincent ME. 1977. Developmental anomalies of the maxillary sinus. *Trans Am Acad Ophthalmol Otolaryngol.*, 84: 723-728. 7.
- Khanobthamchai K, Shankar L, Hawke M, Bingham B. 1991. Ethmoid maxillary sinus and hypoplasia of maxillary sinus. *J Otolaryngol.*, 20: 425-427.
- Kihara.E.N, Ochola.C, Chindia. M.L. and Parker.M.E. 2015. Incidental Pathology and Anatomical Variations in Oral and Maxillofacial Cone Beam Computed Tomographic Scans. *British Journal of Medicine & Medical Research*, vol 5, Issue 11;1349-1360.
- Krennmair, G., C. W. Ulm, H. Lugmayr, and P. Solar, "The incidence, location, and height of maxillary sinus septa in the edentulous and dentate maxilla," *Journal of Oral and Maxillofacial Surgery*, vol. 57, no. 6, pp. 667-672, 1999.
- Mamta Raghav, Freney R. Karjodkar, Subodh Sontakke and Kaustubh Sansare, 2014. Prevalence of Incidental maxillary sinus pathologies in dental patients on cone-beam computed tomographic images, *Contemporary Clinical Dentistry*, Vol 5, issue 3;361-365.
- Marcelo Lupion Poleti, 1 Luciana Maria Paes da Silva Ramos Fernandes, 2 Christiano Oliveira-Santos, 3 Ana Lúcia Alvares Capelozza, 2 Luiz Eduardo Montenegro Chinellato, 2 and Izabel Regina Fischer Rubira-Bullen, 2014. Anatomical Variation of the Maxillary Sinus in Cone Beam Computed Tomography *Case Reports in Dentistry*, Volume 2014, Article ID 707261, 3 pages.
- Maxillary Sinus Septation as a Cause of Chronic Rhinosinusitis Corbin D. Sullivan MD1, Stephen F. Conley MD1,2, Steven R. Sewall MD3 Department of Otolaryngology and Communication Sciences (1), Pediatric Otolaryngology (2), and Oral and Maxillofacial Surgery (3); Medical College of Wisconsin and Children's Hospital of Wisconsin, Milwaukee, Wisconsin.
- Rashid Al-Abri, Deepa Bhargava, Wameeth Al-Bassam, Yahya Al Badaai and Sukhpal Sawhey, 2014. Clinically Significant Anatomical Variants of the Paranasal Sinuses. *Oman Medical Journal*, Vol 29, Issue 2;110-113
- Ritter L, Lutz J, Neugebauer J, Dreiseidler T, Zinser MJ, et al. 2011. Prevalence of pathologic findings in maxillary sinus in cone beam computerized tomography. *Oral Surgery Oral Med Oral Pathol Oral Radiol Endod.*, 111:634-640
- Sirikci A, Bayazit Y, Gümüşburun E, Bayram M, Kanlikama M. 2000. A new approach to the classification of maxillary sinus hypoplasia with relevant clinical implications. *Surg Radiol Anat.*, 22: 243-247.
- Song Ren, Haijiao Zhao Jingbo Liu Qingxuan Wan Yaping Pan, 2015. Significance of maxillary sinus mucosal thickening in patients with periodontal disease, *International Dental Journal*, December 2015 Volume 65, Issue 6 Pages 283-337.
- Thiagarajan B, Narashiman S. Hypoplasia of all paranasal sinuses: A case series and Literature review. *Otolaryngology*. 2012;2.
- Trauma J.K. Hoang E.C. Smith D.P. Barboriak. E REPORT Ruptured Maxillary Retention Cyst: Cause of Unilateral Rhinorrhea after trauma.
