



## CASE STUDY

### MAXILLARY FIRST MOLAR WITH SIX CANALS HAVING DOUBLE ROOT CANAL SYSTEM IN EACH ROOT

<sup>1</sup>Dr. Ramesh Chandra, <sup>\*</sup><sup>1</sup>Dr. Poonam Singh and <sup>2</sup>Dr. Braj Bhushan Mall

<sup>1</sup>Department of Conservative Dentistry and Endodontics, Career Post Graduate Institute of Dental Sciences and Hospital, Lucknow, India

<sup>2</sup>Assistant Professor, Department of Oral and Maxillofacial Surgery, Dental college RIMS Imphal, Manipur, India

#### ARTICLE INFO

##### Article History:

Received 24<sup>th</sup> January, 2017

Received in revised form

10<sup>th</sup> February, 2017

Accepted 27<sup>th</sup> March, 2017

Published online 30<sup>th</sup> April, 2017

##### Key words:

Vertucci type IV, Weine type III,  
Silver cone.

Copyright©2017, Dr. Ramesh Chandra et al. This is an open access article distributed under the Creative Commons Attribution License, which permits unrestricted use, distribution, and reproduction in any medium, provided the original work is properly cited.

Citation: Dr. Ramesh Chandra Professor, Dr. Poonam Singh and Dr. Braj Bhushan Mall, 2017. "Maxillary first molar with six canals having double root canal system in each root", *International Journal of Current Research*, 9, (04), 49368-49370.

#### ABSTRACT

The anatomic complexities and variations are constant challenges for successful endodontic therapy. A unique morphology with double canal systems in each root was identified. The morphology was characterized by a single palatal root with two canals joining in the apical third, single mesiobuccal root with two mesiobuccal canals and single distobuccal root with two distobuccal canals with two separate orifice and two separate foramina. The present case report discusses the endodontic management of an unusual case of a maxillary first molar with three roots and six canals.

## INTRODUCTION

There are a number of anomalies in the root canal system means something that deviates from what is standard, normal or expected. Root canal system disinfection is of paramount importance in endodontic treatment. To ensure the long-term success of root canal treatment, it is essential to access, clean, and three dimensional filling of entire root canal system (Peters, 2004). Efforts are made during instrumentation to remove infected pulp tissues and debris from the root canal system spaces. However, achieving a sterile environment is impossible because of presence of lateral canals, ramifications, and intercanal communication. The maxillary first molars commonly presents 1 Mesiobuccal Canal (MBC) in mesiobuccal root and 1 Distobuccal Canal (DBC) in distobuccal root and one palatal canal (PC) in palatal root. However, other anatomical configurations have also been reported in the literature. Root and root canal morphological variations in multi-rooted teeth are a treatment challenge for accurate diagnosis and successful endodontic treatment (Al-Qudah and Awawdeh, 2006). Complete knowledge of the root canal anatomy is obligatory because non-treatment of any of the unexplored canals can lead to treatment failure. For the past 50 years, silver cones have been used to fill the root canals.

A silver cone is stiffer than gutta-percha and can be easily inserted into a fine tortuous canal. They are always used in conjunction with a root canal cement. They are decidedly inert, dimensionally stable, and, except in the rarest instances of manufacturing defect, they cannot be resorbed. Their semi-rigidity permits them to be wedged forcibly toward the critical root apex, where they are expected to provide a hermetic seal for the root canal. As in the case of gutta percha, silver cones are available in a variety of widths and in standardized sizes which are intended to conform to the shapes of standardized reamers and files. Ideally, the silver cone should pass loosely through the coronal and middle third of a root canal and bind in the apical portion only. The shape and rigidity of silver cones make this possible in most instances. Silver cones were sometimes recommended for use especially in extremely narrow and curved canals. Nothing could be more incorrect unless the canals were first shaped and enlarged considerably. The #3 silver cone is the minimum sized one that can possibly seal an apex. A #2 silver cone may be threaded or teased into a narrow, underprepared root canal, but it defies logic to expect such a slender wire introduced at the coronal end of the canal to offer a frictional seal at the apical foramen (Filling Root Canals in Three Dimensions *Herbert Schilder*, 2006).

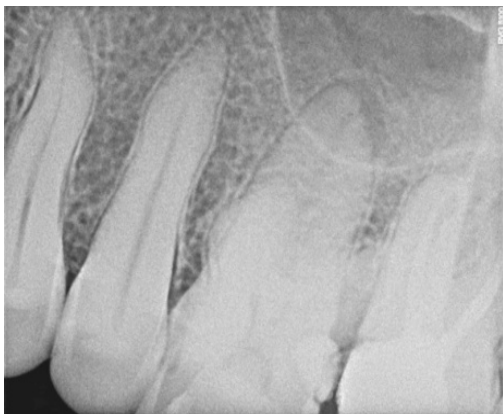#### Case report

A 20-year-old male patient was referred to the Department of Conservative Dentistry and Endodontics, Career Post Graduate

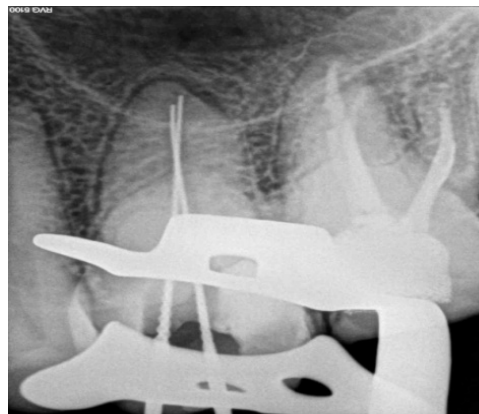
\*Corresponding author: Dr. Poonam Singh, Post graduate student 3<sup>rd</sup> year Department of Conservative Dentistry and Endodontics, Career Post Graduate Institute of Dental Sciences and Hospital, Lucknow, India.

Institute of Dental Sciences & Hospital, Lucknow with a chief complaint of pain in left upper back region of jaw 2 months back. Patient tooth was asymptomatic, two months back he notice a mild pain which was relieved on taking analgesic. Intra oral examination showed grossly decayed tooth (36). IOPA was taken (Fig.a) IOPA revealed radiolucency seen in the coronal region of 36, and approaching towards the pulp chamber. According to clinical and radiographic findings final diagnosis is chronic irreversible pulpitis. Anesthesia achieved using inferior alveolar nerve block by 2 % lignocaine. Isolation was done using Rubber dam. Endodontic access cavity preparation was done under water coolant using Endoaccess Bur (Dentsply Maillefer, Ballaigues, Switzerland) and refined using EndoZ bur (Dentsply Maillefer, Ballaigues, Switzerland).

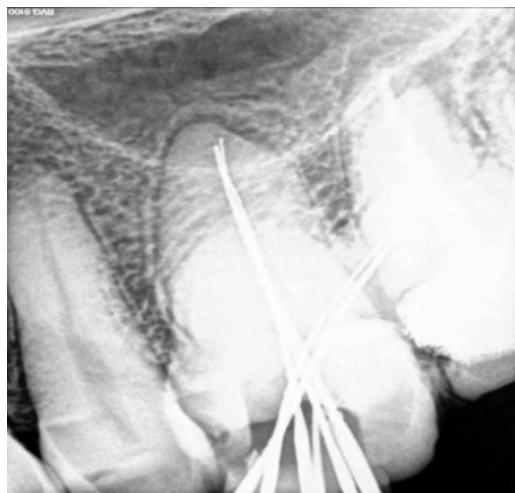
All the orifices were explored using DG-16 endodontic explorer. A ISO size # 10-k file placed into canals to check the patency. The working length of canals was determined by using Radiovisiography. The root canal preparation was done by using stainless steel (SS) 21 mm K-files (Dentsply/ Maillefer, Ballaigues, Switzerland) in a step-back manner through size # 30 by quarter-turn-pull technique. Glyde FILE PREP (10 % carbamide peroxide and 15% EDTA gel) was used for lubrication during instrumentation with each file size and canals were irrigated using 27 gauge needle with 5% sodium hypochlorite followed by normal saline after every instrument used. Once the tooth was asymptomatic master cone radiograph was taken (Fig.e) showing all the six canals. Second mesiobuccal canal (MB2) was obturated with silver cone and



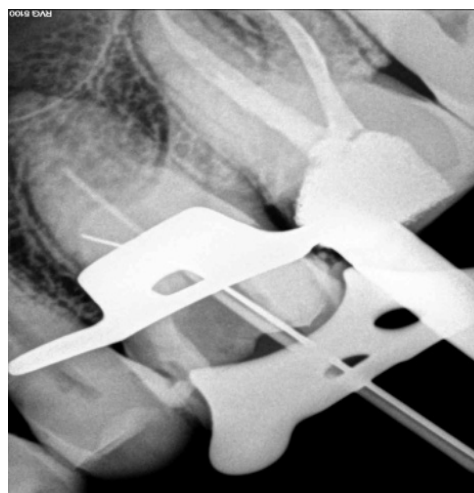**Fig. a. Preoperative radiograph**



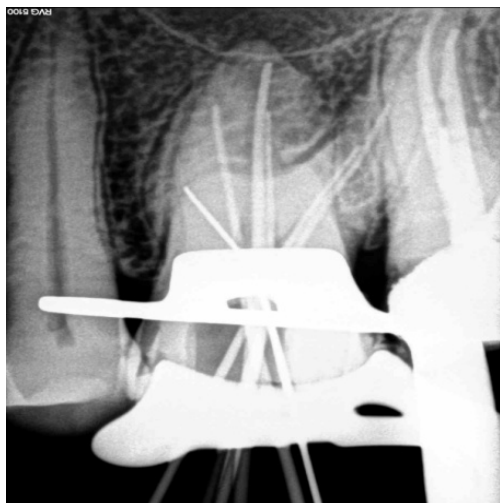**Fig. b. Two canals in palatal root**



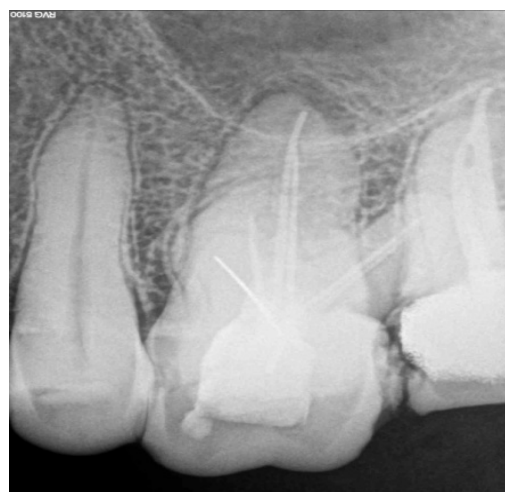**Fig. c. Two canals in distobuccal root**



**Fig. d. Two canals in mesiobuccal root**



**Fig. e. Master Cone radiograph**



**Fig. f. Obturation showing all the six canals**

rest all five canals with gutta-percha and endomethasone sealer (Fig.f). The access cavity was sealed with restorative material and the patient was recalled for permanent restoration.

## DISCUSSION

The presence of a second canal in the MB root (MB2) is reported to be between 18% and 95% (Bauman *et al.*, 2011). This wide range is due to the designs and methods used in these studies (Peeters *et al.*, 2011) and could also be associated with ethnic differences, gender and age of the study populations (Cleghorn *et al.*, 2006). Although the occurrence of a second canal in the distobuccal and palatal roots is infrequent, it is important for clinicians to be aware of all possible anatomic variations for the success of the root canal therapy. The presence of a double canal system in either the distobuccal or palatal root in maxillary first molars was documented in several case reports. Bond *et al.* and Harris were present molars with two palatal canals with separate foramina (Harris, 1980). A case with a bifurcated canal system in the palatal root was reported by Cecic *et al.* (1982). A double canal system in the distobuccal roots was reported by Martinez-Berna and Ruiz-Badanelli and Hulsmann (Hulsmann, 1997; Martinez-Berna and Ruiz-Badanelli, 1983; Barbizam *et al.*, 2004). In present case report In Fig. b intraoral periapical radiograph revealed two separate canals in a single palatal root which join in the apical third (Vertucci type II), (Weine type II). In Fig. c intraoral periapical radiograph revealed two separate and distinct canals extend from the pulp chamber to the apex in a single mesiobuccal root (Vertucci type IV), (Weine type III). In Fig.d intraoral periapical radiograph revealed two separate and distinct canals extend from the pulp chamber to the apex in a single distobuccal root (Vertucci type IV), (Weine type III).

## Conclusion

A common failure in endodontic treatment of the permanent maxillary first molars is likely to be caused by an inability to locate, clean, and obturate the additional canals. Excellent knowledge, understanding and appreciation for root canal system anatomy influence predictably successful treatment outcome. A practitioner should always have doubt in his/her mind regarding presence of extra canal in tooth. With such knowledge and doubts in mind one can help tooth to move on its normal functioning for life time.

## REFERENCES

- Al-Qudah AA. and Awawdeh, LA. 2006. Root canal morphology of mandibular incisors in a Jordanian population. *Int Endod J.*, 39:873-77.
- Barbizam JV, Ribeiro RG, Tanomaru Filho M. 2004. Unusual anatomy of permanent maxillary molars. *J Endod.*, 30:668-71.
- Bauman, R.; Scarfe, W.; Clark, S.; Morelli, J.; Scheetz, J. and Farman, A. 2011. Ex vivo detection of mesiobuccal canals in maxillary molars using CBCT at four different isotropic voxel dimensions. *Int. Endod. J.*, 44(8):752- 8.
- Cecic P, Hartwell G, Bellizzi R. 1982. The multiple root canal system in the maxillary first molar: A case report. *J Endod.*, 8:113-5.
- Christie WH, Peikoff MD, Fogel HM. 1991. Maxillary molars with two palatal roots: a retrospective clinical study. *J Endod.*, 17:80-4.
- Cleghorn, B. M.; Christie, W. H. and Dong, C. C. 2006. Root and root canal morphology of the human permanent maxillary first molar: a literature review. *J. Endod.*, 32(9):813-21.
- Filling Root Canals in Three Dimensions *Herbert Schilder, D.D.S. JOE*, Volume 32, Number 4, April 2006
- Harris WE. 1980. Unusual root canal anatomy in a maxillary molar. *J Endod.*, 6:573-5.
- Hulsmann M. 1997. A maxillary first molar with two distobuccal root canals. *J Endod.*, 23:707-8.
- Martinez-Berna A, Ruiz-Badanelli P. 1983. Maxillary first molars with six canals. *J Endod.*, 9:375-81.
- Peeters, H. H.; Suardita, K. and Setijanto, D. 2011. Prevalence of a second canal in the mesiobuccal root of permanent maxillary first molars from an Indonesian population. *J. Oral Sci.*, 53(4):489-94.
- Peters OA. 2004. Current challenges and concepts in the preparation of root canal systems: a review. *J Endod.*, 30: 559-67.

\*\*\*\*\*