



## CASE STUDY

### AN UNUSUAL PRESENTATION OF PLEOMORPHIC ADENOMA OF LACRIMAL GLAND A RARE ENTITY AND REVIEW OF LITERATURE

<sup>\*</sup><sup>1</sup>Raj, A., <sup>1</sup>Bahadur, H. and <sup>2</sup>Shirazi, N.

<sup>1</sup>Department of Ophthalmology, Himalayan Institute of Medical Sciences, Swami Rama Himalayan University, Jolly Grant, Dehradun

<sup>2</sup>Department of Pathology, Himalayan Institute of Medical Sciences, Swami Rama Himalayan University, Jolly Grant, Dehradun

#### ARTICLE INFO

##### Article History:

Received 18<sup>th</sup> January, 2017

Received in revised form

14<sup>th</sup> February, 2017

Accepted 21<sup>st</sup> March, 2017

Published online 30<sup>th</sup> April, 2017

#### ABSTRACT

Pleomorphic adenoma of the lacrimal gland (PALG) is a rare benign mixed tumor of the lacrimal gland. We are presenting a fifty nine years old male with painless swelling of left eye lid and a palpable mass on superolateral aspect of lid. On computed tomography CT scan of orbit that mass was indenting the globe with invasion of sheath of lateral rectus muscle. On surgical excision it was proved a case of PALG. No case has been yet reported with PALG producing compression of globe and lateral rectus muscle sheath involvement.

##### Key words:

Lacrimal gland, Pleomorphic adenoma.

Copyright©2017, Raj et al. This is an open access article distributed under the Creative Commons Attribution License, which permits unrestricted use, distribution, and reproduction in any medium, provided the original work is properly cited.

Citation: Raj, A., Bahadur, H. and Shirazi, N. 2017. "An unusual presentation of Pleomorphic adenoma of Lacrimal gland a rare entity and review of literature", *International Journal of Current Research*, 9, (04), 49413-49416.

## INTRODUCTION

Pleomorphic adenoma of the lacrimal gland (PALG) is a rare benign tumor of the lacrimal gland. Lacrimal gland tumors represent approximately 9% of all orbital masses. Of those 9%, approximately 10% are PALG (Shields *et al.*, 2004). Pleomorphic adenoma is a neoplastic proliferation of epithelial cells that form characteristic ductal structures with surrounding myoepithelial cells (Weis *et al.*, 2009). Pleomorphic adenoma is the most common type of tumor in the parotid gland (80%) (Eveson *et al.*, 2005). The mean age of diagnosis of PALG was 48 in one large case series (Shields *et al.*, 2004). Because of the rarity of this tumor, the risk factors have not been elucidated. PALG typically presents with palpable mass on superolateral aspect of the orbit with slow growth and inferonasal displacement of the globe, unilateral painless, gradual, non axial proptosis. Biopsy may be appropriate in cases of diagnostic dilemma (Lai *et al.*, 2009). Definitive treatment of PALG is complete excision due to common recurrence and malignant transformation with incomplete excision. Radiological investigation may be done either by computerized tomography (CT) or magnetic resonance imaging (MRI). The treatment is the complete excision of the tumor and adjacent tissues (Halli *et al.*, 2011).

\*Corresponding author: Raj, A.

Department of Ophthalmology, Himalayan Institute of Medical Sciences, Swami Rama Himalayan University, Jolly Grant, Dehradun

## Case report

A 59 years old male presented with a history of a slowly progressing painless swelling in the lateral aspect of the left orbit for last two years duration. The swelling started growing fast since last two months. On local examination the overlying skin was normal without any evidence of abnormal pigmentation. The left eye showed puffiness in the periorbital area. On palpation of left upper eye lid revealed a firm, nodular, non tender, non pulsatile and irreducible swelling in the superolateral aspect of the left orbit (Figure 1a). Retropulsion of the globe was limited in comparison to the contralateral globe. No bruit or pulsation were felt. The patient had no ptosis, proptosis or lagophthalmos. Bells phenomenon was good. Extraocular movements were normal except restriction of the abduction and supraversion of left eye associated with diplopia in abduction. On examination best corrected visual acuity was 20/30 both eyes with -0.75 D Sph with addition of +2.75D Sph for both eyes for near vision. On slit lamp biomicroscopy of the right eye, anterior segment was unremarkable but on left side there was a mass visible on superolateral aspect of the globe in area of lacrimal gland. Intraocular pressure was 16mmHg for both eyes with goldmann applanation tonometry. Dry eye work up in form of Schirmer's, tear film break up time, tear film height was done which was within normal limits. Pupillary reflexes were normal.

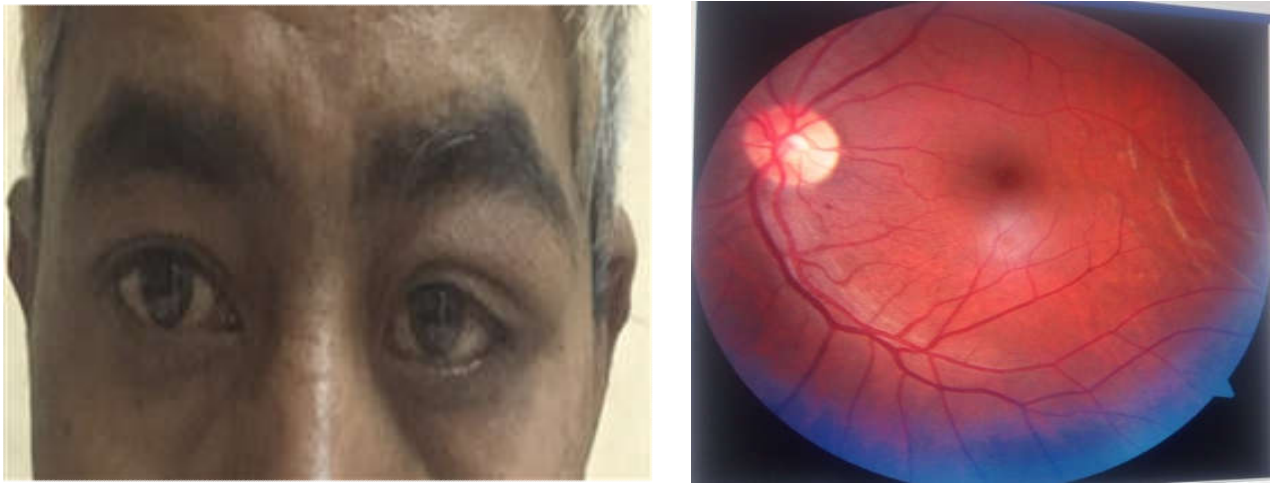


Figure 1 (a). Puffiness around the left upper lid (b) Fundus shows the choroidal folds

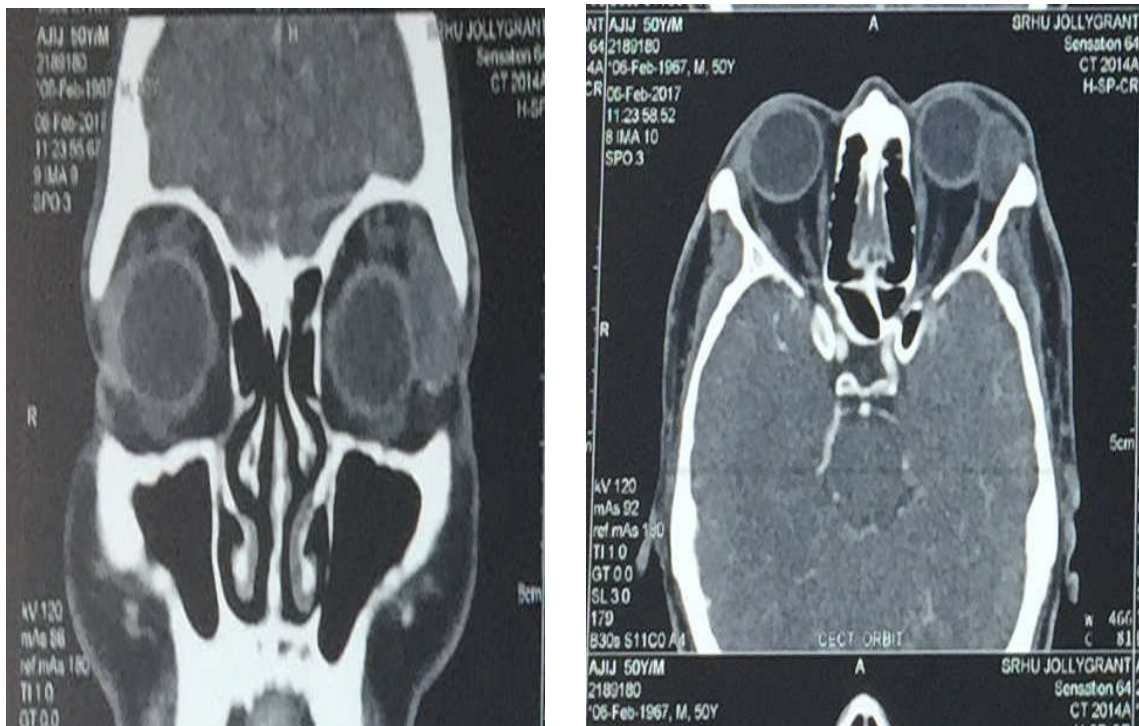

Figure 2 (a). CT Coronal section showing mass (b) CT Axial section showing mass indenting globe

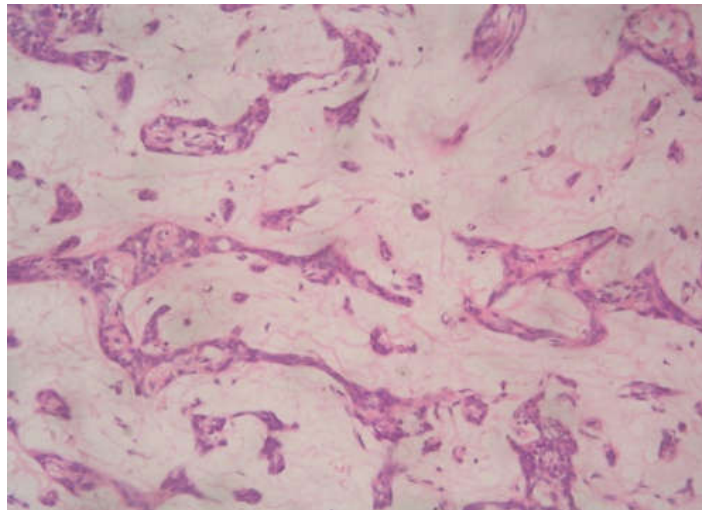


Figure 3. Photomicrograph : Hematoxylin and Eosin : 20x10X: Epithelial component forming tubules and cords in a background of fibromyxoid stroma

Fundus examination of left eye showed multiple crescentic choroidal folds on lateral aspect starting about two disc diameter away from the fovea and tapering near the inferotemporal arcade which showed the compression effect of the growth on globe. The folds were having their convexities towards the disc (Figure 1b). The fundus examination of the other eye was unremarkable. Systemic history was unremarkable. Contrast enhanced computed tomography of orbit was ordered which revealed a heterogeneously enhancing mass lesion in extraconal compartment in superolateral aspect of the left orbit measuring 2.4x2.2x1.6cm on axial and coronal scans. Laterally the mass was indenting the overlying lateral wall of the globe. The fat planes with lateral rectus were ill defined. No evidence of calcification or any bony erosion was seen. (Fig 2a,b) Surgical excision was planned as it was increasing in size and compressing the globe. Superolateral orbit was approached via the upper lid. The mass was approached by blunt and sharp dissection and separated from the lateral periorbital rim and was removed with its capsule intact. Care was taken to avoid any damage to the lateral rectus and levator muscle. Excised mass was sent for histopathological examination and the diagnosis of PALG was established. After three months the CT scan of orbit was done but no evidence of recurrence was found. On gross examination it was a single globular, greyish brown, soft tissue piece measuring 25x20x16mm with areas of haemorrhage on its outer surface.

### Microscopic examination

Sections showed a well encapsulated benign mixed tumour of lacrimal gland. There was marked proliferation of cords, acini and tubules lined by columnar cells having round to oval nuclei and bland nuclear chromatin. Sheets of myoepithelial cells were also seen with supporting stroma of fibromyxoid without any evidence of malignancy (Figure 3). So diagnosis of benign PALG was established.

## DISCUSSION

Lacrimal gland tumours are a rare condition in clinical practice, constituting 7-9% of all orbital tumors (Santos *et al.*, 2010). Among all of them, the most common epithelial tumor is the PALG, accounting for more than half of the epithelial forms (Chandrasekhar *et al.*, 2001). Secondary metastasis to the lacrimal gland was also reported (Ferry *et al.*, 1975). The term pleomorphic (benign mixed tumor) was first defined and used by Willis. PALG is a benign indolent tumor, consisting of a very firm mass that leads to compression atrophy of the normal gland, displacement of residual lacrimal tissues and is surrounded by a 'pseudocapsule' into which small sprouts of adenoma may project. Most cases (90%) involve the orbital lobe of the lacrimal gland (Rose *et al.*, 2009) PALG is most frequent in the third and fourth decade, with no gender preponderance. The clinical presentation is usually characterized by a painless palpable mass in the upper external quadrant of the orbit which was true for our case also. It shows slow growth and inferonasal displacement of the globe (Santos *et al.*, 2010). There may also be an increase in lacrimation and intrabulbar pressure visual impairment and diplopia (Hallis *et al.*, 2011). Malignancy is suspected when there is a fast onset of symptoms, pain, and radiographic evidence of bone destruction (Santos *et al.*, 2010). Malignant transformation can occur in 10-20% of PALG. Seventy-five percent of pleomorphic adenomas transform into pleomorphic

adenocarcinoma, while the rest transform into cystic carcinoma (Wright *et al.*, 1992). Radiological investigation like CT or MRI makes the cornerstone for its investigation as CT was done for the present case also. It provides information on anatomic extent, configuration, margins and angulation features of a lacrimal gland fossa mass. However, CT provides more details about bone destruction and presence of calcification, while MRI provides better internal tissue features and intracranial extension (Gunduz *et al.*, 2003). Although the tumor presents characteristic clinical and radiological features, which usually allows preoperative diagnosis, the definitive diagnosis is based on the histopathological examination (Ostrosky *et al.*, 2015).

Differential diagnosis includes lymphoma, chronic dacryoadenitis, Sjogren's syndrome, adenoid cystic carcinoma, granulomatous dacryoadenitis (sarcoidosis), benign lymphoid hyperplasia, cavernous hemangioma, intralacrimal schwannoma. The treatment is the complete excision of the tumor and adjacent tissues, usually by lateral orbitotomy. It is believed that preoperative biopsy and incomplete resection could lead to the tumor recurrence (even after years), as well as to malignant transformation (Hallis *et al.*, 2011). Complications following surgery include orbital hemorrhage, edema, optic nerve compression, orbital infection, lateral gaze palsy (Hallis *et al.*, 2011). In addition dry eye, ptosis, lid retraction and transient diplopia were also seen (Prabhakaran *et al.*, 2010). Lateral gaze palsy and diplopia occurred in the present case also. The prognosis is good when the lesion is completely excised with an intact capsule. A recurrence rate of 3% within five years has been reported in complete excisions and a recurrence rate of 32% over 15 years in incomplete ones. It is estimated that 10% of pleomorphic adenomas undergo malignant change within 20 years after first treatment and 20% by the end of 30 years. Malignant transformation of a benign pleomorphic adenoma into a squamous cell carcinoma has also been reported 19 years after the initial operation (Chandrasekhar *et al.*, 2001). For the patients suspected to have pleomorphic adenoma, incisional biopsy should not be performed in order to prevent the likelihood of a relapse to occur. The displacement of the mass with its capsule can extend the patients' lives and improve their quality of life. We consider our case unusual due to its presentation at relatively older age, without proptosis and invasion of the sheath of lateral rectus muscles, with restricted adduction, compressing the globe and producing the choroidal folds which are rare features in cases of PALG.

### Acknowledgements

We acknowledge Mr. Surendra Singh Bhandari for his help in photographic documentation, computerized editing & technical support.

**Conflict of interest:** None declared

**Financial Support:** Nil

## REFERENCES

- Chandrasekhar J, Farr DR, Whear NM. 2001. Pleomorphic adenoma of the lacrimal gland: case report. *Br J Oral Maxillofac Surg.*, 39(5):390-3

- Eveson JW, Kusafuka K, Stenman G, Nagao T. 2005. "Pleomorphic Adenoma" *Pathology and Genetics of Head and Neck Tumors*, 253-258.
- Ferry AP, and Font RL. 1975. Carcinoma metastatic to the orbit. *Mod Probl Ophthalmol.*, 14:377-381.
- Gunduz K, Shiels CL, Gunalp I, Shields JA. 2003. Magnetic resonance imaging of unilateral lacrimal gland lesions. *Graefes Arch Clin Exp Ophthalmol.*, 241:907-913.
- Hallis RC, Mishra S, Kini YK, Kharkar VR, Hebbale MA. 2011. Modified lateral orbitotomy approach: A novel technique in the management of lacrimal gland tumors. *J Craniofac Surg.*, 22: 1035-1038
- Lai T, Prabhakaran VC, Malhortra R, Selva, D. 2009. Pleomorphic adenoma of the lacrimal gland: is there a role for biopsy? *Eye.*, 23:2-6.
- Ostrosky A, Klurfan FJ, Gonzalez MJ, Camaly D, Villa D. 2005. Pleomorphic adenoma of the lacrimal gland. Case report. *Med Oral Patol Oral Cir Bucal.*, 10: 86-89
- Prabhakaran VC, Cannon PS, McNab A, Davis G, O'Donnell B, Dolman PJ, et al. 2010. Lesions mimicking lacrimal gland pleomorphic adenoma. *Br J Ophthalmol.*, 94:1509-1512
- Rose GE. 2009. To crash or not to crash? Probability in the management of benign lacrimal gland tumours. *Eye.*, 23(8): 1625-1628
- Santos RR, Damasceno RW, de Pontes FS, Cursino SR, Nishiwaki-Dantas MC, Vital Filho J, et al. 2010. Ten-year follow-up of a case series of primary epithelial neoplasms of the lacrimal gland: clinical features, surgical treatment and histopathological findings. *Arq Bras Oftalmol.*, 73:33-39.
- Shields JA, Shields CL, Rcartozzi R. 2004. Survey of 1264 Patients with Orbital Tumors and Simulating Lesions. *Ophthalmology.*, 111:997-1008.
- Weis E, Rootman J, Joly TJ, et al. 2009. Epithelial Lacrimal Gland Tumors. *Arch Ophthalmol.*, 127:1016-1028.
- Wright JE, Rose GE, Garner A. 1992. Primary malignant neoplasms of the lacrimal gland. *Br J Ophthalmol.*, 76:401-407.

\*\*\*\*\*