



CASE STUDY

SMILE ENHANCEMENT WITHOUT ORTHODONTIC INTERVENTION

*¹Chowdhary Zoya, ²Sharma Vandana, ³Bhardwaj Puneet and ⁴Rai Rohit

¹Department of Periodontology, Teerthankar Mahaveer Dental College, Moradabad, U.P., India

²Department of Periodontology, Vyas Dental College, Jodhpur Rajasthan., India

³Department of Periodontology, Azamgarh Dental College, Azamgarh, U.P., India

⁴Department of Dentistry, Jawaharlal Nehru Medical College, Ajmer, U.P., India

ARTICLE INFO

Article History:

Received 22nd February, 2017

Received in revised form

13th March, 2017

Accepted 25th April, 2017

Published online 19th May, 2017

ABSTRACT

Excessive gingival display is a common esthetic hurdle in an individual's personality, as it may lead to a poor smile which impacts the person's appearance as well as the confidence. This report describes two case reports where the gummy smile was corrected without orthodontic intervention. The procedures are beneficial to patients desiring less invasive alternative to orthognathic surgery and is safe with minimal risk/ side effects along with minimal treatment time as compared to orthodontic treatment.

Key words:

Aesthetics,
Crown lengthening,
Gummy smile,
Lip repositioning,
Smile line.

Copyright©2017, Chowdhary Zoya et al. This is an open access article distributed under the Creative Commons Attribution License, which permits unrestricted use, distribution, and reproduction in any medium, provided the original work is properly cited.

Citation: Chowdhary Zoya, Sharma Vandana, Bhardwaj Puneet and Rai Rohit, 2017. "Smile enhancement without orthodontic intervention", *International Journal of Current Research*, 9, (05), 49960-49963.

INTRODUCTION

The main objective of dental clinicians is to meet the patient expectations (Butler *et al.*, 1998). A person's smile is one of the most important factor for the first impression (Loi *et al.*, 2010) as smile is said to be the non-verbal method of communication. The harmonious relationship among the dentition (premolar to premolar), the periodontium (gingival line), and the lips; that will make or break a smile. Patients with excessive gingival display, referred to as "gummy smile" (Lang, 1995; Lanning *et al.*, 2003) usually experience dissatisfaction and are conscious about their clinical appearance (Kassagani *et al.*, 2012). The etiology of gummy smile may include gingival enlargement, insufficient clinical crown length, vertical maxillary excess, anterior dentoalveolar extrusion, altered passive eruption, short or hyperactive upper lip and/ or combinations (Garber and Salman, 1996; Silberberg *et al.*; 2009; Lang; 1995; Levine and McGuire, 1997). In the recent year excessive gingival display/ gummy smile correction has received increased emphasis in dental literature and different treatment modalities have been introduced to correct it.

Gummy smile cases are treated by Orthognathic surgery, but these procedures are quite invasive and requires hospitalization of the patients (Tasdemir *et al.*, 2014). For these reasons, lip repositioning procedure, crown lengthening procedures are undertaken, as they are less invasive and have minimal complications. Clinical crown lengthening is a periodontal resective procedure aiming at partial removal of supporting periodontal tissue to increase the exposure of coronal tooth structure. According to the American Academy of Periodontology it is "a surgical procedure designed to increase the extent of supragingival tooth structure for restorative or esthetic purposes by apically positioning the gingival margin, removing supporting bone, or both maybe accomplished by orthodontic tooth movement" (GPT, 2001). Crown lengthening is basically divided into aesthetic and functional types. Clinical smaller crown maybe due to excessive coverage of the coronal part of the tooth by the tissue/ or may be associated with posterior bite collapse or excessive parafunctional patterns (bruxism, etc.) that lead to reduced crown height (Goldberg *et al.*, 2001). Lip repositioning procedure was first described in the plastic surgery literature in 1973 (Rubinstein and Kostianovsky, 1973). The objective is to partially inhibit gingival display by limiting the retraction of elevator smile muscles (i.e. zygomaticus minor, levator anguli, orbicularis oris, and levator labii superioris), and the technique involves removing a strip of maxillary vestibule mucosa and suturing

*Corresponding author: Chowdhary Zoya,

Department of Periodontology, Teerthankar Mahaveer Dental College, Moradabad, U.P., India.

the mucosa to the mucogingival line (Rubinstein and Kostianovsky, 1973). It results in shallow vestibule, restricting the muscle pull thereby reducing the gingival display during smiling. The authors here present two smile enhancement case reports treated with crown-lengthening and lip repositioning procedures for the correction of excessive gingival display.

CASE REPORT

Case 1

A 21-year-old female patient reported to the Department of Periodontology with a complaint of small appearance of her teeth and desired a more esthetic smile (Figure 1). There was no history of swelling in any part of the oral cavity and had no relevant medical history. On examination it was seen that the crown of the maxillary anterior teeth were covered with the gingiva, giving an appearance of small clinical crown in the maxillary anterior region. The oral hygiene status was found to be good. Intraoral periapical radiograph (IOPAR) revealed no abnormalities in the region. Blood examinations of the patient revealed normal values.

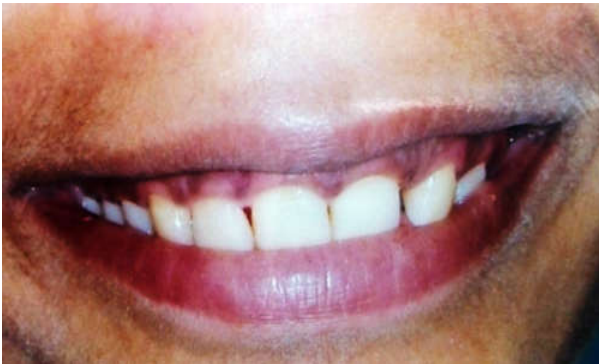

Figure 1. Pre-operative photograph

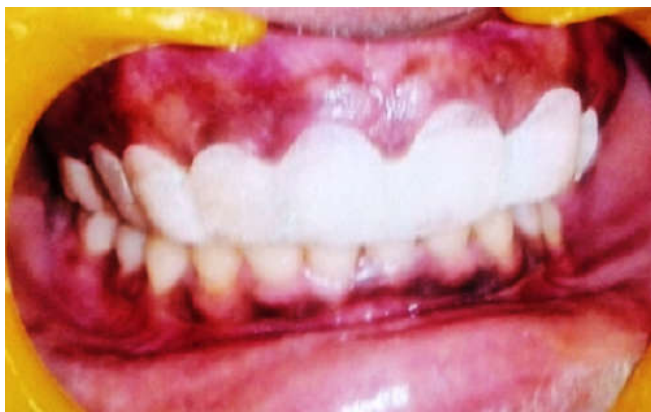

Figure 2. Surgical stent placed.

TREATMENT

The treatment comprised of oral prophylaxis and excision of the gingiva over the anatomic crown. To start with thorough scaling was carried out & the response to the same was evaluated after 1 weeks of time. A surgical stent was made with clear acrylic with its margins at the cemento-enamel junction of the teeth, for guidance. The excision of the lesion was made by using a BP blade no.11 which was guided along the margins of the surgical stent, making an external bevel incision at an angle of 45° (Figures 2-4), following saline irrigation & covered with periodontal dressing (Coe-Pac).

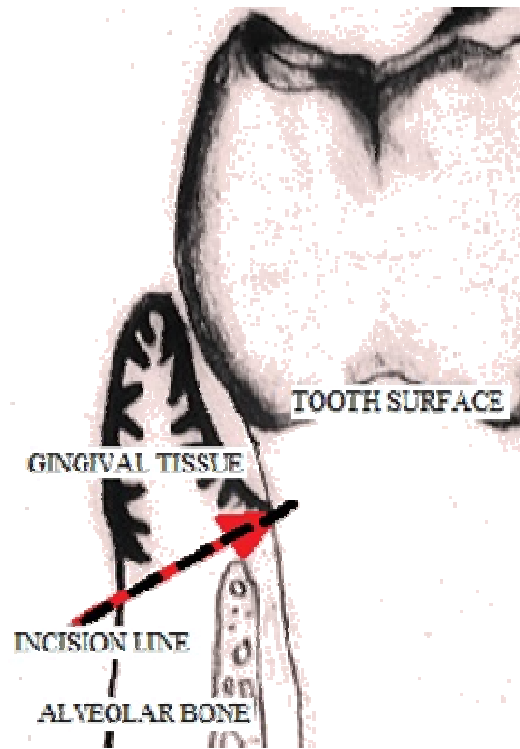


Figure 3. Diagrammatic representation of external bevel incision

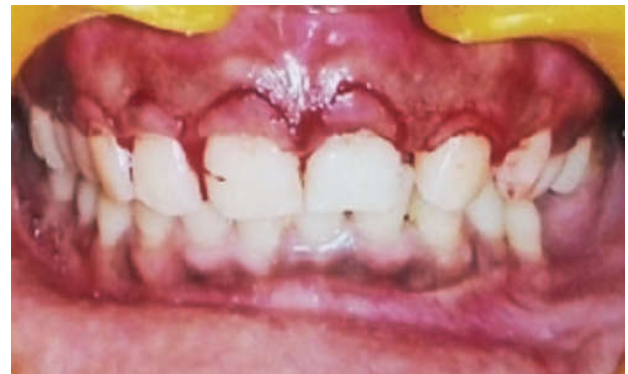

Figure 4. Incision made using BP blade no.11

Post-operative instructions were given to the patient along with prescription of Tab. Diclomol, 8hrly for 3 days and Chlorhexidine gluconate for rinsing twice daily for 7 days. The patient was recalled after 1 week and then after 3 months. The healing was uneventful & satisfactory without any sign of trauma to the underlying structures (Figure 5).

Case 2

A 20-year-old male patient reported to the Department of Periodontology, with the chief complaint of excessive display of gums. There were no significant medical or family history and the patient presented with no medical conditions that could contradict the surgical procedure. On extra oral examination, there was no gross asymmetry seen bilaterally. A moderate gingival display was seen during smiling which extended from the maxillary right second premolar to the maxillary left second premolar (Figure 6). On intraoral examination, it was determined that the cause for gummy smile was the hyperactive upper lip. An informed consent from the patient was obtained after explaining the treatment and also its benefits and possible complications. The patient was then scheduled for a repositioning surgery.

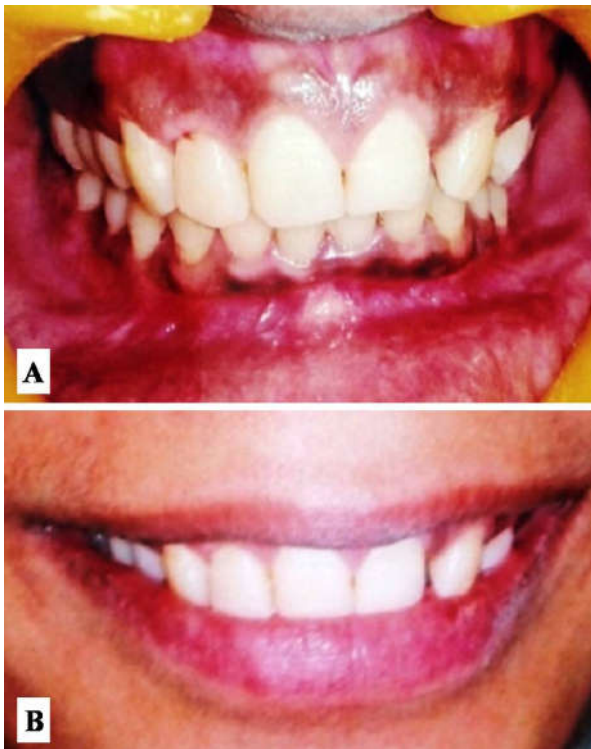

Figure 5 (A & B): Post-operative photograph

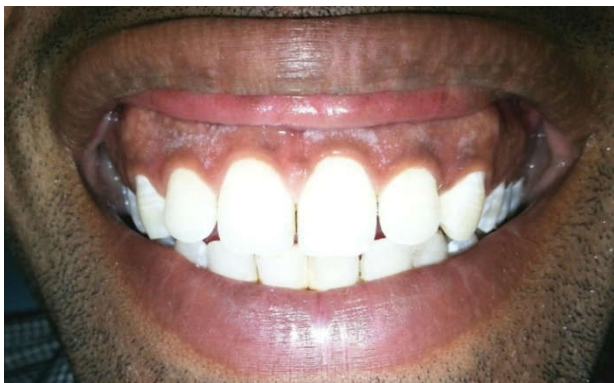

Figure 6. Pre-operative photograph

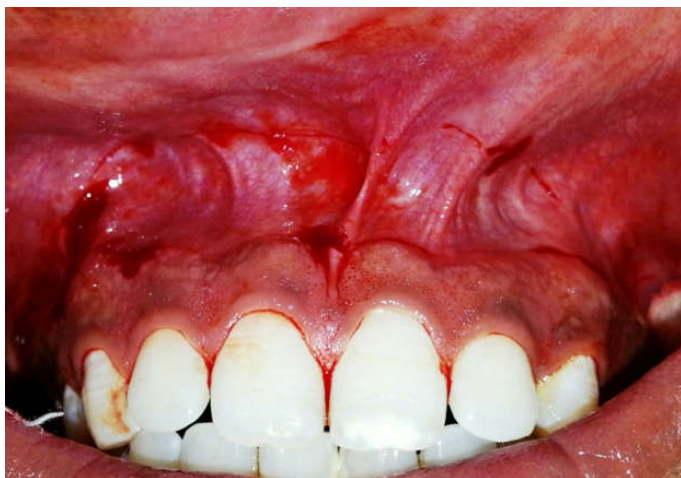

Figure 7. Incisions made using scalpel

Treatment

The treatment comprised of oral prophylaxis and lip repositioning surgery. Complete mouth disinfection was performed followed by anesthetization of the surgical site.

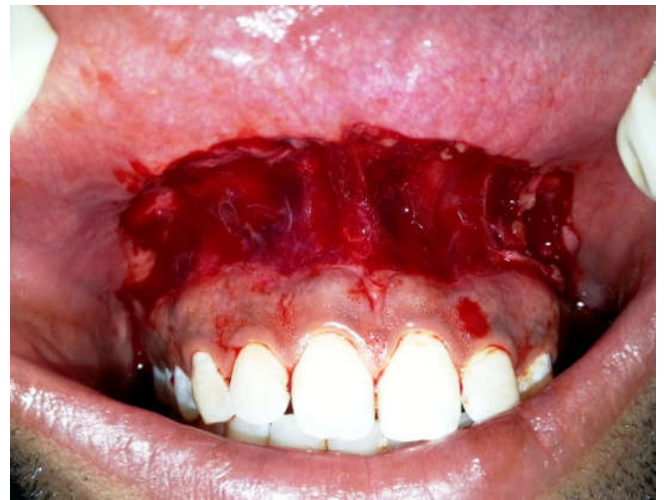

Figure 8. Exposed submucosa after removal of the mucosal strips

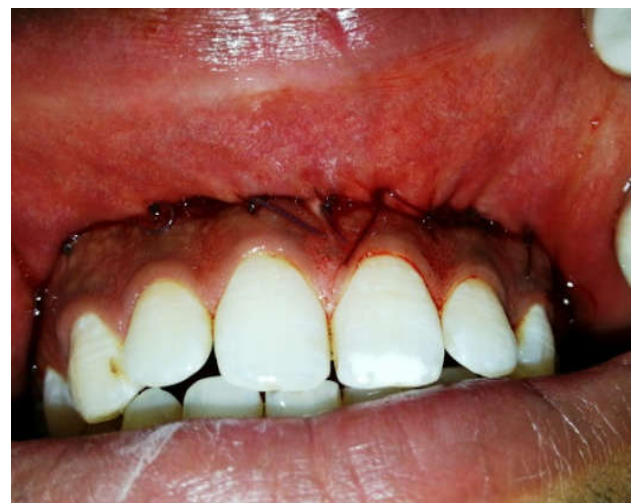

Figure 9. Intra-oral appearance following suturing

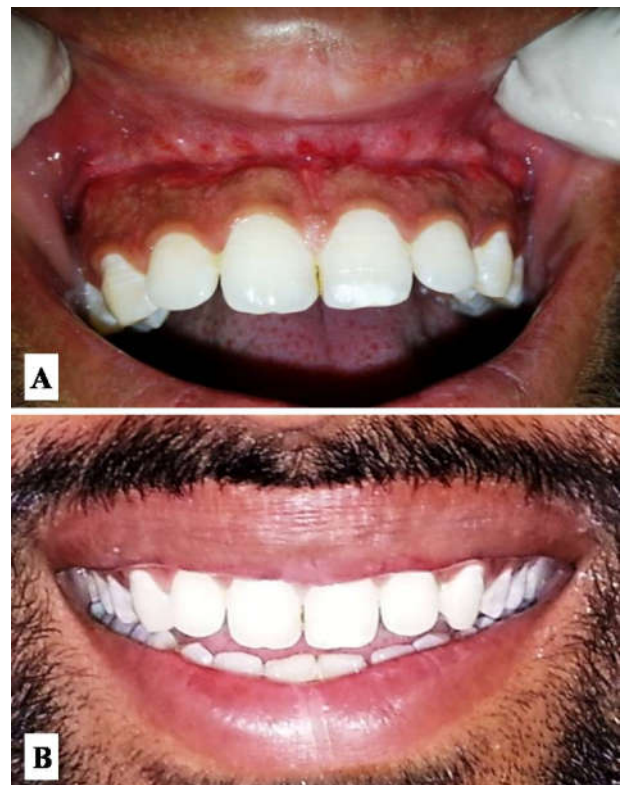


Figure 10 (A & B). Post operative photograph

A first partial-thickness incision was given along the mucogingival junction followed by a second incision, parallel to the first one in the labial mucosa, made at approximately 10-12mm from first incision (Figure 7). The two incisions were then connected at the mesial line angles of both the maxillary first molar in an elliptical manner. The strip of partial-thickness flap was removed, exposing the underline connective tissue (Figure 8). The two incision lines were approximated using continuous interlocking sutures (Figure 9). Post-operative instructions were given to the patient along with prescription of Tab. Diclomol, 8hrly for 5 days and Chlorhexidine gluconate for rinsing twice daily for 10 days. The patient was recalled after 10 days for suture removal and the healing was uneventful with a reduction in gingival display after 6 months (Figure 10).

DISCUSSION

Excessive gingival display or Gummy smile usually make people conscious of their clinical appearance and even have dissatisfaction (Kassagani *et al.*, 2012). There are basically four different etiologies that are responsible for the gummy smile (Simon *et al.*, 2007)

- Passive eruption, gingival dose not complete apical migration: These cases are corrected by crown lengthening (hard and soft tissue resection).
- Dentoalveolar extrusion: These cases are corrected by orthodontic intervention or even by orthognathic surgeries.
- Vertical maxillary excess: These cases are corrected by orthognathic surgeries.
- Hyperactive upper lip: These cases are corrected through various treatment options, with each having different outcomes, such as myectomy, botulinum toxin injection, lip elongation (associated with rhinoplasty), detachment of lip muscles, and lip repositioning (Silva *et al.*, 2013).

The case presentations aimed to present the outcome for a gummy smile treated with crown lengthening procedure and lip repositioning surgery. In both the cases, the clinician and the patients were satisfied with the clinical outcome, which further lead to boost in patient confidence. An accurate diagnosis and a pertinent case selection are critical for the success. The clinician must plan the treatment on the basis of etiology, patient needs, time duration required for treatment, patient satisfaction etc.

Conclusion

Periodontics deals with the functionally and aesthetically pleasing smile. The least invasive way of treating gummy smile requires proper diagnosis of the underlying etiology. Crown lengthening procedures and Lip repositioning surgery may be a good treatment alternative for reducing the excessive gingival display depending upon its etiology, as reported in the patients in this case report. Both the patient and the clinician were satisfied with the final outcome.

REFERENCES

- Butler, C.C., Rollnick, S., Pill, R, Maggs-Rapport, F., Stott, N. 1998. Understanding the culture of prescribing: a qualitative study of general practitioners' and patient' perceptions of antibiotics for sore throats. *BMJ.*, 317:637-642.
- Garber, D.A. and Salman, M.A. 2000. The aesthetic smila: Diagnosis and treatment. *Periodontol.*, 11:18-28.
- Goldberg, P.V., Higginbottom, F. L., Wilson, T.G. 2001. Periodontal considerations in restorative and implant therapy. *Periodontol.*, 25:100-109.
- Kassagani, S.K., Nutalapati, R. and Mutthineni, R.B. 2012. Esthetic Depigmentation of Anterior Gingiva: A case series. *NY State Dent J.*, 78:26-31.
- Lang, N. P. 1995. Periodontal considerations in prosthetic dentistry. *Periodontol.*, 9:118-131.
- Levine, R.A. and McGuire, M. 1997. The diagnosis and treatment of the gummy smile. *Compend Contin Educ Dent.*, 18(8):757-762.
- Loi, H., Nakata, S. and Counts, A.L. 2010. Influence of Gingival Display on Smile Aesthetics in Japanese. *Eur J Orthod.*, 32:633-637.
- Rubinstein, A.M. and Kostianovsky, A.S. 1973. Cirugia Estetica de la Malformacion de la Sonrisa. *Pren Med Argent.*, 60: 952.
- Silberberg, N., Goldstein, M., Smidt, A. 2009. Excessive gingival display- etiology, diagnosis, and treatment modalities. *Quintessence Int.*, 40:809-818.
- Silva, C.O., Riberio-Junior, N.V., Campos, T.V.S., Rodrigues, J. and Tatakis, D. 2013. Excessive Gingival Display: Treatment by a Modified Lip Repositioning Technique. *J Clin Periodontol.*, 40: 260-265.
- Simon, Z., Rosenblatt, A. and Dortman, W. 2007. Eliminating a Gummy Smile with Surgical Lip Repositioning. *Cosmet Dent.*, 23:102-108.
- Tasdemir, Z., Alkan, B.A. and Alkan, A. 2014. Treatment of Excessive Gingival Display Using a Lip Repositioning Technique: *A Case Report. J Dent App.*, 1(1): 13-15.
