



CASE REPORT

MEIGS SYNDROME: A CASE REPORT

Dr. Manjisha M. Litake and *Dr. Kaushal Kumar Rai

Byramjee Jeejeebhoy Government Medical College, Jai Prakash Narayan Road,
Near Pune Railway Station, Pune – 411001

ARTICLE INFO

Article History:

Received 26th May, 2017
Received in revised form
08th June, 2017
Accepted 19th July, 2017
Published online 31st August, 2017

Key words:

Kyphoscoliosis
Meigs' syndrome
Ovarian tumor
Fibroma

INTRODUCTION

The Meigs' syndrome is defined as the presence of ascites & hydrothorax associated with a benign ovarian tumor mostly fibroma that disappears after the removal of the tumor. Joe Vincent Meigs (1892-1963), a professor of the Harvard Medical School of Gynecology drew attention to the syndrome (Lurie, 2000; Griffin, 1996). Meigs' syndrome is a strange clinical entity that is also considered to be an uncommon complication of fibroma of the female genital tract. The more frequently observed type of ovarian tumor is the fibroma. Ovarian fibroma represents 2 to 5% of ovarian tumor and out of this only 1 to 2% of cases present as Meigs syndrome. Ascites in ovarian fibroma present in 10 to 15% of cases while hydrothorax in only 1% of cases. It is accepted that the uterine tumors such as the fibromas, although common, can be associated to ascites and hydrothorax, as well as leiomyoma of the broad ligament. The presumptive diagnosis of this pathology is basically clinical in spite of the priceless value that imaging techniques like ultrasonography, contrast enhanced computed tomography (CECT) have in confirming the presence of ascites, pleural effusion and the characteristics of the ovarian tumor. Cytomorphology of the pleural and ascitic liquid is also used as well as the serum levels of carcinogenic antigen-125 (CA-125) to discard the malignancy of the ovarian tumor that is associated with the syndrome. The definitive diagnosis is usually postoperative. All the signs and symptoms of Meigs' syndrome disappear with the surgical excision of the ovarian tumor by means of the abdominal surgery.

Copyright©2017, Dr. Manjisha M. Litake and Dr. Kaushal Kumar Rai, This is an open access article distributed under the Creative Commons Attribution License, which permits unrestricted use, distribution, and reproduction in any medium, provided the original work is properly cited.

Citation: Dr. Manjisha M. Litake and Dr. Kaushal Kumar Rai, 2017. "Meigs Syndrome: A case report", *International Journal of Current Research*, 9, (07), 55680-55682.

CASE: A 50 year old female diagnosed case of congenital kyphoscoliosis admitted with chief complaints of abdominal lump since 3 months and pain in abdomen since 3 days with increase in intensity since 1 day. There was positive history of irregular, heavy and prolong menstrual cycle. On physical examination there was evidence of 15cm×10cm firm, well-defined, bosselated, non-tender, mobile, intraperitoneal lump present in lower abdomen more on right side and was mobile. There was evidence of flank fullness with dull note on percussion present. Ultrasonography of abdomen and pelvis suggestive of well-defined space occupying lobulated mass of size 12cm×14cm×13 cm in peritoneal cavity with normal right ovary and uterus. Left ovary could not be separately distinguished from the lesion. There is evidence of moderate ascites with moderate right side pleural effusion and minimal on left side. X ray chest PA view shows right sided blunting of costo-phrenic angle. Her RFTs/LFTs and CBC workup were within normal limits with cytomorphologic study of ascetic and pleural fluids negative for malignant cells except raised serum CA 125 levels to 428 U/ml. CECT of abdomen and pelvis was done and suggestive of well-defined, 9×15.3×8.6cm, lobulated

solid mass in abdominal and pelvic cavity in midline with central areas of necrosis causing displacement of bowel loops. Fundus of uterus not separately visualized from the mass with blood supply from left internal iliac artery. Bilateral kidney appears mal-rotated with right side pelvis directed infero-medially and left side pelvis postero-medially. Moderate to gross free fluid in abdomen present with sub-centrimetric pre and para aortic lymph node noted. There is evidence of kyphoscoliosis deformity towards left with moderate right sided pleural effusion and mediastinal shift to left.

Based on these finding on CECT three differentials were given

1. Uterine pedunculated fibroid
2. Mesenteric GIST
3. Left sided ovarian tumor

Right sided 32 Fr. chest tube inserted in 5th intercostal space along mid axillary line under all aseptic precaution. Approx. 500cc of pleural fluid drained and sent for cyto-morphologic workup which was transudate in nature negative for malignant cells. She underwent exploratory laparotomy, Intra-operative findings were:

*Corresponding author: Kaushal Rai,

Byramjee Jeejeebhoy Government Medical College, Jai Prakash Narayan Road, Near Pune Railway Station, Pune – 411001

- Moderate ascites
- 15×12×13 cm pelvic mass arising from left ovary.
- Right sided simple ovarian cyst.
- Multiple omental seedlings.

Excision of mass with trans-abdominal hysterectomy with bilateral salpingo-oophorectomy with omentectomy under general anaesthesia. On Histopathological examination :

Gross evaluation: Single soft tissue mass measuring 15cm×10cm×9 cm. externally whitish with bosselated appearance, on cut section shows homogenous whorled appearance at places with fallopian tube 4cm size attached to it.

necrosis. Other sections from uterus, right ovary and omentum were unremarkable.

IMPRESSION: FIBROMA

Patient discharged on post operative day (POD) 6 with resolved pleural effusion, chest tube removed on POD 5. She advised follow up for suture removal and follow up period of 1 month was uneventful.

DISCUSSION

The cardinal features of Meigs' syndrome are

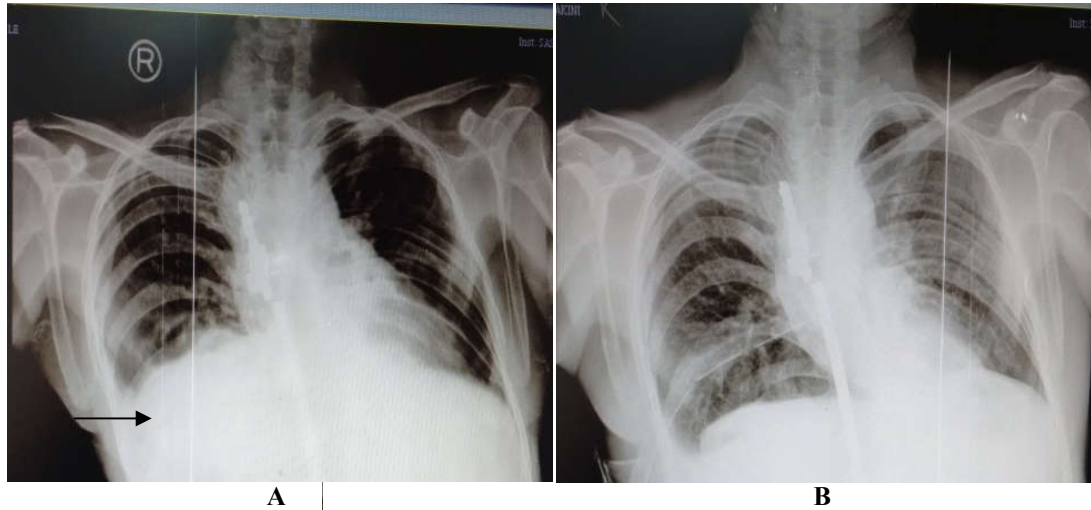


Fig:1- (A) Showing X ray chest PA view showing right sided pleural effusion with blunting of CP angle; (B) showing lung expansion after chest tube insertion

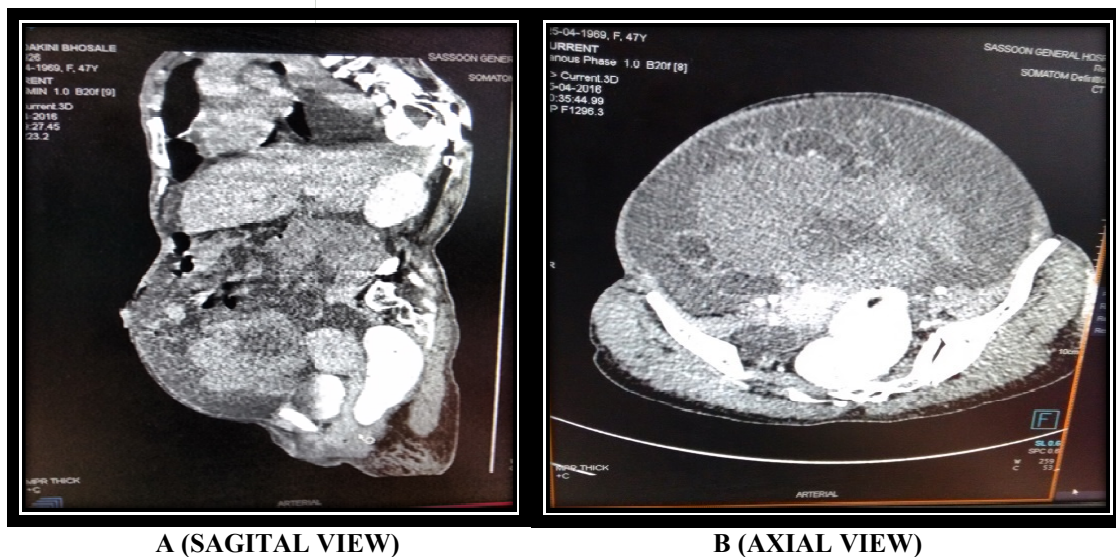
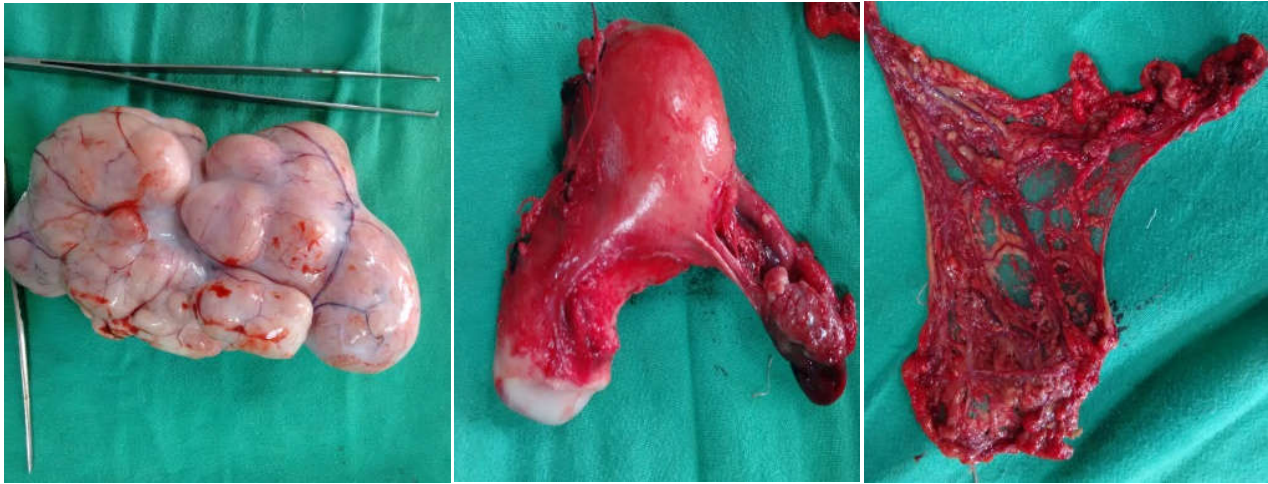


Fig:2- CT scan showing well defined mass with fundus of uterus not separately identified(A); (B) showing mass, uterus and cyst in right ovary

Hysterectomy with salpingo-oophorectomy specimen contains cervix, uterus with endometrial thickness 0.8cm, myometrial thickness 1.2cm with fallopian tube and ovary with hemorrhagic fluid in it.

MICROSCOPY: Section study through tumor composed of bundles and fascicles of spindle shaped cells with elongated nuclei with marked deposition of collagen with focal myxoid changes also noted, with no mitosis and no evidence of

- A benign ovarian tumour
- Ascites (10-15%)
- Pleural effusion (1%), The ovarian tumour is usually a fibroma (2-5% of all ovarian tumor) but may be a thecoma, cystadenoma, or granulosa cell tumour. If the tumour is resected, the fluid resolves. As consistent with our case. Most features are related to ascites and pleural effusion but before the menopause there may be menstrual symptoms too.



- Fatigue
- Dyspnea (initially on exertion)
- Distended abdomen with associated weight gain
- Non-productive cough
- Amenorrhea and irregular menstruation.

In presented case, patient was having abdominal distention, irregular, heavy and prolong menstrual cycle. The pleural effusion in the cases of ovarian tumors usually corresponds to an exudate. It is generally on the right side and can be massive on occasions, with unspecific biochemical or cellular unspecific characteristics of the liquid. Statistically, 70% of para-ascetic effusions are on the right, 15% on the left and 15% are bilateral. A possible pathogenesis for the formation of the pleural and peritoneal effusions in the case of ovarian tumors can be explained by the filtration of interstitial liquid to the peritoneum through the ovarian tumor capsule. This liquid can also diffuse to the space pleural through the diaphragmatic lymphatic vessels in the Bochdalek's foramen or through diaphragmatic defects.

The cytological exam of the ascetic and pleural liquid in patients with ovarian tumors should be performed in order to differentiate between reactive processes and tumor spread. In presented case pleural and ascetic fluid analysis was transudate in nature and both fluids negative for malignant cells. In the evaluation of the presented patient, we use this tumor marker and we believe that the CA-125 deserves special attention for its role in the preoperative evaluation of women with pelvic masses. Although CA-125 was originally described as tumor marker for ovarian cancer, at present its elevation (above 35 mIU/mL) is associated with several benign conditions as: endometriosis, leiomyoma, pregnancy, pelvic inflammatory disease, as well as diverse malignancies. Several authors have pointed out that CA-125 serum levels may raise in Meigs' syndrome and they suggested a suspicion of the syndrome in the presence of massive pleural effusion, even high serum levels of CA-125, a negative cytological study of the ascetic liquid and the absence of peritoneal implants at CT-scan.

Conclusion

Although not very common condition, a vigilant approach can help to achieve early diagnosis and curative treatment of this benign condition.

REFERENCES

- Bognoni V, Quartuccio A Jr, Quartuccio A. 1999. Meigs' syndrome with high blood levels of CA 125. A clinical case and review of the literature. *Minerva Ginecol.*, 51(12): 509-12.
- Bretelle F, Portier MP, Boublil L, Houvenaeghel G. 2000. Recurrence of Demons-Meigs' syndrome. A case report. *Ann Chir.*, 125(3): 269-77
- Griffin JP. 1996. Dame Mary Page-the first recorded case of Meigs' syndrome? *J R Coll Physicians Lond.*, 30(5): 465.
- Kazanov L, Ander DS, Enriquez E, Jaggi FM. 1998. Pseudo-Meigs' Syndrome. *Am J Emerg Med.*, 16(4): 404-5.
- Lurie S. Meigs' syndrome: the history of the eponym. 2000. *Eur J Obstet Gynecol Reprod Biol.*, 92(2): 199-204.
- Rozier R, Berger A, Cugnenc PH. 1998. Meigs' syndrome: is it possible to make a preoperative diagnosis? *J Gynecol Obstet Biol Reprod.*, 27(5): 517-22.
- Santangelo M, Battaglia M, Vescio G, Sammarco G, Gallelli G, Vetere A, Soommella L, Triggiani E. 2000. Meigs' syndrome: its clinical picture and treatment. *Ann Ital Chir.*, 71(1): 115-9.
- Tarnowski B, Krolewski P. 1998. True and pseudo-Meigs syndrome. *Ginekol Pol.*, 69(11): 813-6.
- Vasilev SA, Schloerth JB, Campeau J, et al., 1988. Serum CA-125 levels in preoperative evaluation of pelvic masses. *Obstet Gynecol.*, 71:751-756.
- Wiatrowska B, Krajci P, Berner A. 2000. Pseudo-Meigs' syndrome. *Tidsskr Nor Laegeforen.*, 120(3): 364-6.
- Zurawski VR Jr, Orjaseter H, Andersen A, et al., 1988. Elevated serum CA-125 levels prior to diagnosis of ovarian neoplasia: Relevance for early detection of ovarian cancer. *Int J Cancer.*, 42:677-680.
