



## RESEARCH ARTICLE

### RESTORING SMILES FOR THE YOUNG: TWO AESTHETIC AND FUNCTIONAL APPROACHES

\*<sup>1</sup>Jayshree Verma, <sup>2</sup>Mayank, <sup>3</sup>Kusha Thakur and <sup>4</sup>Saurabh Jain

<sup>1</sup>MDS Pedodontics & Preventive Dentistry

<sup>2</sup>Post Graduate student, Department of Prosthodontics, Himachal Dental College, Sundernagar, Distt. Mandi, Himachal Pradesh

<sup>3</sup>Post graduate student, Department of Prosthodontics, Himachal Dental College, Sundernagar, Distt. Mandi, Himachal Pradesh

<sup>4</sup>Post graduate student, Department of Periodontics, RUHS College of Dental Science, Jaipur

#### ARTICLE INFO

##### Article History:

Received 27<sup>th</sup> February, 2017

Received in revised form

13<sup>th</sup> March, 2017

Accepted 18<sup>th</sup> April, 2017

Published online 23<sup>rd</sup> May, 2017

##### Key words:

Early childhood caries, Premature loss, Aesthetic, Fibre post, Strip crowns, Fixed Functional Space Maintainer.

#### ABSTRACT

This paper describes why it is important to rehabilitate primary teeth damaged by early childhood caries and presents the step-by-step clinical sequence of restoration using two different approaches. One, using polyethylene fiber post followed by strip crowns after endodontic treatment, and the other, an aesthetic fixed functional space maintainer, whereby the maxillary primary second molars were used to support the appliance through bands and a wire that contained an acrylic flange bearing trimmed acrylic teeth, anteriorly. Both the techniques offer conservative, aesthetic, non-invasive and affordable treatment options.

*Copyright*©2017, Jayshree Verma. This is an open access article distributed under the Creative Commons Attribution License, which permits unrestricted use, distribution, and reproduction in any medium, provided the original work is properly cited.

**Citation:** Jayshree Verma, 2017. "Restoring smiles for the young: two aesthetic and functional approaches", *International Journal of Current Research*, 9, (05), 50724-50729.

#### INTRODUCTION

Premature loss of teeth due to trauma or dental caries is a common occurrence in children and has a profound effect on the oral health of the child which may result in a reduced masticatory efficiency, loss of vertical dimension, aesthetic-functional problems which often tend to cause undesirable tooth movements of primary or permanent teeth leading to malocclusion and loss of arch length (Khare *et al.*, 2013). In case of premature tooth loss in anterior incisal segment, there is minimum space loss and a linguodistal inclination of the teeth, causing a collapse of the anterior lingually, apart from closure of the space and shift of midline (Barber) (Tandon, 2008). The major consequence of early loss of maxillary primary incisors is most likely delayed eruption timing of the permanent successors as reparative bone and dense connective tissue covers the site. In addition, unattractive appearance and potential development of deleterious parafunctional habits (e.g. tongue thrust swallow, forward resting posture of the tongue, improper pronunciation of fricative sounds- "s", "f") may be of concern (McDonald, 2011; Da Silva, 2012).

It may also affect psychosocial and psychological growth patterns of the child that can interfere with the personality and behavioural development, manifesting as depression, increased shyness of a child along with poor friend circle and non-acceptable daily life style (Rocha Rachel de Oliveira, 2004). Mahmoud (2009) in a study to identify the negative effects of anterior tooth loss on patient's quality of life and satisfaction with their dentition; found reduced level of confidence among patients not having anterior teeth. The most frequent oral health issue is dental caries. Sometimes, it can affect even very small children, short after the eruption of the first teeth, being called early childhood caries (ECC). This particular type of dental caries has been defined by the American Academy of Pediatric Dentistry as "the presence of one or more decayed (non-cavitated or cavitated lesions), missing (due to caries), or filled tooth surfaces in any primary tooth in a child 71 months of age or younger" (American Academy on Pediatric Dentistry, 2008-2009). The condition, when associated with the bottle habit, has been characterized as first affecting the primary maxillary anterior teeth, followed by involvement of the primary molars. The extent of decay is almost always more severe in the maxillary incisors, and, frequently, by the time the child is brought to the dentist, much of the anterior clinical crowns are decayed or lost. ECC is not only limited to high-risk groups (developing countries), but involves children of all

\*Corresponding author: Jayshree Verma,

Bhojia Dental College & Hospital, Chandigarh- Nalagarh Road, Budh (Baddi), Teh. Baddi, Distt. Solan, Himachal Pradesh – 173205.

socioeconomic levels including middle- and upperclass populations (Waggoner, 2001). Full mouth rehabilitation including the esthetic restoration of such mutilated teeth is a challenge not only because of the limitations of the available materials and techniques but also because the children who require such restorations are usually among the youngest and least manageable group of patients. Most clinicians prefer to treat the emotionally immature children under general anesthesia. Treatment under general anesthesia has its own risks and limitations. The treatment is expensive and out of reach for most of the middle and low socioeconomic status children. All these factors must be taken into consideration before deciding the choice of restorative material (Cravero, 2004; Usha *et al.*, 2007). The purpose of this article is to review latest materials and techniques in managing primary anterior teeth and it documents two case scenarios to restore aesthetics, phonetics, function and prevention from deleterious oral habits.

With the introduction of new adhesive systems and restorative materials, a new approach for treating these teeth has been explained and documented, where fibre core posts are introduced into the cervical one third of the root canals of primary incisors after endodontic treatment, to avoid interference with process of permanent tooth eruption, followed by esthetic rehabilitation with strip crowns. Strip crowns are thin, transparent, celluloid preformed crowns that serve as support for the restorative material while being applied on the prepared tooth, during the restoration protocol (Mannocci, 2002; Steven Schwartz, 2015; Suzan Sahana, 2010). Second approach, is using a fixed functional anterior space maintainer "Hollywood bridge", using primary incisor denture teeth secured from a rigid steel wire (0.036 or 0.040) extended to bands or stainless steel crowns on the primary molars. Reasons for replacement with a prosthetic device constitute parental desire for aesthetics, space maintenance and speech development (Khare *et al.*, 2013; Adewumi *et al.*, 2012).

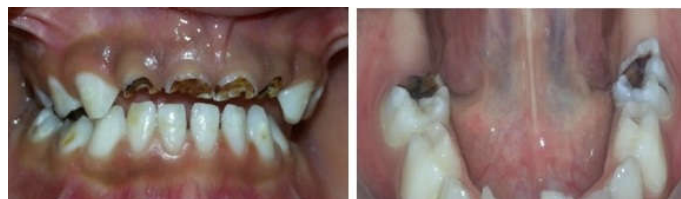## CASE REPORT

### Case 1

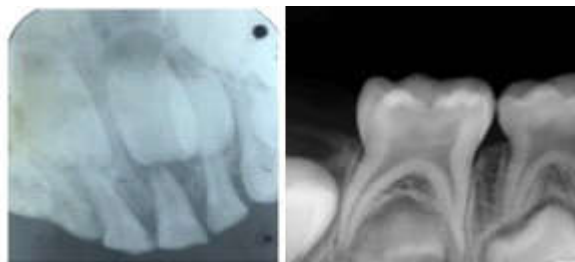A four year old boy reported to the outpatient department of Pedodontics and Preventive dentistry, Himachal Dental College Sundernagar, with the chief complaint of severely decayed upper front teeth and pain in the lower posterior region. Intraoral examination revealed multiple carious teeth (Figure 1&2). IOPA of teeth # 51,52,61,62 & 85 showed pulp involvement (Figures 3 & 4). 75 was found to be grossly decayed and was extracted, followed by the placement of a distal shoe space maintainer to guide the eruption of 36 (Figures 5, 6, 7& 8). An endodontic treatment was carried out for 51, 52, 61, 62 & 85 using Metapex (Meta Biomed Co. Ltd. Korea) as root canal filling material, followed by the placement of a stainless steel crown for 85 (Figures 9,10 & 11).

One week after the pulpectomy, the cervical third of each tooth (51, 52, 61 & 62) was prepared for the placement of an intra canal retainer i.e. a polyethylene fibre (Ribbond) post. The post-space was created by removing approximately 4mm of Metapex material by using a thin straight fissure bur with no visible material remaining on the walls of the post-space. The

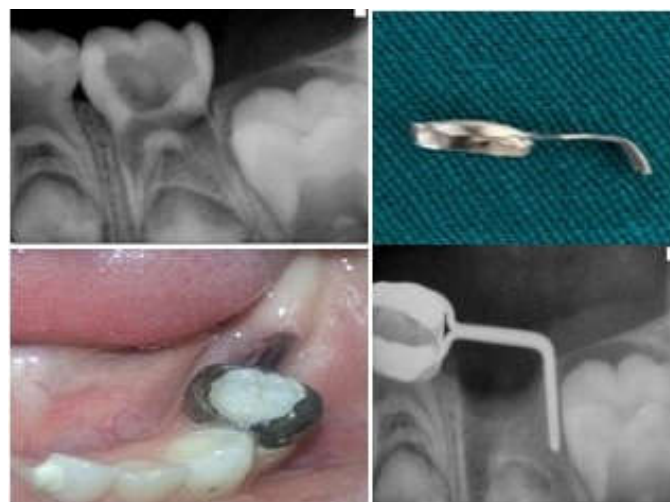prepared post space was then cleaned with saline, air-dried and acid – etched with 37% phosphoric acid for 15 seconds.



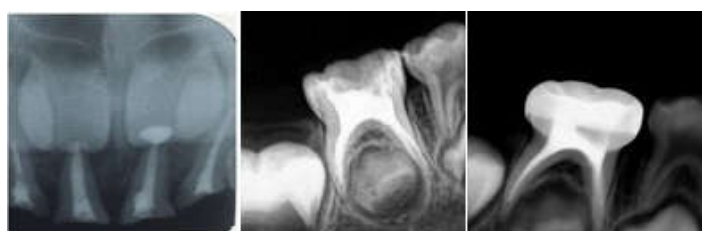
Figures 1 & 2. Pre-operative intraoral views



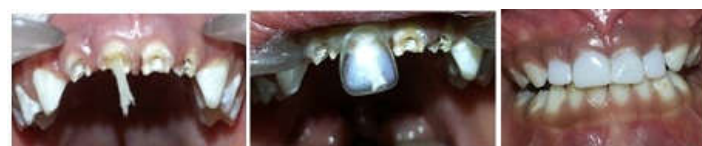Figures 3 & 4. IOPA of 51, 52, 61, 62 & 85



Figures 5, 6, 7 & 8. Grossly decayed 75, Distal shoe in place to guide the eruption of 36



Figures 9, 10 & 11. Endodontic treatment done for 51, 52, 61, 62 & 85, followed by SS crown placement with 85



Figures 12, 13 & 14. Ribbond fibre posts bonded followed by strip crowns

This space was rinsed and air dried and after that, a light cured bonding agent was applied. It was then light cured with for 20

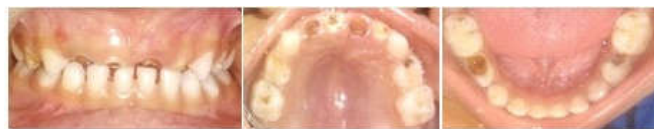seconds. The polyethylene post was then cured for 20 seconds in order for it to gain rigidity, before its insertion into the post-space. The fibre was inserted into the canal after it was immersed in the dental adhesives system (scotch bond, 3M), along with a thin layer of flowable composite. The incisal end of the post projected 2-3 mm above the remaining tooth structure. A visible light curing was done and finally, teeth were restored with strip crowns (Unitek Strip Crown, 3M ESPE) (Figures 12, 13 & 14). Crown form was selected, with a mesiodistal incisal width equal to the tooth to be restored. The composite shade A2 was selected for better esthetics. The selected crown form was trimmed with crown and bridge scissors, to remove excess crown material at cervical level; a small hole was created by punching the strip crown with a sharp explorer at the incisal edge or palatal surface, to allow flowing of excess composite; the crown form was filled with the selected material and seated on the tooth and checked for correct position; the excess material from the gingival area was removed; the composite material was light cured through the celluloid strip crown; the celluloid crown form was removed, occlusion was checked and final finishing, polishing of the restoration was performed. After completion of the procedure, post-operative photographs and radiographs were taken. Home care instructions, including oral hygiene measures and diet counselling, were given to the parents. Recall checkup was scheduled after every 6 months to assess the maintenance.

## Case 2

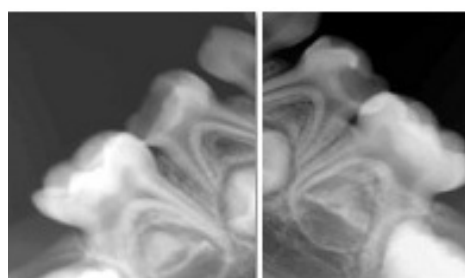
A four and half years old boy reported to Department of Pedodontics and Preventive Dentistry, with complaint of pain, unpleasant look, undernourishment, and alteration in speech. On examination it was found that the upper anterior teeth 51, 52, 61, 62 were grossly decayed (infected root stumps), 54, 55, 64 & 75 were found to be carious, while IOPA revealed the pulpal involvement of 74 & 84 (Figures 15, 16, 17, 18 & 19). Child's mother gave history of night bottle feeding upto 3 years of age. History also revealed improper diet and oral hygiene practices with no previous dental visit. Patient appeared undernourished (weight = 12 kg) and was uncooperative during diagnosis. Overall school performance of the child was only satisfactory and he was less friendly with his fellow classmates. On thoroughly evaluating the case, extraction of the root stumps in the maxillary arch was planned followed by placement of fixed functional space maintainer subsequently. All the carious teeth were restored and endodontic treatment was carried out for 74 & 84, followed by placement of stainless steel crowns (Figures 20, 21 & 22).

After obtaining written parental consent, preoperative occlusal analysis was performed and then the root stumps were extracted. Orthodontic bands (0.005-inch thickness and 0.180-inch width) were adapted on teeth 55 and 65 followed by alginate impression to make the working cast. Mandibular impression was also recorded and wax bite registration was done to maintain the vertical and antero-posterior relations of jaws and teeth. Under laboratory procedures, stone models were cast from the impressions. On the upper cast, a Nance palatal arch was adapted using 19-gauge spanning from one band to the other, and soldered to the bands. An additional wire framework, made of 21 gauge wire was soldered on the anterior aspect of the standard Nance framework which extended from mesial of one canine to the labial surface of the maxillary ridge to the mesial of the other canine to reinforce the acrylic segment with teeth. The free ends of the wire were

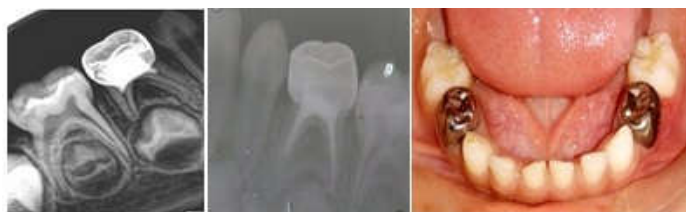then soldered to the corresponding molar bands. In the anterior region of the upper cast, a trial wax up was done with trimmed acrylic teeth (B1 shade). The acrylic teeth were originally of adult size, which had to be trimmed to the primary tooth sizes of 51, 52, 61 & 62. After cold mould seal application and cold cure acrylic resin insertion, the appliance was then removed from the cast and trimming, finishing, polishing was done. In the next appointment, the appliance was cemented on 55 and 65 with luting glass ionomer cement (Fuji I) and occlusion was checked for any premature contact (Figures 23, 24 & 25). The patient was advised to maintain proper oral hygiene.



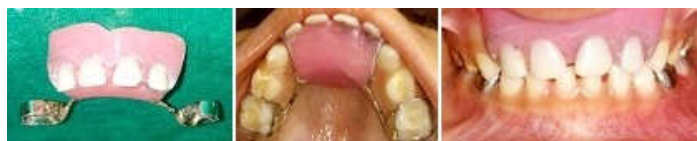Figures 15, 16 & 17. Intraoral clinical views



Figures 18 & 19. IOPA's showing pulpal involvement with 74 & 84



Figures 20, 21 & 22. Endodontic treatment done with 74 & 84 followed by SS crown restoration



Figures 23, 24 & 25. Hollywood bridge fabrication and insertion

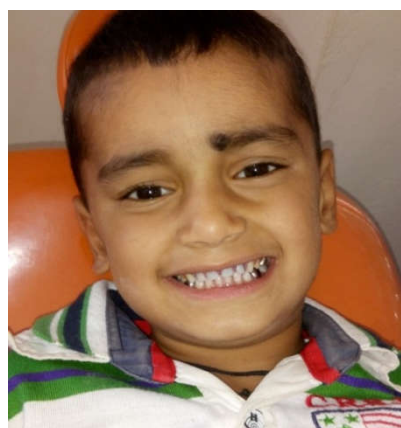


Figure 26. Happy smile

First recall of patient was done after 24 h followed by checkup every 3 months. The parent was informed that the appliance will be removed around the age of 6-8 years, to prevent interference of erupting permanent successors and was also advised to return immediately in case of any problem with the space maintainer, including distortion or breakage. Both the patient and the parents were satisfied with the treatment and the aesthetics (Figure 26).

## DISCUSSION

The premature loss of primary incisors is usually given little clinical attention unless severe closure of the space is noticed or there is evidence of an aberrant speech pattern and oral habits developing as a result (Chakraborty *et al.*, 2015). Northway (1984) stated that more space was lost in the first year of extraction than in successive years (Northway, 1984). Kumari (2006) found that the greatest space closure occurs during the first 4 months of the extraction (Padma Kumari, 2006). One of the important functions of the primary tooth is to occupy the physiological space and guide the eruption of its permanent successor (Singh, 2010). The aesthetic rehabilitation of primary anterior teeth has a vital psychological impact on recovery of patient's self-esteem (Slack and Jones) (Slack, 1955). The successful restoration of badly mutilated primary anterior teeth in preschool children is a challenging task. Conventional glass ionomer restorations have demonstrated high failure rates in the primary dentition. In addition, adhesion of the bonding agents to the enamel and dentine of primary teeth (less mineralized structure) is poor as compared to that of permanent teeth and can compromise the final restoration (Mehra, 2012; Mortada, 2004). When there is severe loss of coronal tooth structure, the use of posts placed inside the canal after endodontic treatment will give retention, provide stability to the reconstructed crown, and withstand masticatory forces in function. There are a variety of root posts used in pediatric dentistry. A resin composite post building up directly, alpha or omega shaped orthodontic wires, stainless steel pre fabricated posts, nickel-chromium cast posts with macro retentive elements, biological posts prepared from natural teeth from a tooth bank or reinforced fibers. The use of omega-shaped stainless orthodontic wire, although simple and inexpensive, the wire is unable to adequately adapt to the canal form, which may lead to radicular fracture on excessive masticatory forces (Usha *et al.*, 2007; Mortada, 2004). The biological posts provide excellent esthetics but requires establishment of tooth bank and stringent infection control policies. Metal posts do not meet the esthetic requirement because of their colour and may cause problems during the course of natural exfoliation. Composite posts do provide satisfying esthetics; but, there polymerization shrinkage increases risk of loss of retention and have poor loading strength. The development of the fibre-reinforced composite technology has brought a new material into the realm of metal-free adhesive esthetic dentistry. Different fiber types such as glass fibers, carbon fibers, Kevlar fibers, vectran fibers, and polyethylene fibers have been added to composite materials. Carbon fibres prevent fatigue fracture and strengthen composite materials, but they have an unesthetic dark colour. Kevlar fibres which are made of an aromatic polyamide, increase the impact strength of composites, but they are unaesthetic and hence, their use is limited. Vectran fibers are synthetic fibers made of aromatic polyesters, highly resistant to abrasion and impact strength, but not commonly used due to their high expansion (Uzun, 1999). Fibre glass composite posts

provide excellent esthetics and good retention but the main disadvantage being its high cost (Jain, 2011). Polyethylene fibres (Ribbon) has adequate translucency, ease of manipulation, decreased chair side time, improves the impact and flexural strength, modulus of elasticity of composite materials and they are almost invisible in the resinous matrix. Due to these reasons, they are the most appropriate and the best aesthetic strengtheners of composite materials (Sharma, 2013).

Eshghi *et al* treated 161 compromised primary maxillary incisors with 53 composite post restorations, 54 fiber post restorations and 54 reversed post restorations. After root canal preparation and post cementation, the tooth crown was reconstructed with composite resin and celluloid crowns (the strip crown technique). After one year of follow-up, 136 teeth were available for assessment. The retention rates of the restorations after one year were: 100% for the reverse post technique, 97.83% for fiber post and 97.73% for composite post (Alireza Eshghi *et al.*, 2013). The bonded resin composite strip crowns are very affordable method of restoring beautiful confident smiles in children where Zirconia crowns are not feasible. The technique proves simple to use, reasonable placement time, great parent and patient satisfaction, good esthetics, easy to repair, cost of materials (strip crown kit) is affordable. However, it may be easily fractured by trauma/traumatic occlusion, technique-sensitive, requires good tooth isolation, needs adequate tooth structure for retention and also patient cooperation (Steven Schwartz, 2012; Suzan Sahana, 2013).

In the results of a study conducted by Kupietzky *et al*, who assessed 112 strip crown composite restoration placed in 40 children, after a period of 18 months, reported an 88% overall retention rate, with only 12% of restorations losing some resin material, and none of the restorations being totally lost. Duhan *et al.* assessed the clinical performance of four different types of restorations: composite, strip crown, biological and composite with stainless steel band. A total of 52 primary frontal teeth were treated by these means. The check-up periods were 3, 6 and 9 months after treatment. Loss of retention was seen in composite restorations and composite restorations with stainless steel band after 3 months. After 6 months, retention loss was seen in all restoration types, except for strip crowns, in which loss was seen after 9 months (Duhan *et al.*, 2015). Careful consideration should be taken during treatment planning or decision making for placement of any space maintainer in incisor segment (Singh, 2010). The removable space maintainers cover large area of oral tissue causing irritation to ulceration. To improve patient acceptance, aesthetic functional fixed appliance is reliable (Khare *et al.*, 2013).

In the present case, minimum amount of palatal coverage is done causing no or less irritation. Banding of molars is done for improved strength instead of bonding. A similar appliance was mentioned by Jasmine and Groper, in which plastic teeth were attached to metal cleats that were soldered to the palatal wire bar instead of being attached to acrylic, as it was in our design. Although their appliance would be superior in hygiene, it may pose the risk of space developing between the teeth and the alveolus, due to an improper anterior fit or reduction of ridge height. The appliance that we used has acrylic flange design (modified ridge lap) and would not pose the above risk; and in addition, prevents the development of hyperplastic tissue created by excessive forces concentrated on a single

wire. However, lack of hygiene under the inaccessible acrylic flange may result in mucosal inflammatory disease. But, this is the most commonly used pontic design, as it fulfills most of the needs in cases involving ideal edentulous ridges. It has limited contact with the underlying ridge, i.e. only on the buccal aspect, which allows proper sanitation (Garber, 1981). The other limitations like long follow up, appliance breakage can be decreased by motivating and giving proper education to the child and their parents (Aswanth, 2014). As this appliance is cemented permanently into position, it requires minimal post-insertion adjustments. This design has an additional wire framework soldered in the anterior region, to provide additional strength and to prevent the pontics from rotating on the lingual wire. Unlike the posterior segment, the anterior segment from canine to canine appears to be stable, even after early loss of incisors, with no net loss of space between the canines (Christensen, 1994). Moreover, the intercanine growth between ages of two and four years is minimal (less than 0.5mm) and it is clinically insignificant (Scures, 1967). Changes in arch length with tooth migration generally occur after the eruption of the first permanent molar. At this time, the appliance can be removed, as it coincides with the eruption of the central incisors (Waggoner, 2001). Thus, this paper has offered several considerations for the clinicians to make when considering the placement of a fixed prosthetic appliance or rehabilitation using fibre posts and strip crowns.

## Conclusion

Currently, there are many options for rehabilitation of grossly destructed or fractured primary anterior teeth. The choice of restoration depends on various factors such as the amount of tooth structure remaining, ability to obtain adequate moisture control, child's cooperating ability, esthetic demands, and finally cost factor. A thorough knowledge about the available materials and clinical techniques help in attaining clinical success and patient satisfaction. The two treatment approaches which has been described in the above case reports, provides simple, effective and promising alternatives in restoring function and aesthetics in young children.

## REFERENCES

- Adewumi, A.O., Horton, C., Guelmann, M., Dixon-Wood, V., McGorray, S.P. 2012. Parental perception vs professional assessment of speech changes following premature loss of maxillary primary incisors. *Pediatr Dent*, 34, 295-9.
- Alireza Eshghi, Raha Kowsari-Isfahan, Maryam Khoroushi (2013) Evaluation of Three Restorative Techniques for Primary Anterior Teeth with Extensive Carious Lesions: A 1-year Clinical Study. *Journal of Dentistry for Children* 80(2): 80-87.
- AL-Omiri, M.K., Karasneh, J.A., Lynch, E. *et al.* 2009. Impacts of missing upper anterior teeth on daily living. *Int Dental J.*, 59:127-32.
- American Academ on Pediatric Dentistry (2008-2009) American Academy of Pediatrics: Policy on Early Childhood Caries (ECC): Classifications, Consequences, and Preventive Strategies. *Pediatr Dent* 30: 40-43.
- Aswanth, K.P., Asokan, S., John, B.J. 2014. Fixed functional space maintainer: A weight gainer: A case report. *J Indian Acad Dent Spec Res.*, 1:25-7.
- Chakraborty, S., Dhawan, P., Rastogi, P. 2015. Replacement of Premature Loss of Primary Anterior Teeth by Anterior Fixed Functional Space Maintainer: A Case Report. *Int J Oral Health Med Res.*, 2(2):51-52.
- Christensen, J.R., Fields, H.W. 1994. Space maintenance in the primary dentition. In: Pinkham JR, editor. *Pediatric Dentistry: Infancy through adolescence*, 2nd ed. Philadelphia: W.B. Saunders Company; 358-63.
- Cravero, J.P., Blike, G.T. 2004. Review of pediatric sedation. *Anesth Analg* 99: 1355-1364.
- Da Silva, K., Roy, B., Yoon, R.K. 2012. Early loss of primary incisors due to para-functional tendency. *N Y State Dent J.*, 78:26-30.
- Duhan, H., Pandit, I.K., Srivastava, N., Gugnani, N., Gupta, M. *et al.* 2015. Clinical comparison of various esthetic restorative options for coronal build-up of primary anterior teeth. *Dent Res J* 12(6): 574- 580.
- Garber, D.A., Rosenberg, E.S. 1981. The edentulous ridge in fixed Prosthodontics. *Compend Contin Educ Dent.*, 2:212-23.
- Jain, M., Singla, S., Bhushan, B., Kumar, S., Bhushan, A. 2011. Esthetic management of anterior primary teeth using polyethylene fibre with two different approaches. *J Indian Soc Pedod Prev Dent.*, 29:327-32.
- Jasmin, J.R., Groper, J.N. 1984. Fabrication of a more durable fixed anterior esthetic appliance. *ASDC J Dent Child.*, 51:124-7.
- Khare, V., Nayak, P.A., Khandelwal, V., Nayak, U.A. 2013. Fixed functional space maintainer: novel aesthetic approach for missing maxillary primary anterior teeth. *BMJ Case Rep*; 1-4.
- Kupietzky, A., Waggoner, W.F., Galea, J. 2003. The clinical and radiographic success of bonded resin composite strip crowns for primary incisors. *Pediatr Dent* 25(6): 577-581.
- Mannocci, F., Berteli, E., Sherriff, M., Watson, T.F., Ford, P. 2002. Three-year clinical comparison of survival of endodontically treated teeth restored with either full cast coverage or with direct composite restoration. *J Prosthet Dent.*, 88: 297-301.
- Mcdonald and Avery's. 2011. *Dentistry for the Child and Adolescent*. 9th Ed PHILADELPHIA, WB SAUNDERS; 558.
- Mehra, M., Grover, R. 2012. Glassfiber Post. An Alternative for Restoring Grossly Decayed Primary Incisors. *Int J Clin Pediatr Dent.*, 5(2):159-162.
- Mortada, A., King, N.M. 2004. A simplified technique for the restoration of severely mutilated primary anterior teeth. *J Clin Pediatr Dent.* 28(3):187-192.
- Northway, W.M., Wainright, R.L., Demirjian, A. 1984. Effects of premature loss of deciduous molars. *Angle Orthod.*, 54:295-329.
- Padma Kumari, B., Retnakumari, N. 2006. Loss of space and changes in the dental arch after premature loss of the lower primary molar: A longitudinal study. *J Indian Soc Pedod Prev Dent.*, 24:90-6.
- Rocha Rachel de Oliveira, Neves Lucimara Teixeira das, Marotti Noely Regina, Wanderley Marica Turolla, Correa Maria Salete Nahas Pires. Intracanal reinforcement fiber in pediatric dentistry: A case report. *Quintessence International* 2004; 35, 263-68.
- Scures, C.C. 1967. Report of the increase in bicanine diameter in 2 to 4-year-old children. *J Dent Child.* 34:332-35.
- Sharma, N., Passi, S., Kumar, V.V. 2013. Multidisciplinary Approach to the Rehabilitation in Management of Child with Early Childhood Caries: A Case Report. *J Clin Diagno Res.*, Oct;7(10): 2374-2375.

- Singh, B.D., Ranadheer, E. 2010. Aesthetic space maintainer — a cosmetic alternative for pediatric patients — A case report. *J Indian Dent Assoc*, 4:12.
- Slack, G.L., Jones, J.M. 1955. Psychological effect of fractured incisors. *Br Dent J*, 99:386-8.
- Steven Schwartz 2015. Full Coverage Aesthetic Restoration of Anterior Primary Teeth. Crest® Oral-B® at dentalcare.com Continuing Education Course.
- Suzan Sahana, Aron Arun Kumar Vasa, Ravichandra Sekhar 2010. Esthetic crowns for primary teeth: a review. *Annals and Essences of Dentistry* 2(2): 87-93.
- Tandon, S. 2008. Text book of pedodontics. 2nd edn. Paras Medical Publisher, 446–65.
- Usha, M., Deepak, V., Venkat, S., Gargi, M. 2007. Treatment of severely mutilated incisors: A challenge to the pedodontist. *J Indian Soc Pedod Prev Dent*, 25(Suppl): S34-6.
- Uzun, G., Hersek, N., Tincer, T.1999. Effect of five woven reinforcements on the impact and transverse strength of a denture base resin. *J. Prosthet Dent.*, 81:616-620.
- Vitale, M.C., Caprioglio, C., Matrignone, A., Marcheisu, U., Botticelli, A.R. 2004. Combined technique with polyethylene fibers and composite resins in restoration of traumatized anterior teeth. *Dent Traumatol*; 20:172-177
- Waggoner, W.F., Kupietzky, A. 2001. Anterior esthetic fixed appliances for the preschooler: considerations and a technique for placement. *Pediatr Dent.*, 23:2.

\*\*\*\*\*