



RESEARCH ARTICLE

NEURO-ENDOSCOPIC CYSTO-VENTRICULOSTOMY AND BIOPSY WITH AID OF NEURONAVIGATION IN PATIENTS WITH INTRAVENTRICULAR LESIONS IN THE 3RD VENTRICLE AND OCCLUSIVE HYDROCEPHALUS IN COMPARISON TO STEREOTACTIC TECHNIQUE: A SERIES OF 41 PATIENTS AND REVIEW OF THE LITERATURE

^{1,*}MunthirAl-Zabin; MD, PhD and ²Dieter Hellwig; MD, PhD

¹Senior Specialist Neurosurgery, Khoula Hospital, Muscat, Sultanate of Oman

²Department of Neurosurgery, University Hospital of Marburg, Germany

ARTICLE INFO

Article History:

Received 23rd March, 2017
Received in revised form
05th April, 2017
Accepted 15th May, 2017
Published online 20th June, 2017

Key words:

Neuronavigation,
Neuroendoscopy,
Minimally invasive endoscopic
neurosurgery,
Occlusive hydrocephalus,
Cystic brain lesions,
Lesions in the third ventricle,
Cerebrospinal Fluid (CSF),
Endoscopic Third Ventriculostomy (ETV).

*Corresponding author:

MunthirAl-Zabin,
Senior Specialist Neurosurgery, Khoula
Hospital, Muscat, Sultanate of Oman.

Copyright©2017, MunthirAl-Zabin and Dieter Hellwig. This is an open access article distributed under the Creative Commons Attribution License, which permits unrestricted use, distribution, and reproduction in any medium, provided the original work is properly cited.

Citation: MunthirAl-Zabin and Dieter Hellwig, 2017. "Neuro-endoscopic cysto-ventriculostomy and biopsy with aid of Neuronavigation in patients with intraventricular lesions in the 3rd ventricle and occlusive hydrocephalus in comparison to stereotactic technique: A series of 41 patients and review of the Literature", International Journal of Current Research, 9, (06), 51952-51959.

ABSTRACT

Introduction: The intracranial lesions in the third ventricle can have a variety of clinical manifestations. Masses related to the anterior recesses or floor of the third ventricle may manifest as dysfunction of the hypothalamic-pituitary hormonal axis. Masses of the posterior wall of the third ventricle, foramen of Monro masses, and intraventricular masses often manifest as hydrocephalus accompanied mostly by headaches. Some congenital cysts or acquired abnormalities, such as cavum veliinterpositi cyst and ectatic basilar artery, respectively, may be incidental imaging findings but distort the normal anatomy of the third ventricle or mimic more serious disease.

Objective: 41 Patients (24 female, 17 male, age 12-82 years) with occlusive hydrocephalus due to intraventricular processes were treated with endoscopic technique with the aid of neuro-navigation.

Methods: In these cases, the endoscopic cysto-ventriculostomy and biopsy of lesion has been selected as operative method. The neuro-navigation has been used for the optimization of the operation approach. For diseases in the region of the 3rd ventricle there are three variants: micro neurosurgery, stereotaxy, and endoscopic method. In patients with unclear diagnosis and other clinically limiting conditions the endoscopic guided method as a minimally invasive method should be selected.

Results: With the endoscopic method, the intraventricular processes could be visualized. A necessary haemostasis could be performed under direct vision. In addition to the biopsy extraction, the occlusive hydrocephalus could be also treated with this method in approximately 68.3 % of the patients. There were no significant complications or bleedings postoperatively. There was in 70-90% of the cases a reliability of histopathological diagnosis. In comparison with the stereotactic method it has the same grade of accuracy (Mennel *et al.*, 1994, Zentralblattfür Neurochirurgie). There has been no postoperative morbidity or mortality in consequence of this treatment.

Conclusions: Neuroavigation-assisted, endoscopic biopsy and cystoventriculostomy has in comparison with the stereotactic method the same grade of accuracy and reliability. It has also more advantages, such as visualization of the operation area and intraoperative treatment and avoidance of complications postoperatively, especially intracranial or intracerebral haemorrhages. The hydrocephalus can also be treated concurrently in the most cases.

INTRODUCTION

Microneurosurgical resection and / or insertion of ventriculo-peritoneal shunt were for long time the only means of treatment for patients with lesions in the site of third ventricle, such as colloid cysts. In the past few years, however, endoscopic procedures have gained increasing significance and have been used more widely. (Duffner *et al.*, 1998; Hellwig and Bauer, 1998; Hellwig and Riegel, 1998; Grotenhuis, 1998; Hellwig *et al.*, 1999; Tirakotai *et al.*, 2004; Tirakotai *et al.*,

2004; Riegel *et al.*, 2000; Schroeder and Gaab, 1999; Hellwig *et al.*, 2005; Koch *et al.*, 2004; Cinalli *et al.*, 1999; Fritsch and Mehdorn, 2002) Neuroendoscopy is a relatively new technique in neurosurgery that cannot yet be definitely judged on the basis of scientific evidence. (Duffner *et al.*, 1998; Hellwig and Bauer, 1998; Hellwig and Riegel, 1998; Grotenhuis, 1998) Large-scale, randomized controlled studies and metaanalyses are currently in progress, but no conclusive findings have yet been reported regarding the potential advantages, for various indications, of this new technique over other, established ones.

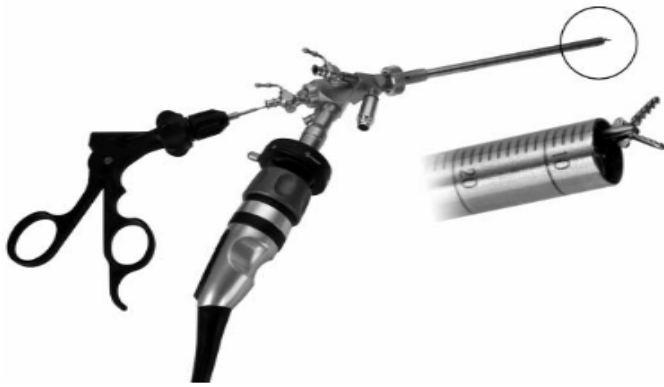

Figure 1. Hellwig-type ventriculoscope with multiple working, irrigation and aspiration channels

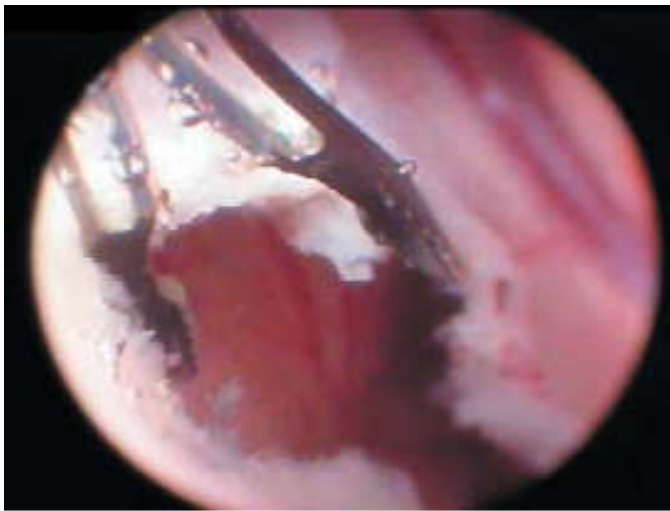

Figure 2. Intraventricular septostomy with bipolar grasping forceps (diameter 1.5 mm)

Many different types of neuroendoscope with good optical properties are now available, and little improvement seems to be needed in this area (Hellwig and Riegel, 1998; Grotenhuis, 1998; Hellwig *et al.*, 1999). A neuro-endoscope should have two working channels to enable the surgeon to work with both hands (as in conventional, non-endoscopic microsurgery), as well as a channel for irrigation and suction. A compromise must be struck, so that the parenchymal trauma due to the insertion of the device is minimized (Figures 1 & 2), while the endoscope simultaneously remains optimally manipulable for surgical purposes. The standard types of neuro-endoscopes today have a diameter of 3 to 6 mm. Diameters greater than 8 mm are not acceptable, because the use of such instruments affords no advantage over conventional microsurgery. Intraoperatively interchangeable endoscopes with different viewing angles, i.e., angulated optics, must be used to enable inspection of the operative field from a variety of perspectives (see figure 1).

A special problem may arise in neuroendoscopic procedures on neonates or infants. Large-diameter adult endoscopes should not be used in such patients, as their use promotes the development of a cerebrospinal fluid fistula to the skin along the trajectory of insertion of the endoscope through the brain parenchyma. It has been found to be safer to use pediatric endoscopes of diameter 2–3 mm with two working channels and high-quality optics. Ultra-thin endoscopes have been designed and put to use as microsurgical operating

instruments for endoscopically assisted microsurgery, e.g., as "seeing dissectors" in cerebral aneurysm surgery. Such instruments enable the neurosurgeon to see around corners in the operative field. Obviously, endoscopes that are designed for this purpose can be kept very thin, as they do not need to have any working channels (Grotenhuis, 1998; Tirakotai *et al.*, 2004; Koch *et al.*, 2004; Cinalli *et al.*, 1999; Fritsch and Mehdorn, 2002; Boschert *et al.*, 2003). Planning of the neuroendoscopic approach: The precise, three-dimensional planning of the neuroendoscopic approach, i.e., the determination of the burr hole site, approach trajectory, and target, can be carried out either with stereotactic neurosurgical technique (6) or with the aid of neuronavigation (Tirakotai *et al.*, 2004; Schroeder and Gaab, 1999; Hellwig *et al.*, 2005; Koch *et al.*, 2004; Cinalli *et al.*, 1999). The advantage of neuronavigation over stereotaxy is the surgeon's greater freedom in the manipulation of the endoscope when it does not need to be attached to a stereotactic frame. A combination of neuroendoscopy and neuronavigation is currently the operative standard (Figure 3). Neuronavigation can add useful information in the endoscopic treatment of several lesions in the third ventricle with and without occlusive hydrocephalus, especially for preoperative planning. However, entering the ventricular system is unproblematic and adequate intraoperative orientation can be acquired from the visible anatomic landmarks. So-called virtual ventriculostomy (Riegel *et al.*, 2000; Gangemi and Mascari, 1999) is a new imaging technique that is currently in the process of development. It enables three-dimensional planning of the neuroendoscopic procedures, so that they can be "performed" preoperatively in a virtual environment (Figure 4). In the present study, navigation aided neuro-endoscopic techniques will be presented along with indications and results for cysto-ventriculostomy and biopsy in patients with lesions in the 3rd ventricle with occlusive hydrocephalus in comparison to stereotactic procedures. This issue will be described and discussed in the light of the current literature. (Cinalli *et al.*, 1999; Boschert *et al.*, 2003; Tirakotai *et al.*, 2004; Guiot *et al.*, 1963; Cappabianca *et al.*, 2004; Krämer, 2002)

OBJECTIVES AND METHODS

Retrospective analysis was performed for 41 Patients (24 female, 17 male, age 12-82 years, mean 45.5 years), who were diagnosed with occlusive hydrocephalus due to intraventricular processes and were treated with endoscopic technique with the aid of the neuro-navigation at the University Hospital of Marburg/ Germany in the time from 2002 till 2010. (See table 1)

TABLE 1: CLASSIFICATION OF AGE GROUPS OF THE PATIENTS (YEARS / PERCENTAGE, %)

12-15 (PAEDIATRIC CASES)	15 / 36.6
16-30	9 / 22.0
31-50	11 / 26.8
51-65	4 / 9.7
66-82	2 / 4.9

81% of the cases showed headache as a main symptom, followed by vomiting and nausea in 36%, convulsion in 18%, dizziness / giddiness in 17%, vision deficits in 17%, gait ataxia in 6%, aphasia / dysphasia 5% and deficits of pituitary hormones in 4% of the patients. (See Table 2).

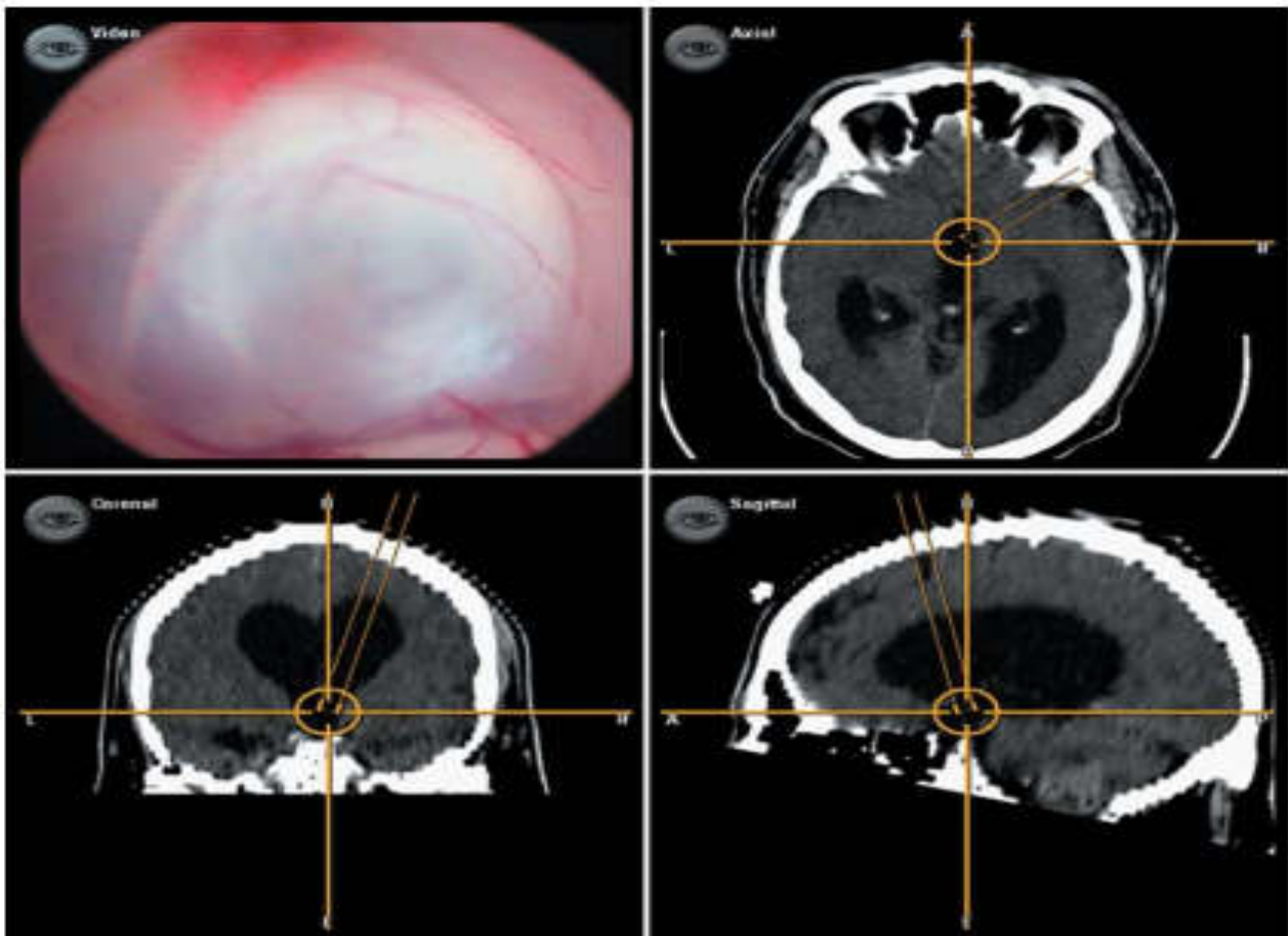


Figure 3. Navigation-assisted neuroendoscopy. Determination of the trajectory to the target and intraoperative three-dimensional check of the approach to a coloid cyst in the foramen of monro

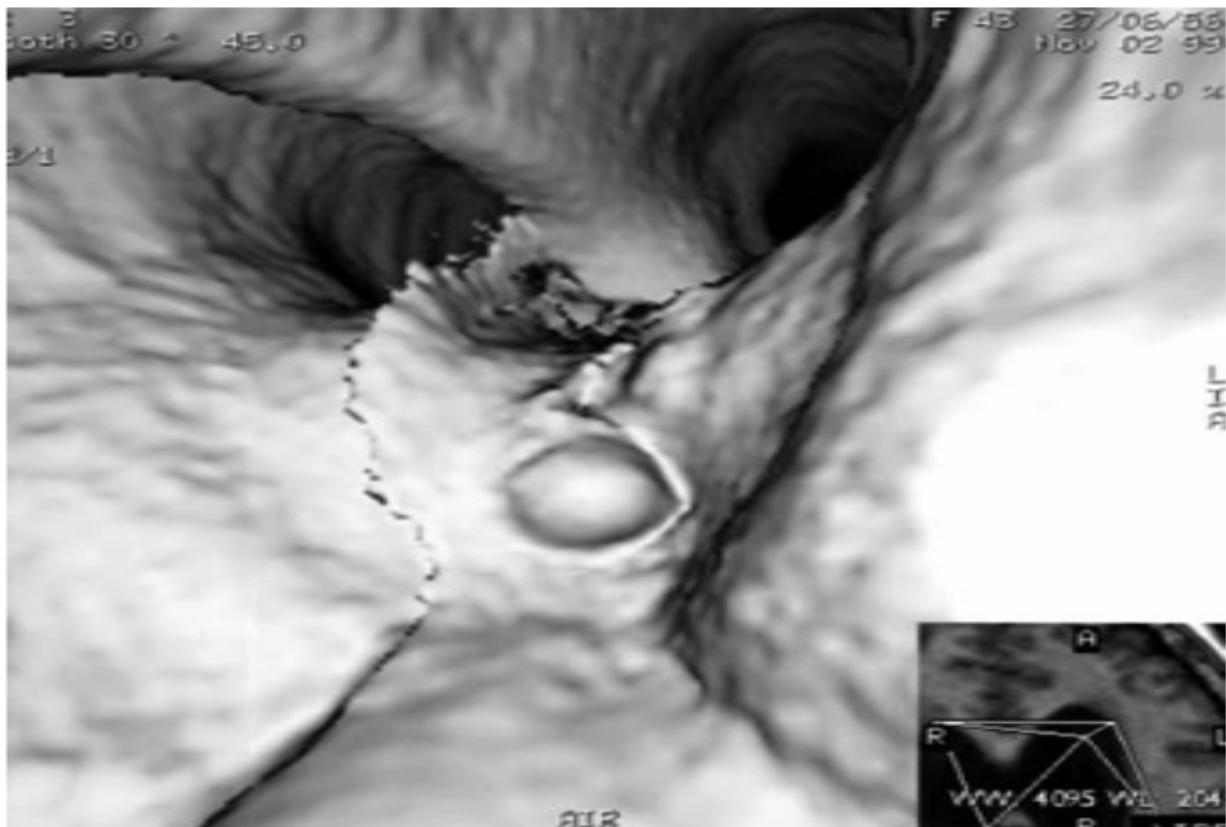


Figure 4. Preoperative imaging of the operative site with so-called virtual neuroendoscopy

TABLE 2: SYMPTOMS OF PATIENTS WITH 3RD VENTRICLE LESIONS & HYDROCEPHALUS

HEADACHE	81 %
VOMITING AND NAUSEA	36 %
CONVULSION	18 %
DIZZINESS AND GIDDINESS	17 %
VISION DEFICITS	17 %
GAIT DISTURBANCE / ATAXIA	6 %
APHASIA / DYSPHASIA	5 %
DISTURBANCES OF PITUITARY HORMONES	4 %

TABLE 3: DIAGNOSIS / NUMBER / PERCENTAGE (%) OF PATIENTS (PAEDIATRIC GROUP / 15)

GERMINOMA	8 / 53.3
PILOCYTIC ASTROCYTOMA	3 / 20.0
CRANIOPHARYNGIOMA	3 / 20.0
LANGERHANS CELL HISTOCYTOSIS	1 / 6.7

TABLE 4: DIAGNOSIS / NUMBER / PERCENTAGE OF PATIENTS (ADULT GROUP / 26)

COLLOID CYST	8 / 30.8
EPENDYMOMA	3 / 11.6
PLEXUS PAPILOMA	3 / 11.6
PINEAL CYST	3 / 11.6
CONGENITAL INTRAVENTRICULAR CYST	2 / 7.7
SUBEPENDYMOMA	2 / 7.7
LYMPHOMA	1 / 3.8
TECTAL GLIOMA	1 / 3.8
HYPOTHALAMIC HAMARTOMA	1 / 3.8
PITUITARY MACROADENOMA	1 / 3.8
SELLAR MENINGIOMA	1 / 3.8

The follow up period was approximately 3-5 years for all the patients, where as some of the patients have continued or completed the postoperative treatment in another neurosurgical centres. (See Tables 1- 4)

RESULTS

In the paediatric group, all the eight patients with germinoma, two patients with pilocytic astrocytoma and one patient with craniopharyngeoma have required postoperatively no CSF diversion, as the occlusive hydrocephalus was treated endoscopically. In the adult group it was a successful treatment of the occlusive hydrocephalus as well in seven patients with colloid cyst, two patients with ependymoma, two patients with

plexus papilloma, two patients with pineal cyst, all the two patients with the congenital intraventricular cyst, one patient with lymphoma and one patient with subependymoma. All together calculated, the success rate for treatment of the occlusive hydrocephalus was 68.3% (28 patients out of 41). There was a reliability of the histopathological diagnosis in 70-90% of the operated patients, which was performed by two neuropathologists. In comparison with the stereotactic method it has the same grade of accuracy (Mennel *et al.*, 1994, Zentralblatt für Neurochirurgie, Germany). There has been no morbidity or mortality postoperatively in consequence of this treatment. There were no postoperative complications or bleedings, as the patients were kept postoperatively for at least one day on the ICU and then for more 5-7 days as inpatients,

until the final histopathologic evaluation and diagnosis was achieved and confirmed. Further surgical procedures, chemotherapy and /or radiation therapy were required postoperatively in some patients according to the diagnosis. From the paediatric group, 1 patient and from the adult group 2 patients continued the treatment in another neurosurgical centres.

DISCUSSION

In the last few years, the indications for neuroendoscopic operations have been standardized. Generally, neuroendoscopy is used for procedures in preexisting or pathologically formed cavities in the central and in the peripheral nervous system as well (Schroeder and Gaab, 1999; Schroeder *et al.*, 2004; Tirakotai *et al.*, 2004; Krämer, 2002; Yeung and Yeung, 2003; Perez-Cruet *et al.*, 2002; Brueser and Larkin, 1998). In the treatment of hydrocephalus, neuroendoscopic techniques can be used to reconstitute or recreate the natural pathways of cerebrospinal fluid (CSF) flow, and thereby to obviate the need for the insertion of a shunt system (foreign body in the brain). Endoscopic third ventriculostomy (ETV) has come to new life as a concept for the treatment of occlusive hydrocephalus (Hellwig *et al.*, 2005; Fritsch and Mehdorn, 2002) because of the complications commonly associated with the implantation of shunts to treat hydrocephalus, including shunt malfunction, thrombosis, infection, overdrainage, and slit-ventricle syndrome. In occlusive hydrocephalus, the CSF resorption mechanisms remain intact, and "internal shunt methods" such as ventriculostomy can, therefore, be used (see the box below).

Recent publications (Hellwig *et al.*, 2005; Cinalli *et al.*, 1999; Fritsch and Mehdorn, 2002; Boschert *et al.*, 2003; Schroeder *et al.*, 2004; Gangemi and Mascari, 1999; Hellwig *et al.*, 2003; Tirakotai *et al.*, 2004; Cappabianca *et al.*, 2004; Krämer, 2002; Brueser and Larkin, 1998; Bauer, 1998) have shown that patients whose hydrocephalus has been treated with shunts and who have suffered multiple episodes of shunt malfunction can be successfully treated with neuroendoscopy, so that they can do without a shunt from then onward. Patients considered to be at elevated risk of complications from surgical shunt revision, including those with post-hemorrhagic and post-meningitic hydrocephalus (Boschert *et al.*, 2003), should have an endoscopic procedure instead of insertion of Shunt device. Since the advent of endoscopy, the old clinical rule "once a shunt, always a shunt" thankfully no longer applies. In special cases of aqueductal stenosis, particularly when there is an isolated fourth ventricle, a so-called aqueductoplasty can be performed. In this procedure, the pathway of CSF flow is reconstituted by the endoscopic insertion of a stent from the third to the fourth ventricle, and the implantation of a shunt is thereby avoided. Aqueductoplasty is thus an alternative to ventriculoplasty when the latter would be technically difficult (Schroeder *et al.*, 2004; Gangemi and Mascari, 1999; Hellwig *et al.*, 2003). Not all types of hydrocephalus are amenable to neuroendoscopic treatment. There is as of yet no predictive test for the success of endoscopic ventriculostomy. The best outcomes to date have been documented for occlusive hydrocephalus due to tumor-associated aqueductal stenosis or fourth ventricular displacement, followed by idiopathic aqueductal stenosis.

BOX

Facts on the neuroendoscopic treatment of hydrocephalus

- A stoma in the floor of the third ventricle should be between 4 and 6 mm in diameter, depending on the anatomical situation.
- The rate of closure of ventricular stomata is ca. 2%. A closed stoma can often be reopened in a second endoscopic procedure (11).
- The long-term success rate of third ventriculostomy (i.e., shunt independence) lies between 70% and 90% (12).
- The morbidity and mortality of neuroendoscopic treatment, and the rate of stoma closure, are no higher in infants and young children than in adults. The etiology of hydrocephalus is the most important factor guiding the decision to treat with neuroendoscopy. In occlusive hydrocephalus, third ventriculostomy is always indicated (13).
- Patients who were initially treated with a shunt and subsequently had multiple shunt-related complications can be treated with neuroendoscopy.

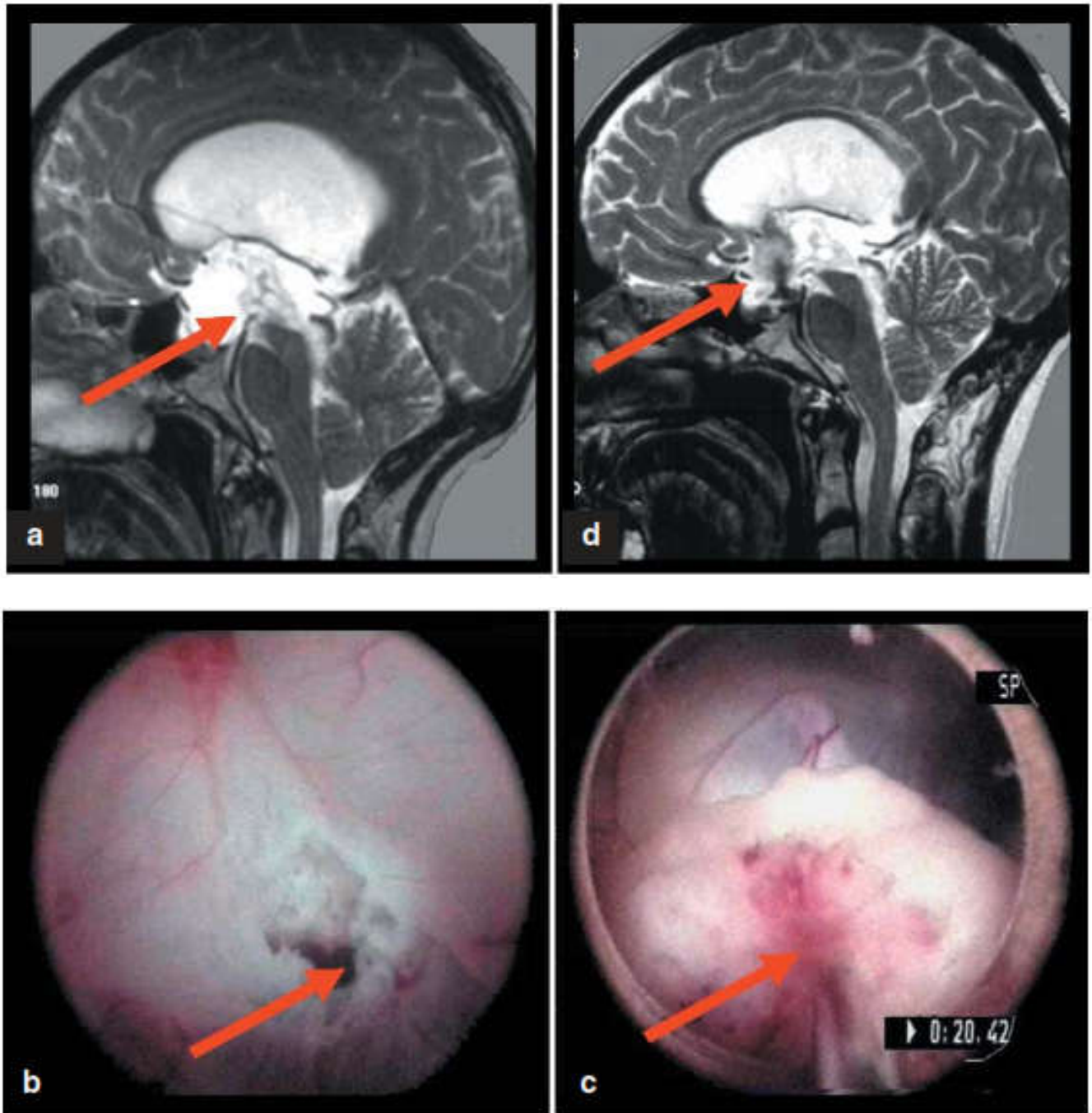


Figure 5: Low-grade astrocytoma in the posterior portion of the third ventricle.

- (a) The T2-weighted preoperative MRI scan shows that the tumor is causing obstructive hydrocephalus;
 (b) Endoscopic biopsy of the tumor;
 (c) Immediately after biopsy, a third ventriculostomy is performed to treat the occlusive hydrocephalus;
 (d) The postoperative MRI shows a prominent flow void at the floor of the third ventricle, indicating flow of CSF into the interpeduncular fossa.

The success rate in post-meningitic and post-hemorrhagichydrocephalus markedly lower, as it is, too, in normal-pressurehydrocephalus (NPH). Gangemi *et al.* (1999) treated 25 NPH patients with endoscopic third ventriculostomy and achieved a success rate of 72%; in particular, these patients' gait disturbance was improved. Intracranial cysts are particularly suitable for neuroendoscopic treatment. Colloid, arachnoid, and pineal cysts can be endoscopically aspirated and fenestrated or removed. For the treatment of cystic craniopharyngiomas, dysontogenetic tumors, gliomas, and metastases, neuroendoscopy can be used in combination with

microsurgical resection, radiotherapy, and adjuvant chemotherapy. Because of their intraventricular location, colloid cysts are a classic indication forneuroendoscopy (Hellwig *et al.*, 2003). Patients with symptoms of occlusive hydrocephalus are treated operatively. For asymptomatic patients, an operation is indicated when the cyst is large enough to threaten an acute occlusion of the foramen of Monro, which would cause acute occlusive hydrocephalus. A preventive operation is justified in view of the reports of sudden death in previously asymptomatic patients with colloid cysts (Kavalar *et al.*, 2005; Brueser and Larkin, 1998; Bauer, 1998).

The postoperative results of neuroendoscopic surgery for colloid cysts are at least as good as those of microsurgery in terms of morbidity, mortality, and recurrence rates (Hellwig *et al.*, 1998; Hellwig *et al.*, 1999; Tirakotai *et al.*, 2004; Schroeder 1999; Hellwig *et al.*, 2005; Koch *et al.*, 2004; Cinall *et al.*, 1999; Fritsch and Mehdorn, 2002; Boschert *et al.*, 2003, Gangemi and Mascari, 1999; Hellwig *et al.*, 2003; Kavalari *et al.*, 2005 Tirakotai *et al.*, 2004; Guiot *et al.*, 1963; Krämer, 2002; Yeung and Yeung, 2003; Perez-Cruet *et al.*, 2002; Brueser and Larkin, 1998). Arachnoid cysts can be found intracranially at many different sites. Most of these cysts are large cavities in the immediate vicinity of the ventricular system or the intracranial cisterns and are therefore well suited to a neuroendoscopic approach. This is particularly true of so-called suprasellar arachnoid cysts. An operation is indicated when the arachnoid cyst is symptomatic, i.e., when it elevates the intracranial pressure, causing headache or other neurological symptoms and signs (Tirakotai *et al.*, 2004; Guiot *et al.*, 1963; Cappabianca *et al.*, 2004; Krämer, 2002). Neuroendoscopy can be used alone or in combination with conventional microsurgery. The postoperative results of endoscopic surgery for arachnoid cysts are comparable to those of conventional microsurgery. Approximately 75% of patients benefit from the operation. A reduction of cyst size is not a prerequisite for clinical improvement. The most important factor is the linkage of the cyst to the draining CSF pathways so that the intracranial pressure can be normalized. Solid intraventricular tumors, too, can be treated neuroendoscopically.

Such tumors are preferably biopsied with neuroendoscopic guidance, rather than "blindly" by stereotaxy. Biopsy under direct vision is particularly advantageous in the area of the foramen of Monro, as well as for pineal tumors in the posterior portion of the third ventricle. The operative approach can be chosen to spare ventricular vessels and functionally important structures, because endoscopy, unlike stereotaxy, offers the neurosurgeon a direct visual check, especially if the procedure is aided by neuro-navigation. If the tumor is causing occlusive hydrocephalus (e.g., because of its location in the posterior portion of the third ventricle), a third ventriculostomy can be performed at the same sitting, or, alternatively, a stent can be inserted between a lateral ventricle and the third ventricle, or between the third and fourth ventricles (Figure 5). The likelihood of complete tumor resection via neuroendoscopic surgery is a function of tumor size. Neuroendoscopy is excessively time-consuming if the tumor exceeds 2 cm in diameter. Regarding the endoscopic pituitary surgery, Guiot, in 1962, was the first to use an endoscope in pituitary surgery (Guiot *et al.*, 1963). In recent years, the use of endoscopy in adenoma resection has markedly increased but has not yet become standard. The operative approach is simple and fast and has few complications. Adequate instrumentation is available to allow the neurosurgeon to work effectively through a narrow opening, whereas the neuronavigation can be a useful aid in these procedures. It is important, however, that the neurosurgeon performing endoscopic pituitary surgery should also be well-versed in conventional trans-sphenoidal trans-nasalmicro surgery, so that he or she can switch to the other technique if anatomical or other technical difficulties are encountered. The endoscopic pituitary surgery is associated with shorter operative time, reduced operative trauma, relatively low rate of intra- and post-operative complications and a shorter postoperative period of bed rest for the patients. (Tirakotai *et al.*, 2004; Koch *et al.*, 2004; Boschert *et al.*, 2003;

Gangemi and Mascari, 1999; Hellwig *et al.*, 2003; Kavalari *et al.*, 2005; Cappabianca *et al.*, 2004; Yeung and Yeung, 2003; Brueser and Larkin, 1998). Most congenital malformations of the third ventricle are rare. The most common paediatric malformation is abnormal ventricular dilatation (hydrocephalus) due to aqueductal stenosis. A wide variety of pathologic processes may secondarily involve or arise in the third ventricle. To create a useful radiologic differential diagnosis, it is helpful to separate these lesions by their anatomic relationship to the ventricle while also considering the age of the patient. The most commonly found pathologic processes are related to the anterior recesses of the third ventricle and are of sellar-suprasellar or hypothalamic-chiasmatic origin. Lesions deforming the posterior aspect of the third ventricle most commonly arise from the pineal gland, although tectal plate and inferior thalamic masses may obstruct the aqueduct, resulting in dilatation of the third ventricle. Lesions may arise in the floor of the third ventricle, such as hypothalamic hamartoma, or be extrinsic masses elevating the floor. The most common mass of the foramen of Monro is a benign colloid cyst. Most intraventricular masses are lesions arising in or metastatic to the choroid plexus. MR imaging is recommended to best delineate the entire extent of a lesion involving the third ventricle and to further characterize it. To this end, sagittal MR imaging is often the most useful in determining from which direction a mass involves the third ventricle. (Kavalari *et al.*, 2005; Tirakotai *et al.*, 2004; Guiot *et al.*, 1963; Cappabianca *et al.*, 2004; Krämer, 2002; Yeung and Yeung, 2003; Perez-Cruet *et al.*, 2002; Brueser and Larkin, 1998; Bauer, 1998)

Conclusion

The procedure of neuronavigation-assisted, endoscopic biopsy and cystoventriculostomy has in comparison with the stereotactic method the same grade of accuracy and reliability. But it has also more advantages, such as visualization of the operation area and avoiding of complications intra- and postoperatively. The occlusive hydrocephalus can also be treated concurrently in the most cases. Neuroendoscopy is a recognized technique in the neurosurgery for the treatment of many different lesions affecting the nervous system, which has been significantly improved and developed in the last years.

REFERENCES

- Boschert, J., Hellwig, D. and Krauss, J.K. 2003. Endoscopic third ventriculostomy for shunt dysfunction in occlusive hydrocephalus: long-term follow-up and review. *J Neurosurg*, 98:1032–9.
- Brueser, P. and Larkin, G. 1998. The dilemma of treating carpal tunnel syndrome: open versus endoscopic release. In: Hellwig D, Bauer BL eds.: Minimally invasive techniques for neurosurgery. Current status and future perspectives. Berlin, Heidelberg, New York: Springer Verlag, 167–71.
- Cappabianca, P., Cavallo, L.M. and de Divitiis, E. 2004. Endoscopic endonasal transsphenoidal surgery. *Neurosurgery*, 55(4): 933–940.
- Cinalli, G., Sainte-Rose, C., Chumas, P., Zerah, M., Brunelle, R. and Lot, G. 1999. Failure of third ventriculostomy in the treatment of aqueductal stenosis in children. *J. Neurosurg*, 90:448–54.
- Duffner, F., Freudenstein D., Wacker, A. *et al.* 75 Jahre nach Dandy, Fay und Mixter – Ein Rückblick auf die Geschichte der Neuroendoskopie. *Zentralblatt Neurochir*, 1998; 59: 121–8.

- Fritsch, M.J. and Mehdorn, M. 2002. Endoscopic intraventricular surgery for treatment of hydrocephalus and loculated CSF space in children less than one year of age. *Pediatr Neurosurg.*, 36:183–8.
- Gangemi U, Mascari C: Endoscopic third ventriculostomy in idiopathic normal pressure hydrocephalus. *Neurosurgery* 1999; 42:128–32.
- Grotenhuis, J.A. ed. 1998. Endoscope-Assisted Microneurosurgery. A Concise Guidebook. Nijmegen: Uitgeverij Machaon, 33–6.
- Guiot, G., Rougerie, J., Fourester, M. and Fournier, A. 1963. Une nouvelle technique endoscopique: Explorations endoscopiques intracrâniennes. *Presse Med.*, 1225–8.
- Hellwig, D., Bauer, B.L. eds. 1998. Minimally invasive techniques for Neurosurgery. Berlin, Heidelberg, New York: Springer 1998; 7–35.
- Hellwig, D., Bauer, B.L., Schulte, D., Gatscher, S., Riegel, T., Bertalanffy, H. 2003. Neuroendoscopic treatment for colloid cysts of the third ventricle: the experience of a decade. *Neurosurgery*, 52:525–32.
- Hellwig, D., Grotenhuis, J.A., Tirakotai, W., Riegel, T., Schulte, D.M., Bauer, B.L., Bertalanffy, H. 2005. Endoscopic third ventriculostomy for obstructive hydrocephalus. *Neurosurg Rev.*, 28:12–34.
- Hellwig, D., Haag, R., Bartel, V., Riegel, T., Eggers, F., Becker, R. and Bertalanffy, H. 1999. Applications of new electro-surgical devices and probes in endoscopic neurosurgery. *Neurol Res.*, 21:67–72.
- Hellwig, D., Riegel, T., Bertalanffy, H. 1998. Neuroendoscopic techniques in treatment of intracranial lesions. *Minim Invasive Ther Allied Technol.*, 7:123–35.
- Kavalar, M.S., Kavalar, R., Strojnik, T. 2005. A colloid cyst of the third ventricle – the cause of episodic headache and sudden unexpected death in an adolescent girl. *Wiener Klin Wochenschr.*, 117(23–24):837–40.
- Koch, D., Grunert, P., Philippi, R. and Hopf, N. 2004. Re-ventriculostomy for treatment of obstructive hydrocephalus in cases of stoma dysfunction. *Minim Invasive Neurosurg*, 20:405–11.
- Krämer, J. 2002. Behandlung lumbaler Wirbelsäulenprobleme. *DtschArztebl*, 99(A):1510–6.
- Perez-Cruet, M.J., Foley, K.T., Isaacs, R.E., Rice-Wyllie, L., Wellington, R., Smith, M.M. and Fessler, R.G. 2002. Microendoscopic discectomy: technical note. *Neurosurgery*, 51(Suppl.2):129–35.
- Riegel, T., Alberti, O., Retsch, R., Shiratori, V., Hellwig, D., Bertalanffy, H. 2000. Relationships of virtual reality neuroendoscopic simulations to actual imaging. *Minim Invasive Neurosurg*, 43:176–80.
- Schroeder, H.W.S., Gaab, M.R. 1999. Intracranial endoscopy. *Neurosurg Focus*, 6:1–11.
- Schroeder, H.W.S., Oertel, J., Gaab, M.R.: Endoscopic aqueductoplasty in the treatment of aqueductal stenosis. *Childs Nerv Syst* 2004; 20:821–7.
- Tirakotai, W., Bozinov, O., Sure, U., Riegel, T., Bertalanffy, H. and Hellwig, D. 2004. Evolution of stereotactic guidance in neuroendoscopy. *Childs Nerv Syst.*, 20:790–5.
- Tirakotai, W., Riegel, T., Sure, U., Bozinov, O., Hellwig, D. and Bertalanffy, H. 2004. Clinical application of neuronavigation in a series of single burr hole procedures. *Zentralbl. Neurochir.*, 65:57–64.
- Tirakotai, W., Schulte, D.M., Bauer, B.L. and Hellwig, D. 2004. Neuroendoscopic surgery of intracranial cysts in adults. *Childs Nerv Syst.*, 20:842–51.
- Yeung, A.T. and Yeung, C.A. 2003. Advances in endoscopic disc and spine surgery: Foraminal approach, 11:255–23.
