



## RESEARCH ARTICLE

### A MORPHOMETRIC ANALYSIS ON LOCATION OF MANDIBULAR FORAMEN OF SOUTH INDIAN POPULATION

\*Radhika Kuttan, Deborah Joy Hephzibah, T., Dr. Manicka Vasuki, Dr. Jamuna, M.  
and Dr. Gnanapoongothai

Department of Anatomy, PSG Institute of Medical Sciences and Research, Peelamedu, Coimbatore,  
Tamilnadu, India

#### ARTICLE INFO

##### Article History:

Received 03<sup>rd</sup> March, 2017  
Received in revised form  
29<sup>th</sup> April, 2017  
Accepted 12<sup>th</sup> May, 2017  
Published online 30<sup>th</sup> June, 2017

##### Key words:

MF- Mandibular foramen, AB- Anterior border, PB- Posterior border, AG- Gonial angle.

#### ABSTRACT

The aim of the study is to locate the mandibular foramen, from various anatomical landmarks in 35 adult dry human mandibles of 70 sides. The mandible with permanent dentitions of unknown sex from a south Indian population was chosen for the study. The distances were measured by using Digital Vernier Caliper and were statistically analyzed. It was found that the mean value and the standard deviation of the various distances were; from the MF to AB were  $18.23 \pm 1.91$  on (R) and  $17.8 \pm 2.6$  on (L) side. From MF to PB was  $13.49 \pm 1.9$  on (R) and  $14.2 \pm 2$  on (L) side and the distance from MF to AG was been  $20.6 \pm 3.3$  on (R) and  $21 \pm 3$  on (L). The distance between AB to PB were  $31.2 \pm 2.8$  on (R) and  $31.6 \pm 3.37$  on (L). Mandibular foramen is an important landmark for the several dental approaches like inferior alveolar nerve block, as well for the mandibular osteotomies. Hence the Knowledge of the current study of location of MF ensures guidance to the maxillofacial and dental surgeons.

Copyright©2017, Radhika Kuttan et al. This is an open access article distributed under the Creative Commons Attribution License, which permits unrestricted use, distribution, and reproduction in any medium, provided the original work is properly cited.

Citation: Radhika Kuttan, Deborah Joy Hephzibah, T., Dr. Manicka Vasuki, Dr. Jamuna, M. and Dr. Gnanapoongothai, 2017. "A morphometric analysis on location of mandibular foramen of south Indian population, 9, (06), 52763-52765.

#### INTRODUCTION

The mandible is the strongest bone and forms the lower jaw of the face. It has a curved body which is convex forwards, and two rami that ascends posteriorly. The mandibular ramus is quadrilateral and two surfaces lateral and medial and four borders namely superior, inferior, anterior and posterior. Mandibular foramen is located on the medial surface which leads into the mandibular canal through which the inferior alveolar nerve passes through it (Datta 4<sup>th</sup> edition). The junction between lower and posterior border forms the angle of the mandible which usually measures about  $110^{\circ}$ - $115^{\circ}$  in adults. The anterior border is continuous with coronoid process and the posterior border is thick and rounded and becomes overlapped by the parotid gland. For a successful inferior alveolar nerve block, the distance of the MF from AB and PB is essential and is important to look for MF in vertical plane from the mandibular condyle to its inferior border (Thangavel et al., 2012). On a study of mean distance of MF which was conducted on panoramic radiographic tracing, it was found MF was not at the centre of the ramus in the horizontal plane but it was located 2.69 mm posterior and

3.4mm inferior to the midpoint of the ramus (Asma Saher Ansari et al., 2015). However many studies shows the significance of MF from various anatomical landmarks the present morphometric study provide further information for the dental practioners.

#### MATERIALS AND METHODS

The present study was carried on 35 dry human mandibles with a total of 70 sides, of unknown sex present with permanent dentitions of south Indian population. It was obtained from Department of Anatomy Bone Bank, P.S.G.Institute of Medical Sciences and Research followed by the Institutional Ethical Clearance, proposal No 17/ 057. Edentulous mandible, distorted and deformity bones were excluded from the study. Mandibles with III<sup>rd</sup> molar teeth were chosen. Various distances were measured on both sides by using Digital Vernier caliper and have been checked for its accuracy regularly during the data collection. Lowest limit of the MF (b) on the medial surface was taken as the reference point. Distance between lowest point of MF to AB (a-b), and from MF to the PB (b-d) on the medial side of the ramus of the mandible was measured. Distances from lowest point of MF to AG (b-c) and the distance from AB to PB (a-d) were also measured (Fig1). Average, standard deviation, minimum

\*Corresponding author: Radhika Kuttan,  
Department of Anatomy, PSG Institute of Medical Sciences and Research,  
Peelamedu, Coimbatore, Tamilnadu, India.

and maximum values of different distances were calculated for both right and left sides (Table 1), (Table 2).

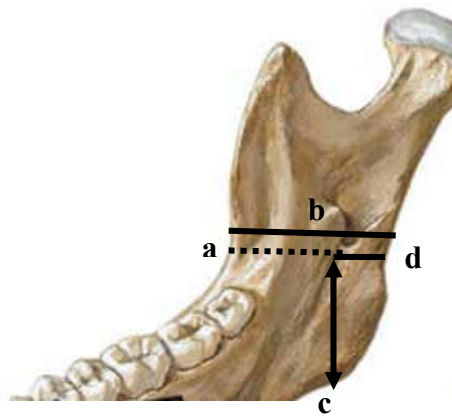


Figure 1. Location of mandibular foramen from various landmarks

Table 1. Location of MF to the anatomical landmarks like AB and PB of the mandible

	MF TO AB		MF TO PB	
	R	L	R	L
ST DEV	1.91	2.6	1.9	2.03
MAX(mm)	23.32	23.11	17.5	18.35
MIN(mm)	14.10	11.2	10.43	11.07
AVERAGE(mm)	18.23	17.8	13.5	14.2

Table 2. Location of MF to AG and distance between AB TO PB of mandible

	MF TO AG		AB TO PB	
	R	L	R	L
ST DEV	3.1	3.1	2.81	3.4
MAX(mm)	30.62	28.1	39.48	40.47
MIN(mm)	15.4	15.88	24.5	25.5
AVERAGE (mm)	20.7	21.1	31.3	31.63

Table 3. Comparison of location of MF with other authors (Asma Saher Ansari et al., 2015; Gopalakrishna et al., 2016; Prajna Paramita Samanta and Poonam Kharb, 2013; Varsha shenoy et al., 2012)

Authors	MF TO AB		MF TO PB		MF TO AG		AB TO PB	
	R	L	R	L	R	L	R	L
Gopala Krishna et al	14.63±3.6	15.31±3.1	12.34±3.10	13.51±3.92	22.14±3.18	22.1±4.12	-	-
Prajna paramita samanta et al	15.72±2.92	16.23±2.88	13.29±1.74	12.73±2.04	21.54±2.92	21.13±3.43	-	-
Varsha shenoy et al	16.1	16.3	11.7	11.3	-	-	-	-
Asma saher et al	17.69±0.61	17.65±0.63	12.03±1.02	11.84±0.7	-	-	29.64±1.2	28.97±2.6
Ennes et al	14.6	14.6	12.1	12.3	18.8	19.4	29.2	29.4
Present study	18.23±1.91	17.88±2.6	13.5±1.9	14.22±2.03	20.7±3.1	21.1±3.1	31.3±2.81	31.63±3.4

## RESULTS

A total of 35 dry human mandibles of 70 sides with unknown sex were studied for the location of MF from the various anatomical landmarks. Values of mean, minimum, maximum and standard deviation values have been represented in (Table 1) and (Table 2). The result shows that average value from the distance of MF to AB was 18.23±1.9 mm on (R) side and 17.8±2.6 mm on (L) side. From MF to PB the distance was 13.5±1.9 mm on (R) and 14.22±2.03 mm on (L). The mean distance from MF to AG was 20.7±3.1mm on (R) side and

21.1±3.1mm (L) side. The distance between AB to PB was 31.3±2.81mm on (R) and (L) was 31.63±3.4mm.

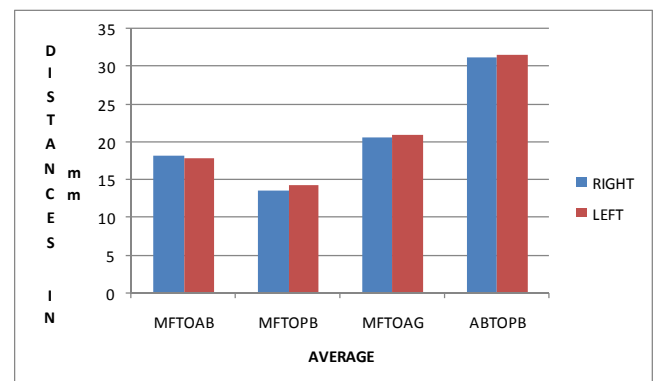


Figure 2. Bar diagram showing comparison of mean values of right and left sides and left sides

## DISCUSSION

The knowledge of location of mandibular foramen on the ramus is important for the dental practioners for an effective mandibular nerve block. In this study location of mandibular foramen from various landmarks of south Indian population were performed and correlated with other studies (Table 3). T. Thangavelu et al found that the MF was positioned to AB about 19±2.34mm (Thangavel et al., 2012). On a cross sectional study using panoramic radiographs of Pakistani individuals by Asma Saher Ansari et al from both gender. The mean distance from AB to MF was 17.69±0.61mm on (R) 17.65±0.68mm on (L) in female. 17.55±0.68 (R), 17.56±0.81mm (L) in males. MF to PB was 12.03±0.2mm(R) and 11.84±0.70mm (L) in females and 12.66±1.23mm(R), 12.52±1.84mm (L) in males. Mean AP diameter was 30.27 mm (Asma Saher Ansari et al., 2015). There was a correlation with our present study (Table 3). According to Gopalakrishna .k. et al the average distance of MF to AB was 14.63±3.16mm (R) and 15.31±3.11mm (L) and from MF to PB was 12.34±3.10mm(R) and 13.51±3.92 on (L), MF to AG is 22.14±3.18mm(R) and 22.1±4.12mm (L) (Gopalakrishna et al.,

2016). Prajna Paranita Samantha et al stated that distance between MF to AB was 15.72±2.92mm on (R) and 16.23±2.88mm on (L). MF to PB were 13.29±1.74mm on (R) AND 12.73±2.04mm on (L). MF to AG was 21.53(R) and 21.13mm on (L). The measurements from anterior to posterior border were not measured by them (Prajna Paramita Samanta and Poonam Kharb, 2013). Varsha Shenoy et al identified that distance from AB-MF was 16.1mm on the (R), 16.3mm on the (L), and from MF-PB was 11.7mm (R) and 11.3mm (L), AB-PB was 30.72mm on (R) and 30.72mm on (L) side (Varsha Shenoy et al., 2012). The present study has a similarity of

mean values. According to Ennis. J.P. Medeiros *et al* the distance from AB to MF was 14.6mm on (R) and 14.69mm (L), MF to PB was 12.1mm (R) 12.3mm (L) and AB-PB were 29.2mm (R), 29.4mm (L) (Ennis *et al.*, 2009). Shailendra singh *et al* found that the MF to angle of the mandible was 22.78±4.05mm (Shailendra Singh *et al.*, 2015).

### Conclusion

It has been concluded that the results were very closely approximated with other studies; there is a bilateral symmetry in the values on right and left sides of the same mandible. Therefore the awareness of location of MF on the ramus from various points of the mandible is necessary before any surgical approaches to the mandible and other reconstructive studies.

### REFERENCES

- Asma Saher Ansari *et al.* 2015. Localization of mandibular foramen on the panoramic radiographs, *J Ayub med Coll Abbottabad.*, 27(3):576-579.
- Datta, A.K. Essentials of Human Anatomy Head and Neck. 4<sup>th</sup> edition Calcutta, Pg 42.
- Ennis .J.P. Medeiros *et al.* 2009. Localization of mandibular foramen and clinical implications, *Int. J. Morphology*, 27(4): 1305-0311.
- Gopalakrishna .K, Deepalakshmi. S. *et al.* 2016. An Anatomical Study on the Position of Mandibular Foramen in 100 Dry Mandibles, *Int J Anat Res.*, 4(1):1967-71.
- Prajna Paramita Samanta and Poonam Kharb, 2013. Morphometric Analysis of a Mandibular Foramen and Incidence of Accessory Mandibular Foramen in Adult Human Mandibles of an Indian population, *Rev Arg de Anat Clin.*, 5(2): 60-66.
- Shailendra Singh Suniti Raj Mishra *et al.* 2015. Location of Mandibular Foramen in Correlation with the Gonial Angle in Indian population, A Morphometric Study for Surgical practices, *Int J Anat Res.*, 3(3):1345-50.
- Thangavel, T., R. Kannan *et al.* 2012. Significance of location of Mandibular Foramen in an Inferior alveolar nerve block, *Journal of Natural Science, Biology and Medicine*, 3(2):156-160.
- Varsha Shenoy *et al.* 2012. Osteometric analysis of the mandibular foramen in dry human mandibles, *JCDR*, 6(4): 557-560.

\*\*\*\*\*