



RESEARCH ARTICLE

CLINICORADIOLOGICAL EVALUATION OF CERVICAL SPINE LOCKING PLATE IN CERVICAL SPINE INJURIES (A PROSPECTIVE AND RETROSPECTIVE STUDY)

*Dr. Sandeep Kumar, Dr. Sangam Garg, Dr. Prabhnoor Singh Hayer and Dr. Shreyash Yadav

Department of Orthopedics SRHU Swami Rama Nagar Dehradun, India

ARTICLE INFO

Article History:

Received 29th May, 2017
Received in revised form
15th June, 2017
Accepted 23rd July, 2017
Published online 31st August, 2017

Key words:

Subluxation,
Dislocation,
Discectomy,
Facetectomy,
Corpectomy.

ABSTRACT

Background Context: Restoration of spinal cord function after injury remains a major challenge to those treating paralyzed victims. While prevention and treatment of secondary cord damage continues to be a primary objective, the ability to reverse established cord dysfunction is a major goal.

Purpose: Clinical and radiological evaluation of results of Cervical Spine Locking Plate in prospective and retrospective cases of lower cervical spine injuries.

Study Design/Setting: It is a prospective as well as retrospective study.

Patient Sample: Study was conducted prospectively on 28 patients and retrospectively on 20 patients making total of 48 patients.

Methods: After meeting all the criteria's patients were enrolled into the study and assessed clinically and radiologically and were taken up for surgery. Postoperatively patients were clinico-radiologically evaluated and followed and outcome was analyzed statistically.

Results: There was statistically significant neurological recovery in most of the patients.

Conclusions: Decompression of the spinal cord and stabilization with anterior cervical plates prevents the further damage to spinal cord, allows early mobility in neurological intact patients and rehabilitation becomes easy in patients having neurological deficit.

Copyright©2017, Dr. Sandeep Kumar et al. This is an open access article distributed under the Creative Commons Attribution License, which permits unrestricted use, distribution, and reproduction in any medium, provided the original work is properly cited.

Citation: Dr. Sandeep Kumar, Dr. Sangam Garg, Dr. Prabhnoor Singh Hayer and Dr. Shreyash Yadav, 2017. "Clinicoradiological evaluation of cervical spine locking plate in cervical spine injuries (A prospective and retrospective study)", *International Journal of Current Research*, 9, (08), 56543-56545.

INTRODUCTION

Incidence of cervical spine injury varies from two to six percent in blunt trauma patients. (Alexander R. Vaccaro, 2001) The annual incidence rate was 64/100,000 with two peaks, one in the second and third decade of the male population and another in elderly females. (Sekhon and Fehlings, 2001) Injuries to cervical spine produces neurological damage in approximately 40% of patients. (Goodrich and Thad, 2005) Restoration of spinal cord function after injury remains a major challenge to those treating paralyzed victims. While prevention and treatment of secondary cord damage continues to be a primary objective, the ability to reverse established cord dysfunction is a major goal. (Goodrich and Thad, 2005) Cervical spine injuries can be stabilized through anterior or posterior approach depending upon the pattern of injury. Posterior stabilization usually is indicated for posterior ligamentous instability. Anterior decompression and fusion with or without internal fixation are most often indicated for burst fracture of cervical spine and severe compression fracture instability. Combined approaches are indicated for patients who

have severe instability and significant neurocompressive pathological condition. (Anderson, 2004) The most common use of internal spinal fixation is to reduce the rate of pseudoarthrosis after fusion and to restore anatomic vertebral alignment after trauma. Fusion is nearly always performed in conjunction with internal fixation. Bone graft material is often used to promote fusion and to replace bone after resection¹. Preoperatively, an incorrect diagnosis or inaccurate identification of a nerve root or disc level is a problem. Intraoperative complications can include injury to the spinal cord, nerve roots, dura, vessels, and other soft tissues. Postoperative neurological injury can result from hematoma, cord edema, disk herniation, and hardware failure or migration. Postoperative complications can include hematoma, infection, and instability (Shone et al., 1993).

Aims and Objectives

1. Clinical and radiological evaluation of results of Cervical Spine Locking Plate in prospective and retrospective cases of lower cervical spine injuries.
2. To study various complications of cervical spine locking plate.

*Corresponding author: Dr. Sandeep Kumar,
Department of Orthopedics SRHU Swami Rama Nagar Dehradun, India.

- To formulate the indications for fixation of cervical spine injuries.

MATERIALS AND METHODS

The present work consists of analysis of clinical, radiological findings and results of management of cervical spine injury patients who were treated surgically by open reduction and internal fixation with cervical spine locking plate and bone grafting. Forty eight patients of cervical spine injury were included in this study. These patients were divided in prospective and retrospective group. Twenty-eight were operated from July 2005 to September 2006 were included in prospective group. In retrospective group twenty patients who came underwent surgery between February 2003 and June 2005 were also included.

The patients included in the study meet the following criteria:-

- Patients with fracture, subluxation or dislocation from C3 to T1 irrespective of the neurological status.
- Patients having unstable fracture.

The patients excluded from study were:-

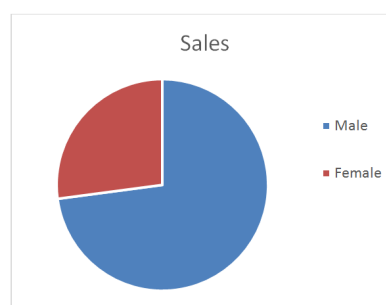
- Patients with fractures involving C1 and C2.
- Patients with stable fractures.
- Patients having multiple skip fractures of cervical spine.

Radiological examination of cervical spine consisted of anteroposterior, lateral, oblique and if required Swimmer's view to rule out injuries involving C7 and T1 and open mouth view to rule out Occipito-Atlantal and Atlanto-Axial injuries. Computerized Tomography of cervical spine was done in all patients to assess the status of vertebral body, facet joints, pedicles, and lamina, spinous process and canal compromise. Patients having unstable cervical spine injuries as per White and Punjabi criteria were admitted and cervical spine traction (head halter and crutch field tongs) was given. Surgical management of cervical spine injuries included anterior as well as posterior fixation depending upon the pattern of injury. Check X-rays were done on the next day. On 1st post operative day patients were allowed to sit. Depending upon the general condition and neurological status of the patient, walking has been allowed from 2nd post operative day. In patients with paraplegia and quadriplegia patient was allowed wheel chair mobility. On the day of discharge neurological examination of every patient was done. Every patient was advised to come for follow-up at 6 week interval. On every follow-up, neurological examination was done and compared with previous neurological status and patients were X-rayed to know the status of implant and bony fusion. Status of fusion was assessed radiologically by diminishing of radiolucent line and crossing of bony trabeculae between body of vertebrae and graft.

RESULTS

- The most common age group affected was 31-40 years, mean age was 42 years. Male (72.91%) predominated females (27.08%).
- Fall from height (50%) was a major cause of injury followed by road side accident (43.7%).
- All patients had unstable cervical spine according to White and Punjabi criteria irrespective of neurological status.

- Most common type of injury was subluxation of C5 over C6 (10 (35.7%) in prospective and 5 (25%) patients in retrospective group) followed by subluxation C6 over C7.
- Subluxation was reduced with traction in 20 (66.7%) patients.
- In 75% of the patients anterior approach was used and in 25% of the patients combined anterior and posterior approach was used for surgery.
- In all the patients Cervical Spine Locking Plate (CSLP) was used for internal fixation of cervical spine. Additional surgical intervention consisted of discectomy in 26 (54.16%) patients as disc was found protruding in the spinal canal, corpectomy and replacement of vertebrae with bone graft filled cage in 10(20.83%) patients as fractured vertebrae was found smashed and fragmented, facetectomy in 12 (25%) as facet joints was found locked and spinous process wiring in 7 (14.58%) patients to achieve posterior stability.
- There was statistically significant (p-value = 0.00 in prospective and p-value = 0.001 in retrospective group) neurological recovery in most of the patients.
- Fusion occurred in 100% of patient within 12 to 18 weeks.
- Movements of neck ranged flexion-extension 100⁰-115⁰, axial rotation 110⁰-130⁰ and lateral bending 60⁰-70⁰.
- In three patients, reduction of fixation could not achieved during anterior approach so facetectomy had to be done by posterior approach and reduction and stabilization with CSLP and bone grafting was done by anterior approach.
- Recurrence of subluxation of C6 over C7 of about 2.5mm occurred in one case (2.08%) of prospective group.
- Commonest complication encountered in our study was difficulty in deglutition.
- One (2.08%) patient died due to CSF leak during surgery and postoperative meningitis.



DISCUSSION

Post operatively neurological recovery of variable degree has been reported in the literature. Kiwerski (1982), noted improvement in muscle power grade by one in 31.8% patients, grade two in 10.09% patients, grade three in 0.9% patients, no recovery in 58.5% patients and no further deterioration in neurologically intact patients. The implant fixation and bone grafting has been reported to result in successful fusion of spine in 97% to 100% of cases Bohler *et al.* (1980), Bose *et al.* (1998). In 2002, Barnes *et al.* (2002) reported 2.6% rate of hardware failure. In 1998, Lowery GL *et al* concluded that hardware failure does not need immediate removal of the

failed hardware. If reoperation necessary for non-union repair, kyphosis correction or other secondary procedures, hardware can be removed. In 2001, Das *et al* (2001) reported 100% fusion rate with the use of bone graft filled cylindrical mesh after corpectomy. Obrein *et al* (1982) 6% and Harris *et al.* (1980) found corresponding figures. In the present study, improvement in muscle power was observed, grade one in 6 (10.8%), two in 8(16.67%), three in 9(18.76%) and 4 in one (2.08%) patients. One patient had no recovery. There was no neurological deterioration in neurologically intact patients.

Conclusions

1. Internal fixation of cervical spine with cervical spine locking plate (CSLP) needs careful observation of minor details which must be respected to optimize the results.
2. Decompression of the spinal cord and stabilization with anterior cervical plates prevents the further damage to spinal cord, allows early mobility in neurologically intact patients and rehabilitation becomes easy in patients having neurological deficit.
3. Good fusion can be obtained after internal fixation with CSLP and bone grafting.
4. In patients with fracture of vertebral body, cage filled with bone graft excellent results by maintain lordosis and providing stability.

REFERENCES

- Alexander R. Vaccaro. 2001. Fractures and dislocations of lower cervical spine. In: Robert W. Bucholz, James D, Heckman, eds. Fractures in adults, Fifth edition. Philadelphia: William and Wilkins; 1375-1403.
- Anderson PA. 2004. Injuries of upper cervical spine. In: Framoyer JW, Wiesel SW, eds. The adult and paediatric spine, Third edition. U.S.A: Lippincott William and Wilkins; 633-669.
- Barnes B, Haid RW, Rodts G, *et al.* 2002. Early results of atlantis anterior cervical plate system. *Neurosurg Focus*, 12:1-7.
- Bohler B, Gaudernak T. 1980. Anterior plate stabilization for fracture dislocation of the lower cervical spine. *J Trauma.*, 20:203-205.
- Bose B. 1998. Anterior cervical fusion using Casper plating: Analysis of results and review of literature; *SurgNeurol.*, 49:25-31.
- Das K, Couldwell WT, Sava G, *et al.* 2001. Use of cylindrical titanium mesh and locking plates in anterior cervical fusion. *J Neurosurg.*, 13(5):174-178.
- Goodrich J, Thad RD. 2005. Lower cervical spine fractures and dislocations. *emedicine continuing education*, 1-12.
- Harris P, Karni MJ, Mcdemont E, *et al.* 1980. The prognosis of patients sustaining cervical spine injuries. *Paraplegia*, 18:324.
- Kiwerski SJ. 1982. Anterior Interbody fusion in the treatment of cervical spine injury. *International Orthopaedics*, 6:255-288.
- Obrein PJ, Schweigel JF, Thompson WJ. 1982. Dislocation of lower cervical spine. *J Trauma.*, 22(8):710-714.
- Sekhon LH, Fehlings MG. 2001. Epidemiology, demographics and pathophysiology of acute spinal cord injury. *Spine*, 26:S2-12
- Shone RM, MacMillan M, Montgomery WJ. Spinal fixation part-I principles, basic hardware and fixation techniques for the cervical spine. *Radiographics* 1993; 13:797-816.
