



## CASE STUDY

### INAUGURAL HEART FAILURE DUE TO DILATEDCARDIOMYOPATHY:VIH IS THE CAUSE

**\*Houssam Laachach, Virginie Chelini, Ismaili Nabila and Noha Elouafi**

Department of Cardiology, Mohammed 6 University Hospital Oujda, Mohammed first University, Morocco

#### ARTICLE INFO

##### Article History:

Received 22<sup>nd</sup> July, 2017  
Received in revised form  
19<sup>th</sup> August, 2017  
Accepted 12<sup>th</sup> September, 2017  
Published online 17<sup>th</sup> October, 2017

#### ABSTRACT

During the first episode of heart failure, especially in young people, the real challenge after symptomatic treatment is etiological research. HIV infection is known to be predictive of cardiac complications by several mechanisms. We report the case of a young person diagnosed with AIDS after inaugural cardiac failure on dilated cardiomyopathy.

#### Key words:

Dilated cardiomyopathy, VIH.

Copyright©2017, Houssam Laachach et al. This is an open access article distributed under the Creative Commons Attribution License, which permits unrestricted use, distribution, and reproduction in any medium, provided the original work is properly cited.

Citation: Houssam Laachach, Virginie Chelini, Ismaili, N. and Noha Elouafi, 2017. "Inaugural heart failure due to dilated cardiomyopathy: VIH is the cause", *International Journal of Current Research*, 9, (10), 58747-58748.

## INTRODUCTION

Heart failure during HIV infection is so frequent and often severe. Infection with the HIV virus can affect several heart tunics: cardiomyopathies, pericarditis, endocarditis and pulmonary hypertension. Compared to opportunistic infections, cardiac damage and especially dilated cardiomyopathy during HIV infection are rarely studied. We report the case of a young man aged 39 years, who is present on dilated cardiomyopathy.

#### Clinical case

It is about Mr F.S: 39 years old, without known medical history, under adverse socio-economic conditions. Admitted in a table of inaugural overall heart failure. The ECG has objectified a left bundle block (Figure 1). The echocardiography showed dilated cardiomyopathy with severe systolic dysfunction with pulmonary hypertension (Figures 2 and 3). Coronary angiography was normal. Cardiac MRI noted an appearance of viral myocarditis (Figure 4). The biological assessment highlighted a lymphopenia and HIV test was positive. CD4 at 72 cells/mm<sup>3</sup> and the viral load at 2100000 cu/ml. The remainder of the viral serology testing and the blood test were normal. After the control of 03 months, the patient has moderately well evolved under VIH bi-therapy and Ramipril.

## DISCUSSION

Cardiac involvement in HIV infection can be observed especially at the stage C, according to the Atlanta CDC classification (Longo-mbenza *et al.*, 1997). The prevalence of cardiomyopathies during HIV infection is poorly specified, it is from 2.7% to 17% according to limited series (El Hattaoui *et al.*, 2008). The delay in diagnosis can be explained the fact that this cardiac involvement during HIV infection can remain asymptomatic for a long time, but it can also be translated into a table of heart failure usually global (Rakotonirina *et al.*, 2014; Bouramou and Ekoba, 1996). The mechanism is explained by myocarditis due to viral infection with HIV or the co-infection with other cardio tropic viruses in over 80 % cases (Rakotonirina *et al.*, 2014; Bouramou and Ekoba, 1996). Besides, there is the indirect mechanism comprising the development of cardiac auto-antibodies, food deficiency, in particular in thiamine and selenium, and the role of antiretroviral therapy, nucleoside analogues (AZT) and certain inhibitors of protease have also been mentioned. Dilated cardiomyopathy in patients HIV positive is serious and is associated with poor prognosis for cardiomyopathy other etiologies (Silver *et al.*, 1984). It is explained by the fact that this cardiomyopathy remains asymptomatic for a long time and most patients are diagnosed with advanced stage of HIV infection with CD4 count very low, less than 400 / mm<sup>3</sup>. Cardiac Echocardiography should be systematic for all patients of HIV because it can detect early this cardiac involvement by the evaluation of the function diastolic and systolic blood pressure of the left ventricle, every year.

\*Corresponding author: Houssam Laachach,  
Department of Cardiology, Mohammed 6 University  
Hospital Oujda, Mohammed first University, Morocco.

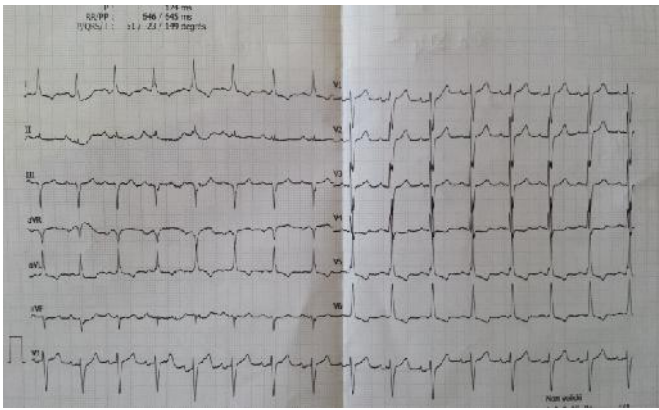


Fig. 1. ECG : Left Bundle block

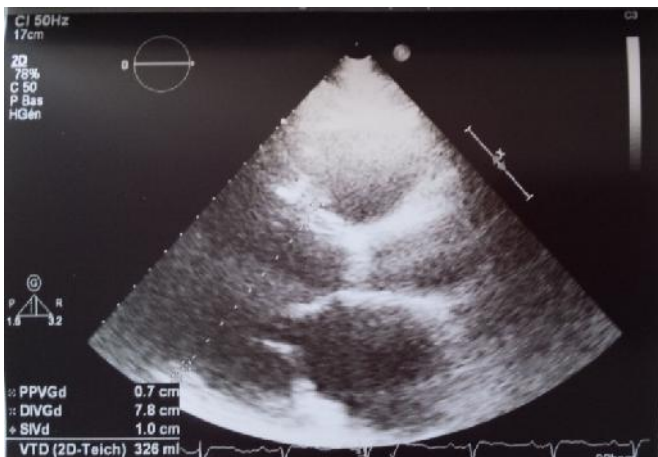

Fig. 2. Echocardiography showing a dilated LV (parasternal)

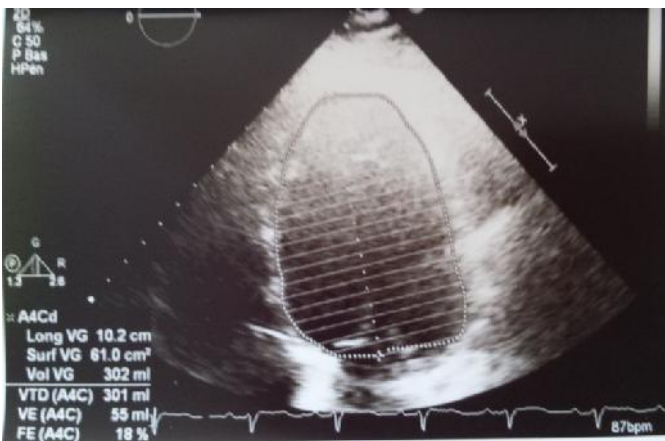


Fig. 3. Echocardiography showing a dilated LV (4C)

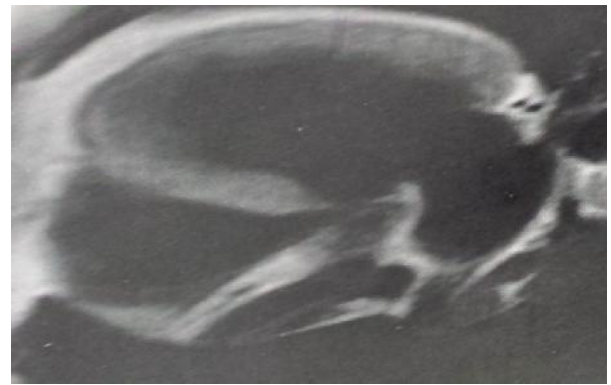


Fig. 4. Cardiac MRI showing a dilated LV and inflammatory wall

The recommendations of the European Society of Cardiology advocate Magnetic Resonance Imaging for the measurement of volumes, mass and LV ejection fraction (Longo-mbenza *et al.*, 1997). HIV testing must be systematic in the face of all unexplained dilated cardiomyopathy because it is still low despite the increase in the global prevalence of this infection.

### Conclusion

Expanded cardiomyopathies are increasingly secondary. AIDS is one of the etiologies that are no longer exceptional. The echocardiography and the cardiac MRI are of great use to the diagnosis alongside the blood biological test.

### REFERENCES

- Bouramoue C, Ekoba J. 1996. Le coeur et le Sida. *Méd Trop.*, 56: 33-9.
- El Hattouï, M., N. Chareï, D. Boumzebra b, L. Aajly, S. Fadouach. 2008. Prevalence of cardiomyopathy in HIV infection: Prospective study on 158 HIV patients. *Médecine et maladies infectieuses : Volume 38, n° 7* :pages 387-391, Doi : 10.1016/j.medmal.2008.03.006
- Longo-mbenza B, Tondouangu K, Kintonki VE, *et al.* 1997. Influence de l'infection par le VIH sur la fréquence élevée des cardiopathies à Kinshasa (Zaire). *Ann Cardiol Angéiol.*, 1997; 46: 81-7.
- Rakotonirina J, Razanakoto H, Rasolofomanana L, *et al.* 2014. HIV prevalence and diabetes prevalence among tuberculosis patients in Antananarivo city. *Int J Res Med Sci.*, 2(3): 834-7.
- Silver MA, Macher AM, Reichert CM, *et al.* 1984. Cardiac involvement by Kaposi's sarcoma in acquired immune deficiency syndrome (AIDS). *Am J Cardiol.*, 53: 983-4.

\*\*\*\*\*