



## RESEARCH ARTICLE

### FREQUENCY AND UTILITY OF ULTRASOUND FOR DIAGNOSIS OF PCOS IN WOMEN POPULATION

\*Dr. Samia Perwaiz khan, Dr. Arwa Iqbal Hussain, Dr. Safia Izhar, Dr. Sadia Rashid and  
Dr. Fadieleh A. Sohail

Department of Pharmacology, Jinnah Medical and Dental College, Karachi 74800, Pakistan

#### ARTICLE INFO

##### Article History:

Received 29<sup>th</sup> December, 2017  
Received in revised form  
24<sup>th</sup> January, 2018  
Accepted 09<sup>th</sup> February, 2018  
Published online 28<sup>th</sup> March, 2018

##### Key words:

Polycystic ovary syndrome,  
PCOS, ultrasound,  
Ovarian follicles

#### ABSTRACT

Polycystic ovary syndrome is a multi-factorial disease. It is the most common endocrine disorder in women of child-bearing age. This clinical characterized of diseases include disrupted ovulation and hyperandrogenism, but the clinical picture and symptom intensity can vary. Currently, the ultrasound assessment of ovaries is one of the essential criteria for the diagnosis of PCOS according to the Rotterdam consensus (2003) and Androgen Excess and PCOS Society (2006). This criterion is determined by the presence of  $\geq 12$  follicles within the ovary with a diameter of 2–9 mm and/or ovarian volume  $\geq 10$  cm<sup>3</sup>. Such ultrasound image in one ovary only is sufficient to identify polycystic ovaries. The finding of polycystic ovaries with polycystic ovary syndrome is confirmed in over 90% of cases irrespective of ethnic factors or race. The assessment of hormone levels as an equivalent of ultrasound features of polycystic ovaries is a promising method. However, aim of this study was to determine that the typical finding of polycystic ovaries in women diagnosed clinically or hormonal levels in population of Karachi.

Copyright © 2018, Samia Perwaiz khan et al. This is an open access article distributed under the Creative Commons Attribution License, which permits unrestricted use, distribution, and reproduction in any medium, provided the original work is properly cited.

Citation: Dr. Samia Perwaiz khan, Dr. Arwa Iqbal Hussain, Dr. Safia Izhar, Dr. Sadia Rashid, Dr. Fadieleh A. Sohail, 2018. "Frequency and Utility of ultrasound for diagnosis of PCOS in Women population", *International Journal of Current Research*, 10, (03), 66406-66408.

#### INTRODUCTION

Polycystic ovary syndrome (PCOS) is associated with ovarian overproduction of androgens with main features of hyperandrogenism and an ultrasound appearance of polycystic ovaries (Bachanek et al., 2015). It is the most common endocrine disorder in young women. This endocrine disease is primarily characterized by anovulation and hyperandrogenism. The ultrasound assessment of ovaries is one of the obligatory criteria for the diagnosis of PCOS according to the Rotterdam consensus (2003) and Androgen Excess & PCOS Society (2006). This criterion is determined by the presence of  $\geq 12$  follicles within the ovary with a diameter of 2–9 mm and/or ovarian volume  $\geq 10$  cm<sup>3</sup>. The polycystic ovaries with polycystic ovarian syndrome is confirmed in over 90% of cases irrespective of ethnicity (Guraya, 2013). Similarity of ultrasound features of polycystic ovaries in healthy women, the inclusion of this sign to the diagnostic criteria of polycystic ovary syndrome is under research. The development of new technologies has an undoubted influence on the percentage of diagnosed polycystic ovaries (Christ et al., 2015). This process has caused an increase in the percentage of polycystic ovary diagnoses since the Rotterdam criteria were published. It is therefore needed to prepare new commonly accepted diagnostic norms concerning the number of ovarian follicles

The assessment of anti-Müllerian hormone levels as an equivalent of ultrasound features of polycystic ovaries is a promising method. However, analytic methods have to be standardized in order to establish commonly accepted diagnostic norms (Balen et al., 2003; Chen et al., 2008). Number of follicles per follicle size category, antral follicle count (AFC), ovarian volume (OV), follicle distribution pattern, stromal area, ovarian area, stromal to ovarian area ratio (S/A) and stromal echogenicity index (SI), total (TT), androstenedione, LH, FSH, cholesterol, triglycerides, low-density lipoprotein, high-density lipoprotein, C-reactive protein, glucose, insulin, and hemoglobin A1C, menstrual cycle length, hirsutism score, body mass index (BMI), waist:hip ratio, and blood pressure (Artini et al., 2010).

#### MATERIALS AND METHODS

Women included in the study with complaints of oligomenorrhea/ amenorrhea acne, hirsutism and infertility were included from the gynae/ obstetrics and ultrasound OPD Medicare hospital. Ultrasound pelvis was done determination of ovarian size (length x height x width) volume and follicular count was done to confirm the diagnosis polycystic ovaries.

#### RESULTS

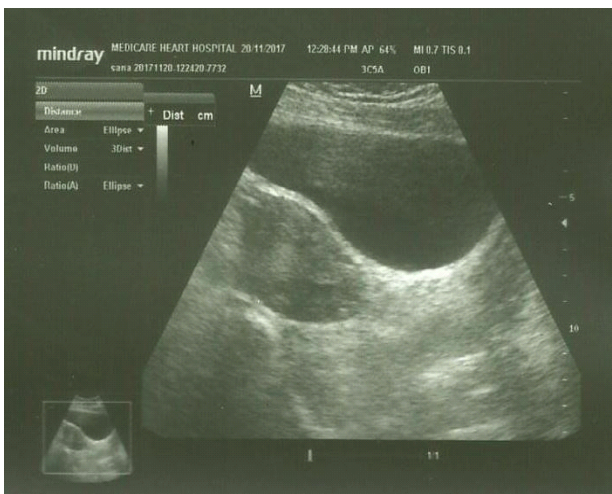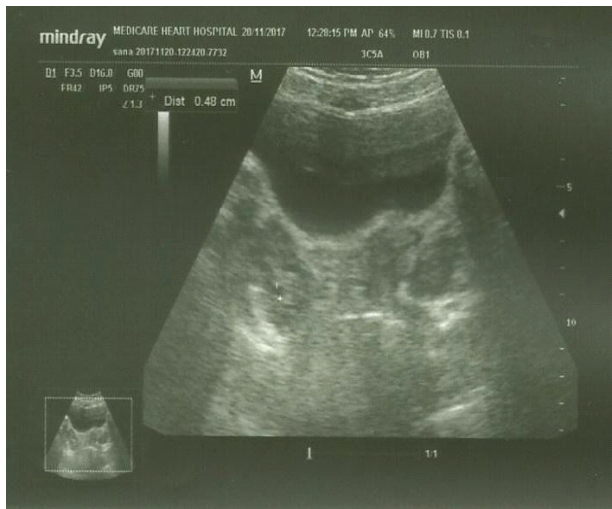
Out of total twenty five women clinically diagnosed as PCOs were recommended ultrasound. It was found that out of these 25 women those showing increased volume 8 (32%) and string

\*Corresponding author: Dr. Samia Perwaiz khan,  
Department of Pharmacology, Jinnah Medical & Dental College,  
Karachi 74800, Pakistan.

of follicles at periphery 25 (100%) was more common finding on ultrasound.

**Table 1. Frequency of ultrasound diagnosis of PCOS in Women population**

Increase volume Right ovary N= 25	Right ovary String of follicles N= 25	Increased volume of left ovary N= 25	Left ovary String of follicles N= 25
8 (32%)	25 (100%)	8 ( 32 % )	25 (100%)



**Figure 1. Enlarged ovaries with string of follicles in periphery**

## DISCUSSION

The ultrasound diagnostic criteria of PCO have improved the diagnosis. With latest improvement in the technology, the diagnostic accuracy has evolved from a mere appreciation of overall ovarian size to the recognition of characteristic follicular patterns of distribution and textural changes in the ovarian stroma. The presence of peripheral tiny follicles than either ovarian volume or stromal brightness [Gurya]. It has also been confirmed that the coexistence of polycystic ovaries with PCOS is common (over 90% of cases) irrespective of ethnic factors or race (Artini *et al.*, 2010; Dewailly *et al.*, 2010). The excess of ovarian follicles in this syndrome is strictly associated with hyperandrogenism, which has been demonstrated by Dewailly *et al.* (2010). The polycystic ovarian syndrome (PCOS) includes a wide spectrum of clinical symptoms and signs. Three different diagnostic classifications have been proposed to define this disease. The first one,

published in 1990, known as the “NIH criteria” requires the simultaneous presence of hyperandrogenism and menstrual dysfunction in order to diagnose PCOS. Later on, in 2003, an expert panel met in Rotterdam and added to the previous criteria the presence of polycystic ovarian morphology detected by transvaginal ultrasonography. The later classification broadened the spectrum of PCOS and also included women with oligomenorrhea and PCO without hyperandrogenism or hyperandrogenism and PCO without menstrual dysfunction. Finally, the Androgen Excess Society, published in 2006 new diagnostic criteria which required the presence of clinical or biochemical hyperandrogenism, with either PCO or menstrual dysfunction to diagnose PCOS. The benefit and utmost importance of lifestyle modification for the long-term health of these women is stressed as well. It is hoped that some clarity in this regard will allow more women to not only be diagnosed and managed properly for their presenting symptoms (hirsutism, irregular menses, etc.), but also to be educated and managed for the continuing health risk of insulin resistance throughout their lives (Legro *et al.*, 2007). By appropriate diagnosis life style modification and treatment options should be considered to prevent complications and fertility (Lashen, 2010).

## Conclusion

The ultrasound finding in anovulatory women with polycystic ovarian syndrome prior to therapy the increase in volume and peripheral string of follicles correlates with clinical finding and beneficial for diagnosis and appropriate management.

## REFERENCES

- Artini P. G., Di Berardino O. M., Simi G., Papini F., Ruggiero M., Monteleone P., Cela V. 2010. Best methods for identification and treatment of PCOS. *Minerva Ginecologica*, 62(1):33-48
- Bachanek, M., Abdalla, N., Cendrowski, K., Sawicki, W. 2015. Value of ultrasonography in the diagnosis of polycysticovary syndrome – literature review. *Journal of Ultrasonography*, 15: 410-422.
- Balen, A.H., Laven, J.S., Tan, S.L., Dewailly, D. 2003. Ultrasound assessment of the polycystic ovary: international consensus definitions. *Hum Reprod Update*, 9: 505-514.
- Chen Y, Li L, Chen X, Zhang Q, Wang W, Li Y *et al.*, 2008. Ovarian volume and follicle number in the diagnosis of polycystic ovary syndrome in Chinese women. *Ultrasound Obstet Gynecol*, 32: 700-703.
- Christ, J.P., Vanden Brink, H., Brooks, E.D., Pierson, R.A., Chizen, D.R., Lujan, M.E. 2015. Ultrasound features of polycystic ovaries relate to degree of reproductive and metabolic disturbance in polycystic ovary syndrome. *Fertil Steril.*, 103(3):787-94. doi: 10.1016/j.fertnstert.2014.12.094. Epub.
- Dewailly D, Pigny P, Soudan B, Cateau-Jonard S, Decanter C, Poncelet E *et al.*, 2010. Reconciling the definitions of polycystic ovary syndrome: the ovarian follicle number and serum anti-Müllerian hormone concentrations aggregate with the markers of hyperandrogenism. *J Clin Endocrinol Metab.*, 95: 4399-4405.
- Guraya S. S. 2013. Prevalence and ultrasound features of polycystic ovaries in young unmarried Saudi females. *Journal of Microscopy and Ultrastructure*, 1, 30-34.

- Lashen H. 2010. Role of metformin in the management of polycystic ovary syndrome. *Therapeutic Advances in Endocrinology and Metabolism*, 1(3) 117\_128. DOI: 10.1177/2042018810380215.
- Legro RS, Barnhart HX, Schlaff WD, Carr BR, Diamond MP, Carson SA, et al. 2007. Clomiphene, metformin, or both for infertility in the polycystic ovary syndrome. *New England Journal of Medicine*, 356(6):551–66.
- Lujan, M.E., Jarrett, B.Y., Brooks, E.D., Reines, J.K., Peppin A.K., Muhn, N. *et al.*, 2013. Updated ultrasound criteria for polycystic ovary syndrome: reliable thresholds for elevated follicle population and ovarian volume. *Hum Reprod*, 28: 1361–1368.