



RESEARCH ARTICLE

FRACTURE HEALING AUGMENTATION WITH TERIPARATIDE THERAPY: A CASE STUDY OF FRACTURE DISTAL END FEMUR FROM INDIA

*Dr. Sujoy Kundu

MBBS, MS, MCH, Consultant Orthopedics, Residence Chamber 'BIJOLI' 131/6, Mahendra Bhattacharya Road, Santragachi, Howrah - 711104, India

ARTICLE INFO

Article History:

Received 19th October, 2017
Received in revised form
21st November, 2017
Accepted 16th December, 2017
Published online 31st January, 2018

Key words:

Teriparatide, Distal femoral fracture,
Osteoporosis, Fracture healing,
Non-union.

ABSTRACT

Distal femoral fractures account for about 6-7% of all femoral fracture and often are unstable and comminuted. They have a potential for long term disability. Impaired healing of such fractures further delays the rehabilitation process, thus impacting quality of life. Teriparatide is not an approved drug for treating osteoporosis in India, unlike other countries. Intermittent administration of teriparatide has anabolic effects that stimulate bone formation and activate bone remodeling. The purpose of this case report is to elucidate the Indian experience of 5 cases of use of teriparatide for fracture of distal femur with non-union. In our experience teriparatide therapy was beneficial to bone healing after the fracture of distal end of femur. Further, it may lead to an early return to activity and vocation for patients undergoing fracture distal end femur.

Copyright © 2018, Dr. Sujoy Kundu. This is an open access article distributed under the Creative Commons Attribution License, which permits unrestricted use, distribution, and reproduction in any medium, provided the original work is properly cited.

Citation: Dr. Sujoy Kundu, 2018. "Fracture healing augmentation with teriparatide therapy: A case study of fracture distal end femur from India", International Journal of Current Research, 10, (01), 64576-64580.

INTRODUCTION

Optimal fracture healing occurs in the shortest time frame with best possible functional recovery. In a normal biological environment, skeletal fractures heal within 6 to 8 weeks. If a fracture is not healed after 4 months, it can be considered a delayed union. If no bony healing is obtained in 6 months after the fracture, it can be clinically considered as non-union. Distal femoral fractures account for about 6-7% of all femoral fracture.^{i,ii}The fractures occur in a bimodal distribution. One group is which sustains high-energy trauma and other group is of post-menopausal osteoporotic females.ⁱⁱⁱThese fractures are usually unstable and have potential for long term disability.¹Impairment in healing process and non-union of these fractures further delays the rehabilitation process, which adversely affect the quality of life. Thus addressing fracture healing in distal femur is very important, and it can be achieved successfully using anabolic therapy like teriparatide. There is no drug currently approved for fracture healing in India. A better understanding of mechanisms pertaining to bone repair and its augmentation techniques can guide us to evaluate new possibilities of augmenting fracture healing like teriparatide. Teriparatide is a recombinant 1-34 fragment of human parathyroid hormone (PTH) having most of the biological activities of PTH.^{iv}

It is a powerful anabolic agent on bone, thus improving its mass, geometry and microarchitecture. In preclinical animal models, intermittent administration of teriparatide, enhances early chondrogenesis and endochondral ossification, which results in increased callus formation and better biomechanical strength of the callus.^v The same has been supported by clinical trials.^{vi, vii} It is an approved drug for treatment of osteoporosis and effective in stimulating bone formation and promote growth factor production for fracture healing. When teriparatide administered intermittently it produces anabolic effects that are responsible for stimulating the bone formation and bone remodeling process.^{viii} Any medical therapy which promotes healing in non-union cases or shortens the time interval for fracture healing will be of great social and economic benefit. The objective of this case report is to envisage the Indian experience of use of teriparatide for fracture of distal femur with impaired healing and non-union.

Case description

Case 1

T/F/1, 53 years old post-menopausal female injured in road traffic accident. After clinical examination & investigation patient was diagnosed with fracture of right distal femur. She was operated on February 2017 for internal fixation with LC-LCP. First x-ray taken on April 2017 showing no sign of fracture union. Injection teriparatide 20 mcg for 3 months was

*Corresponding author: Dr. Sujoy Kundu,
MBBS, MS, MCH, Consultant Orthopedics, Residence Chamber 'BIJOLI'
131/6, Mahendra Bhattacharya Road, Santragachi, Howrah - 711104, India.

started from May 2017. X-ray taken on June 2017 also showing no sign of fracture union. But last x-ray taken in August 2017 showing complete union.

Injection teriparatide 20 mcg for 3 months was also started at same time. She got the complete union of fracture within 4 months.

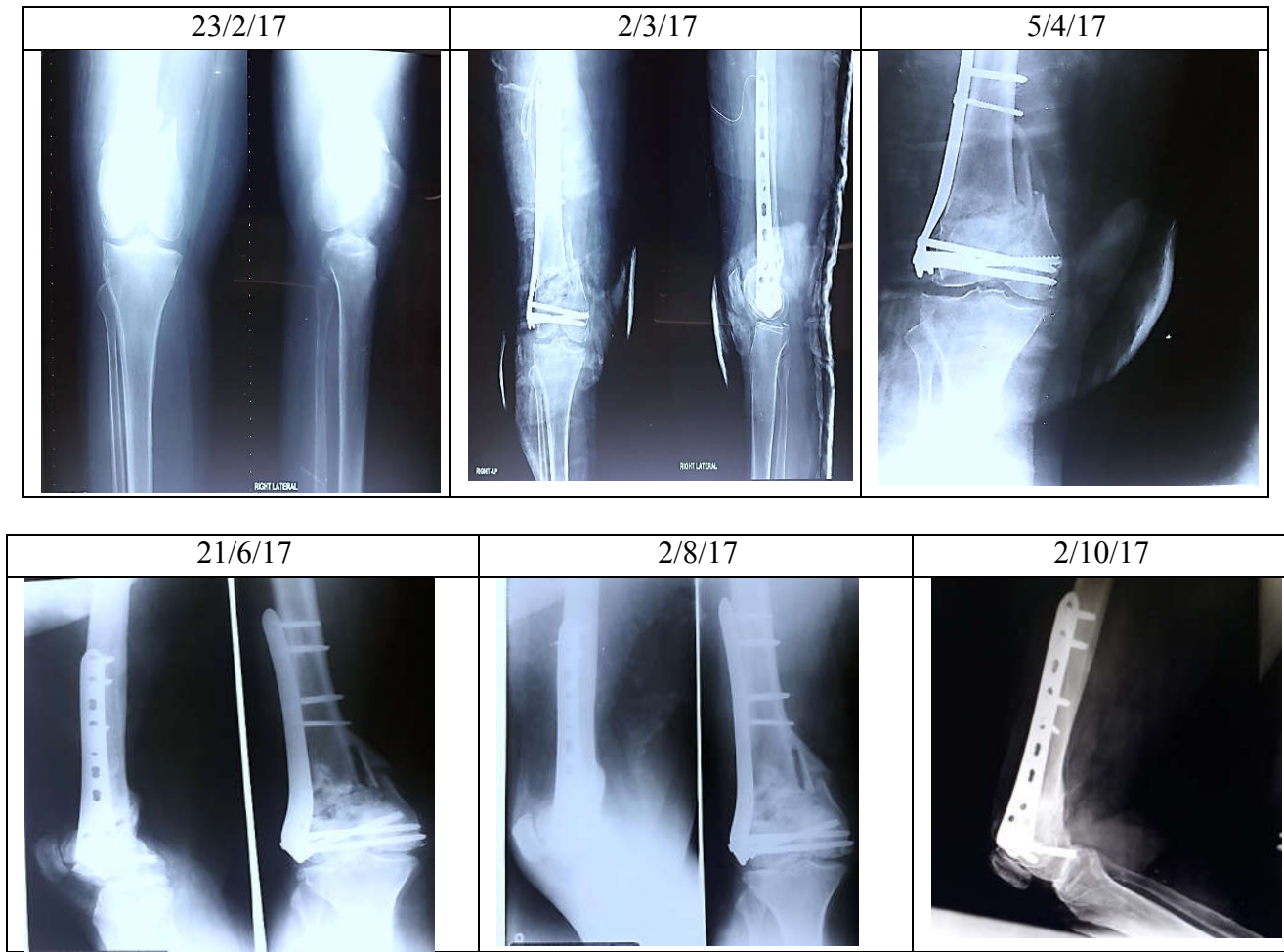


Figure 1. X-ray distal end of right femur antero-posterior & lateral view of case 1

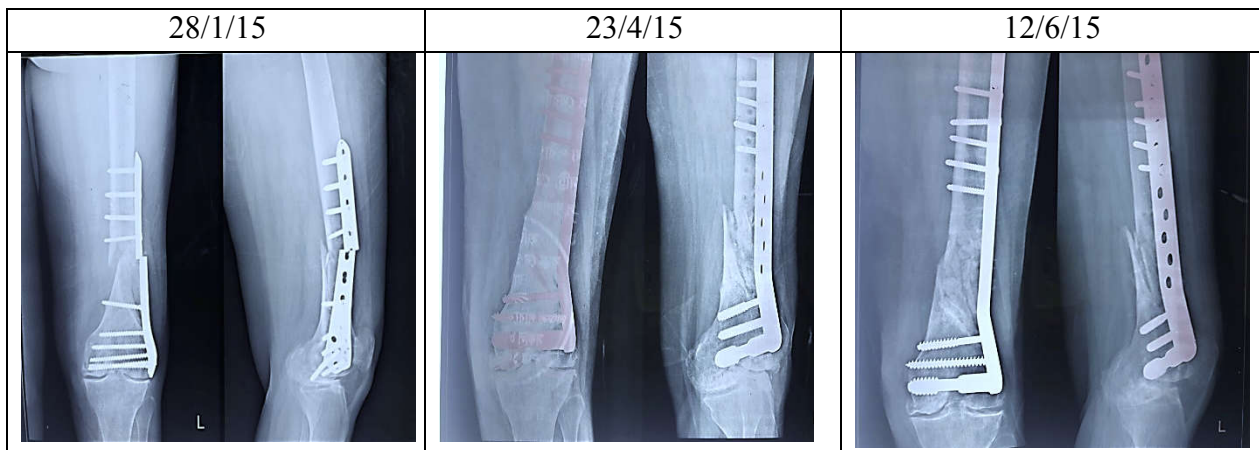


Figure 2. X-ray distal end of left femur antero-posterior view of case 2

Case 2

T/F/2, 65years old post-menopausal women having history of fall. After investigation the patient diagnose with osteoporosis along with fracture of left distal femur. She was operated for the same in November 2104 with LC-LCP. In January 2015 there was breakage of implant for which she was re-operated in February 2015 with DCS barrel plate.

Case 3

T/F/3, 56 years old post-menopausal lady came with history of fall. On clinical examination and investigation she was diagnose with osteoporosis and fracture of right distal femur with intraarticular extensions for which she was operated in August 2015. X-ray taken in initial period showing no sign of fracture union and it was continued till October 2015.

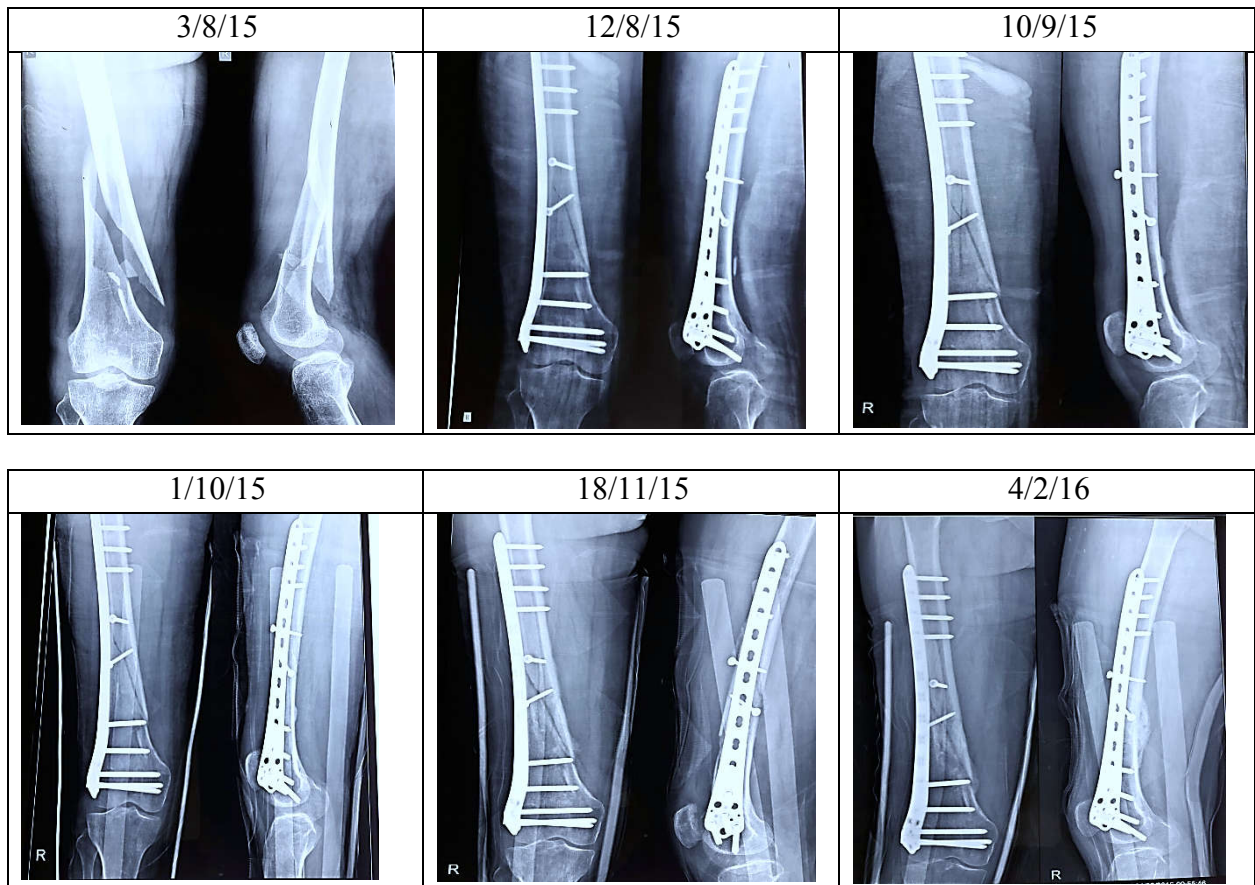


Figure 3. X-ray distal end of right femur antero-posterior view of case 3

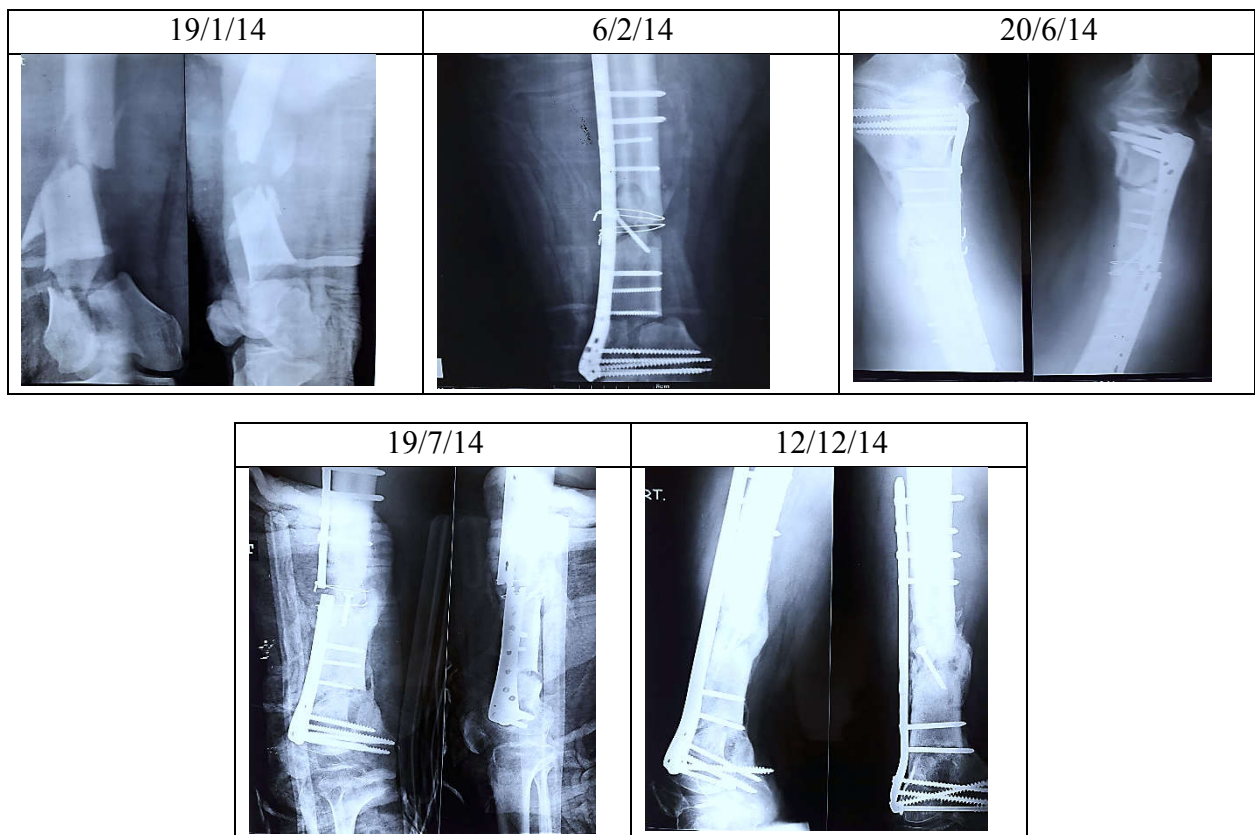


Figure 4. X-ray distal end of right femur antero-posterior & lateral view of case 4

Then injection teriparatide 20 mcg for 3 months was started. Fracture union seen on x-ray taken after 3 months.

Case 4

T/F/4, 42 years old male patient was admitted in January 2014. After clinical examination & investigation patient was

diagnose with infected gassillo type 2 injury with 7 part comminuted compound fracture of distal femur with intra articular extensions. Initially injection linezolid 600 mg twice a day for two weeks was given to treat infection. When the infection subside patient was operated in first week of February 2014 with CRP 14.8 and LC-LCP. After fixation, pop long slab was given and advised strict bed rest for 3 months. X-ray was taken after 3 months which show no sign of union. In June there was breakage of his implant and patient was re-operated. Then again patient was given LC-LCP along with steel plate and injection teriparatide 20 mcg was also started for 3 months. In December 2014 x-ray showed complete union of fracture.

concluded that there was an abbreviated time of fracture healing in the group who received 20 mcg of teriparatide compared to placebo.^{xii} A prospective study was carried out by Chiang et al. in patients having atypical femoral fracture who received 20 mcg of teriparatide daily for six months. Out of these, 5 treated patients showed 2 to 3 fold increase in bone remodeling markers and fracture healing. This finding also revealed that teriparatide improves healing in atypical fractures.^{xiii} Borges et al. reported one case of 84-year old woman with a trochanteric fracture which required surgical intervention. X-ray of the fracture site was done after one month of the surgery which indicate absence of fracture healing.

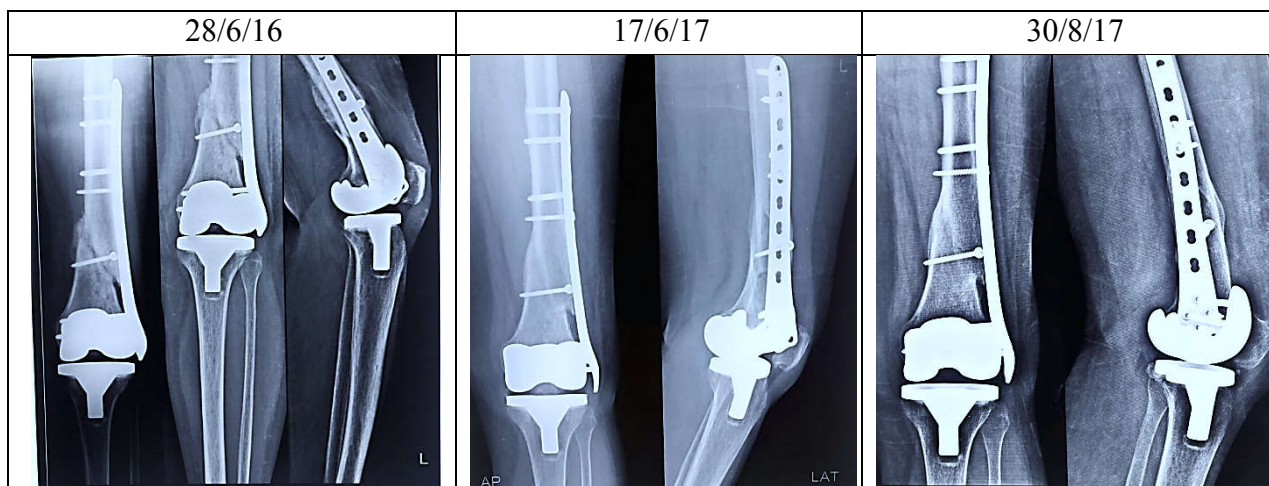


Figure 5. X-ray distal end of left femur antero-posterior & lateral view of case 5

Case 5

T/F/5, 58 year old female undergone total knee replacement in 2014. She was having history of fall related per-prosthetic fracture of left distal femur for which she was operated in 2016. Internal fixation done with LC-LCP. Lateral condylar plate was not united after 2 months. Then injection teriparatide 20 mcg started for 3 months. X-ray taken after this period show the union of fracture.

DISCUSSION

Fracture nonunion rates are variedly reported based on types of fracture, ranging from 18.5% in the tibia diaphysis^{ix} to 1.7% in the femoral shaft.^x Apart from Teriparatide, many physical and biologic methods have been evaluated for enhancing fracture healing including, laser, direct current, microcurrent, electrical magnetic field, ultrasound, and capacitive coupled electrical stimulation. Teriparatide affects osteoclast maturation and function, whereas it stimulates osteoblast proliferation, activity, and lifespan.¹² Sloan et al.^{xi} experimentally showed that teriparatide significantly increases the area of intra-cortical resorption and the percentage of crack length repair compared with those of controls. Our observations are in accordance with other studies showing the anabolic effects of teriparatide on delayed union and non-unions in human subjects especially in patients with osteoporosis or those who received internal fixation. Our case report demonstrated that short interval of time was required for fracture healing in the patients who received 20 mcg of teriparatide for 3 months and our finding are in accordance with study carried out by Aspenberg et al.. They performed a randomized, double-blind study involving 102 post-menopausal women with distal radial fractures and

She was given 20 mcg of teriparatide once in a day and x-ray taken after one month of treatment showed presence of dense callus formation. This case report suggest that teriparatide can hasten healing of fracture.^{xiv} This finding also correlate with our case report which shows rapid fracture healing in femur after treatment with teriparatide. In a case report by Mastaglia et al. the fracture of diaphysis of right femur with delayed union due to prolonged use of bisphosphonates, fracture resolved after treatment with 20 mcg teriparatide for 3 months.⁴ Teruki S et al. analyzed a total of 209 subjects. There were 98 subjects in the teriparatide group and 111 subjects in the placebo group. Patients who received weekly teriparatide had significantly increased BMD at the neck of femur and inter-trochanteric BMD.^{xv}

Clinical application

There is an ongoing quest for therapies augmenting fracture healing. Teriparatide is approved for the treatment of osteoporosis but emerging research in the last decade has shown a potential application in fracture management. Preclinical animal studies and meta-analysis demonstrated both radiographically and histologically that teriparatide responsible for improvements in callus volume, callus mineralization, bone mineral content, strength and rate of successful union at the fracture site. Teriparatide therapy accelerates healing and reduces chances for future second surgery and requirement of bone graft. The advantages of teriparatide therapy are that it can be prescribed in any types of fractures, including those that will be treated non-surgically, it can be commenced at any time, and can be applied through the entire healing period. Observations in our case report support the previous studies using teriparatide for the treatment of fracture non-union and it

is more beneficial in patients of osteoporosis or undergoing internal fixation for fracture. Although case reports form an anecdotal evidence of beneficial effects of TPTD on fracture healing but in dearth of clinical trials, it may offer some guidance for clinical decision making. More case reports and well-designed randomized controlled trials are required to confirm the efficacy and safety of teriparatide for conservative management of fractures and non-unions. A better understanding of fracture healing biology would help in fostering strategies for augmenting fracture healing.

REFERENCES

- ⁱGK Gupta, S Rani, R Kumar, B Singh. Analysis of management of supracondylar femur fracture by locking compression plate. *International Journal of Orthopedics Sciences* 2016; 2(4): 218-222
- ⁱⁱ Hoffmann MF, Jones CB, Sietsema DL. Clinical outcomes of locked plating of distal femoral fractures in a retrospective cohort. *Journal of orthopedic surgery and research.* 2013; 8:43.
- ⁱⁱⁱ Martinet O, Cordey J, Harder Y, Maier A., Buhler M, Barraud GE et al. The epidemiology of fractures of the distal femur. *Injury*, 31(Suppl 3): C62–63, 2000.
- ^{iv} Silvina RM, Gabriel A, Beatriz O. Teriparatide for the rapid resolution of delayed healing of atypical fractures associated with long-term bisphosphonate use. *Eur J Rheumatol* 2015. DOI: 10.5152/eurjrheum.2015.0010
- ^vEllegaard M, Jørgensen NR, Schwarz P. Parathyroid hormone and bone healing. *Calcif Tissue Int.* 2010;14:1–13. doi: 10.1007/s00223-010-9360-5.
- ^{vi}Aspenberg P, Johansson T. Teriparatide improves early callus formation in distal radial fractures. *Acta Orthop.* 2010; 14:234–236. doi: 10.3109/17453671003761946.
- ^{vii}Peichl P, Holzer LA, Maier R, Holzer G. Parathyroid hormone 1-84 accelerates fracture-healing in pubic bones of elderly osteoporotic women. *J Bone Joint Surg Am.* 2011;14:1583–1587. doi: 10.2106/JBJS.J.01379.
- ^{viii}Kraenzlin ME, Meier C. Parathyroid hormone analogues in the treatment of osteoporosis. *Nature Reviews Endocrinology*, 2011; 7(11):647–656. doi:10.1038/nrendo.2011.108.
- ^{ix} K. Fong, V. Truong, C.J. Foote, B. Petrisor, D. Williams, B. Ristevski, et al. Predictors of nonunion and reoperation in patients with fractures of the tibia: an observational study. *BMC Musculoskelet Disord*, 14 (2013), p. 103
- ^x Nonunion following intramedullary nailing of the femur with and without reaming. Results of a multicenter randomized clinical trial. *J Bone Joint Surg Am*, 85-A (2003), pp. 2093-2096
- ^{xi} Sloan AV, Martin JR, Li S, Li J. Parathyroid hormone and bisphosphonate have opposite effects on stress fracture repair. *Bone* 2010; 47: 235-40
- ^{xii} Aspenberg P, Genant HK, Johansson T, Nino AJ, See K, Kelly K et al. (2010) Teriparatide for acceleration of fracture repair in humans: a prospective, randomized, double-blind study of 102 postmenopausal women with distal radial fractures. *J bone Miner Res* 25: 404-414.
- ^{xiii} Chiang CY, Zebaze RMD, Ghasem-Zadeh A, Iuliano-Burns S, Hardidge A, Seeman E et al. (2013) Teriparatide improves bone quality and healing of atypical femoral fractures associated with bisphosphonate therapy. *Bone* 52: 360-365.
- ^{xiv} Borges JLC, Freitas A, Bilezikian JP (2013) Accelerated fracture healing with teriparatide. *Arq Bras Endocrinol Metabol* 57: 153-156.
- ^{xv}Teruki S, Masako I, Masao F, Tatsushi T, Toshitsugu S, Masataka S et al. The effects of once-weekly teriparatide on hip geometry assessed by hip structural analysis in postmenopausal osteoporotic women with high fracture risk. *Bone* 64 (2014) 75–81