



RESEARCH ARTICLE

IMPACT OF BIOPESTICIDE – *AZADIRACHTA INDICA* ON GILLS OF FRESH WATER CATFISH  
*Heteropneustes fossilis*

\*Dr. Vaishali S. Panchwate Tinkhede, Dr. Tantarapale, V.T.

Department of Zoology, Mahatma Fule Senior College, Warud, Amravati, Maharashtra, India

ARTICLE INFO

**Article History:**

Received 19<sup>th</sup> November, 2017  
Received in revised form  
07<sup>th</sup> December, 2017  
Accepted 20<sup>th</sup> January, 2018  
Published online 28<sup>th</sup> February, 2018

**Key words:**

*Azadirachta Indica*,  
*Heteropneustes Fossilis*,  
Sub-Lethal Concentrations,  
Histopathology, Gill Lamella.

ABSTRACT

An investigation on the effect of the *Azadirachta indica* on the gills of *Heteropneustes fossilis* was carried out in the laboratory. Fishes were exposed to sub-lethal concentrations of *Azadirachta indica* for 24, 48, 72 and 96 hrs. The LC<sub>50</sub> values of *Azadirachta indica* calculated for *Heteropneustes fossilis* for 24, 48, 72 and 96 hours are 10.5, 8.5, 7.0 and 6.5 ml/L respectively. The gills were removed for histological examination. The results showed that in normal gills of *Heteropneustes fossilis* shows Primary gill lamella, secondary gill lamella, Inter lamellar space and epithelial cells were observed but with increase exposure, the damage or separation of secondary gill lamellae, epithelial cell hyperplasia, fusion of secondary gill lamella, swelling of secondary gill lamellae and edema, necrosis, hyperplasia, degeneration of cartilaginous bar was observed.

Copyright © 2018, Dr. Vaishali S. Panchwate Tinkhede, Dr. Tantarapale. This is an open access article distributed under the Creative Commons Attribution License, which permits unrestricted use, distribution, and reproduction in any medium, provided the original work is properly cited.

Citation: Dr. Vaishali S. Panchwate Tinkhede, Dr. Tantarapale, V.T. 2018. "Impact of biopesticide – *Azadirachta indica* on gills of fresh water catfish *Heteropneustes fossilis*", *International Journal of Current Research*, 10, (02), 65344-65347.

INTRODUCTION

The aquatic environment is currently under threat by the indiscriminate use of synthetic pesticides by the human activities and causing high risk to non target organisms (Kumar *et al.*, 2010). Pesticides are used in agro-ecosystems, forests, and recreational areas such as golf courses, but it may enter aquatic systems such as streams, rivers, and lakes if used in adjacent areas or if an accidental spill occur. These pesticides are carried into aquatic ecosystem by surface runoff from sites of application and therefore the health of aquatic ecosystem is being adversely affected because they serve as ultimate sink for these pesticides (Singh *et al.*, 2010). These pesticides are also found to be highly toxic not only to fish but also to other organisms which constitute food of the fish. Among different classes of pesticides, organophosphates are more frequently used, because of their high insecticidal property, low mammalian toxicity, less persistence and rapid biodegradability in the environment (Singh *et al.*, 2010). Synthetic pyrethroid insecticides are also extensively used in place of organochlorine, organophosphorus insecticides and carbamates to control pests. These insecticides are more likely to be toxic to fish and other aquatic organisms (Elliot 1977;

Casida *et al.*, 1983; Smith and Stratton 1986; Moore and Waring 2001). In view of the environmental problems caused by the use of synthetic chemicals and the growing need for alternative methods of pest control that minimize this damage, there has been extensive research on pest control by substances from plants (Wan *et al.*, 1996). One of the most promising natural compounds is azadirachtin, an active compound extracted from the neem tree (*Azadirachta indica*), whose antiviral, antibacterial and antifungal properties have been known for several years (Isman *et al.*, 1990; Harikrishnan *et al.*, 2003; ICAR, 1993). It is generally considered less harmful to the environment than other more commonly used pesticides (Mordue [Luntz] and Blackwell, 1993). Therefore, neem-based insecticides are being investigated as alternatives to synthetic insecticides for the control of agricultural insect pests. However, adverse effects of azadirachtin against beneficial organisms have been reported (Schmutterer and Holst, 1987; Beckage *et al.*, 1988; Hoelmer *et al.*, 1991; Price and Schuster, 1991). Neem has also been used successfully in aquaculture systems to control fish predators (Dunkel and Ricilards, 1998). Martinez (2002) stated that aqueous extract of neem leaves and other neem-based products have been extensively used in fish-farms as alternative for the control of fish parasites and fish fry predators such as dragon-fly larvae.

\*Corresponding author: Vaishali S. Panchwate Tinkhede,  
Department of Zoology, Mahatma Fule Senior College, Warud,  
Amravati, Maharashtra, India.

## MATERIALS AND METHODS

The fresh water cat fishes *Heteropneustes fossilis* were collected from the local 'Wadali. lake' near Amravati. The fishes measuring about 15-20 cm length and weighing ranges from 25-100 gm in weight were selected for the experimental study. They were disinfected with 0.1% KMNO<sub>4</sub> solution to avoid fungal infection. These collected fishes were maintained in glass aquaria containing tap water for acclimatization to laboratory conditions at room temperature for one week. The fish were fed with locally available artificial food for once in a day but were not fed 48 hours prior to the test. Water of aquarium was changed regularly. The water analysis is performed according to APHA (1975). The aquarium water was aerated continuously and was used for experimental purpose. For the experiment fresh water catfish *Heteropneustes fossilis* were divided into two groups with 10 fishes in each aquarium. Each group was exposed to sublethal concentration of the *Azadirachta indica* similar set up was also maintained as control. The animals were scarified for optimal concentration of biopesticide for different exposure of 24, 48, 72 and 96 Hrs. For histological studies, fishes were scarified during the exposure period of 24, 48, 72 and 96 Hrs respectively. The toxicant was renewed after fixed period.

## OBSERVATION AND RESULTS

### Histo-pathological Studies

At the beginning of the tests behavioural changes and the number of dead fish were recorded. Other external changes in the body of the fish were observed accordingly. Dead fishes were promptly removed and preserved in 10% formaldehyde. The organ gills were removed and prepared for histo pathological observation. They were fixed in Bouin's fluid for 24 hours, and washed with 70% ethanol and dehydrated through a graded series of ethanol (Schalm et al 1995, Kelly 1979). They were embedded in paraffin, sectioned at 4-5Hm; thickness stained with hematoxylin and eosin and examined using light microscope and photomicrography (Keneko, 1989). The mean physico-chemical parameters of the test concentrations (*Azadirachta indica*) on *Heteropneustes fossilis* were observed. The median lathal concentration (LC50) at 96h was computed using the probit analysis and ANOVA.

### Histo-pathological Studies

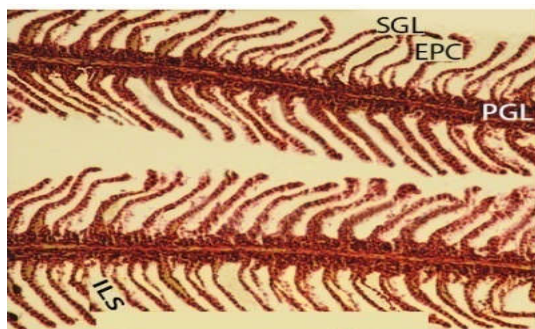


Fig - Normal Gills

**Figure :-** Showing when *Heteropneustes fossilis* was exposed to sub lethal concentration of Biopesticide *Azadirachta indica* for 24, 48, 72 and 96 hrs respectively showed the histo-pathological alternation.

During the course of experiments, *Heteropneustes fossilis* was exposed to sub lethal concentration of Biopesticide *Azadirachta indica* for 24, 48, 72 and 96 hr respectively showed the histo-pathological alternation. In normal gills of *Heteropneustes fossilis* shows Primary gill lamella (PLG), secondary gill lamella (SGL), Inter lamellar space (ILS) and epithelial cells (EPC) were observed (Fig. Normal Gills) cells become active after 24 hours, swelling tips of secondary lamella (S), edema (ED) and fusion of secondary gill lamella (FS) has been observed at 24 hrs exposure of *Azadirachta indica* on fish (Fig. 24hrs.Gills).

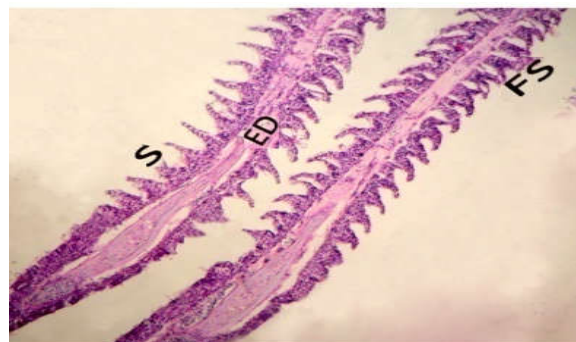


Fig - 24 hours Gills

At 48 hours exposure, damage or separation of secondary gill lamellae (SP), epithelial cell hyperplasia (H), fusion of secondary gill lamellae (F), swelling of secondary gill lamellae (S) and edema (ED), necrosis (N) were observed (Fig. 48hrs.Gills).

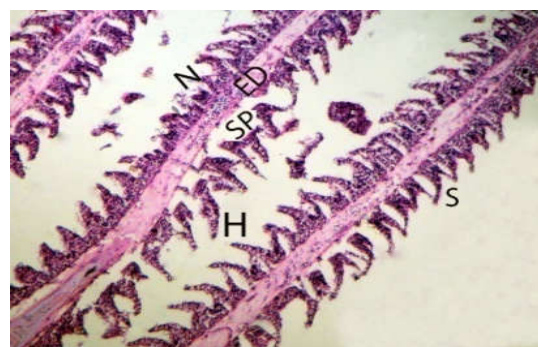


Fig - 48 hours Gills

Several apparent changes were noticed at 72 hours of exposure. This of secondary gill lamella were Shorten (SS) and excessive mucous secretion (EMC) are also seen, edematous separation of the epithelial layer i.e. epithelial cell hyperplasia (H) with necrotic cells (N) occupying the inter lamellar space. Further onwards, volume of pillar cells was found to be increased. Vacuolization and hemorrhage was very prominent (Fig. 72hrs.Gills).

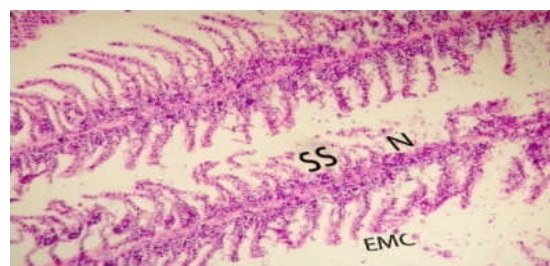

Fig - 72 hours Gills

At 96 hours of exposure, secondary gill lamella were completely slogged off leading to the abnormal raising or swelling of the epithelium as well as fusion of secondary gill lamella, shrinkage (SH) and curling (C) of secondary gill lamellae, epithelial necrosis, vacuolization and degeneration of cartilaginous bar (DCB) has been observed. In 96 hrs at some places gill lamellae are completely degenerated and the filament tips become naked due to loss of epithelium (Fig. 96hrs.Gills)

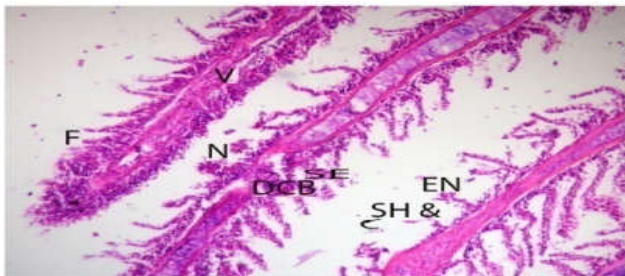

Fig - 96 hours Gills

## DISCUSSION

*Heteropneustes fossilis* exposed to sub lethal concentration of Biopesticide *Azadirachta indica* showed the tissue damages in gill structure. A gill is a respiratory organ that extracts dissolved oxygen from water and excretes carbon dioxide. The gills of vertebrates typically develop in the walls of the pharynx, along a series of gill slits opening to the exterior. Most species employ a countercurrent exchange system to enhance the diffusion of substances in and out of the gill, with blood and water flowing in opposite directions to each other. The gills are composed of comb-like filaments, the gill lamellae, which help increase their surface area for oxygen exchange (Radaiah and Rao 1990). In normal gills of *Heteropneustes fossilis* shows Primary gill lamella, secondary gill lamella, Inter lamellar space and epithelial cells were observed but with increase exposure, the damage or separation of secondary gill lamellae, epithelial cell hyperplasia, fusion of secondary gill lamella, swelling of secondary gill lamellae and edema, necrosis, hyperplasia, degeneration of cartilaginous bar was observed. These observations are in well agreement with Birgit (2007), Mosta- Fa and El-Deeb (2002), Camargo and Martinez (2007) and Banae *et al.* (2011), So finally, it is doubtless that *Azadirachta indica* that is Neem is very beneficial plant because its products are believed to have several medicinal values. The Neem is one of the best pesticides which shows very less hazards to environment. But the present study on *Heteropneustes fossilis* and previous research made on the aquatic organisms especially fresh water fishes proved the hazardous effects of *Azadirachta indica* on stress management, behavior and histological studies.

## Conclusion

So finally, it is doubtless that *Azadirachta indica* that is Neem is very beneficial plant because its products are believed to have several medicinal values. The Neem is one of the best pesticides which shows very less hazards to environment. But the present study on *Heteropneustes fossilis* and previous research made on the aquatic organisms especially fresh water fishes proved the hazardous effects of *Azadirachta indica* on histology of gills So, in future there is need of more research to assess the purported benefits of Neem which is a *Kalpavriksha* for all the mankind.

## Acknowledgements

This project was supported by Respected Dr.V.T.Tantarpale, Vidya Bharti Collage, Amravati.

## REFERENCES

- APHA. 1975. Methods for examination of water and waste water. 14<sup>th</sup> edition. American Public Health Association, Washington.
- Banae Banae M, Sureda A, Mirvaghefi AR, Ahmadi K 2011. Effects of diazinon on biochemical parameters of blood in rainbow trout (*Onchorhynchus mykiss*). Pest. Biochem. Physiol. 99:1-6.
- Beckage N. E., Metcalf, J. S., Nielson, B. D. and D. J., Nesbit 1988. Disruptive effects of azadirachtin on development of *Cotesia congregata* in host tobacco hornworm larvae. Arch. Insect Biochem. Physiol. 9: 47-65.
- Camargo, M.M. and C.B. Martinez, 2007. 10: 2106-2122. Histopathology of gills, kidney and liver of a Neotropical fish caged in an urban stream. Neotrop. Ichthyol., 5: 327-336.
- Casida J.E., Gammon D.W., Glickman A.H. and L.J. Lawrence 1983. Mechanism of pyrethroid insecticides. Ann. Rev. Pharmacol.Toxicol.
- Dunkel F.V. and D.C., Ricilards (1998). Effect of an azadirachtin formulation on six non target aquatic macroinvertebrates. Environ.
- Elliot M 1977. Synthetic Pyrethroids. American Chemical Society, Washington pp.1-28.
- Harikrishnan R., Rani, M. N. and C., Balasundaram, (2003). Hematological and biochemical parameters in common carp, *Cyprinus carpio*, following herbal treatment for *Aeromonas hydrophila* infection. Aquaculture 221: 41-50.
- Hoelmer *et al.*, 1991. Hoelmer K. A., Osborne, L. S. and R. K., Yokomi 1991. Effects of neem extracts on beneficial insects in greenhouse culture, pp. 100-105.
- ICAR 1993. World Neem Conference Souvenir ICAR, Bangalore, India. In J. C. Locke and R. H. Lawson [eds.], Proceedings. USDA Workshop. Neem Öspotential in pest management programs, 16-17 April
- Isman M. B., Koul, O., Luczyski, A. and J., Kaminski 1990. Insecticidal and antifeedant bioactivities of neem oils and their relationship to azadirachtin content. J. Agric. Food Chem., 38: 1406-1411.
- Kumar A., Prasad, M.R., Srivastava, K., Tripathi, S. and A.K., Srivastava 2010. Branchial Histopathological Study of catfish *Heteropneustes fossilis* following exposure to purified Neem Extract, Azadirachtin. World journal of zoology. 5(4): 239-243.
- Martinez S.O 2002. NIM — *Azadirachta indica*: natureza, usos múltiplos produção. Instituto Agrônômico do Paraná (IAPAR),
- Moore A. and C.P. Waring 2001. The effects of a synthetic pyrethroid pesticide on some aspects of reproduction in atlantic salmon (*Salmo salar* L.). Aquatic Toxicol. 52: 1-12.
- Mordue [Luntz], A. J., and A Blackwell, 1993. Azadirachtin: an update. J. Insect Physiol. 39: 903
- Mosta- Fa BB, El-Deeb FA 2002. Impact of certain plants and synthetic molluscicides in some fresh water snails and fish. Sci. Total Environ. 35 (3):989-1007.
- Price J. F. and D.J., Schuster 1991. Effects of natural and synthetic insecticides on sweetpotato whitefly *Bemisia tabaci* (Homoptera: Schalm et al 1995, Schalm

- OW, Jain NC, Carrol EJ 1995. Veterinary haematology, 3rd Ed., Philadelphia, Leaard Febiger pp.15-81. , 1990, USDA-ARS, ARS-86. USDA, Beltsville, MD. 23: 413–418Aleyrodidae) and its hymenopterous parasitoids. Fla. Entomol. 74: 60-68.
- Schmutterer H., and H., Holst, 1987. On the effects of the enriched and formulated neem seed kernel extract AZTVR-K on *Apis mellifera* L. J. Appl. Entomol. 103: 208–213
- Singh N.N. and V.K., Dass 2010. Acute toxicity and behavioral responses of common carp *Cyprinus carpio* (Linn.) to an Organophosphate (Dimethoate). World Journal of Zoology. 5 (3): 183-188.
- Smith T.M. and G.M. Stratton 1986. Effects of synthetic pyrethroid insecticides on nontarget organisms. Residue Rev. 97: 93–119.
- Wan M.T., Watts, R.G., Isman, M.B. and R., Strub 1996. Evaluation of the acute toxicity to juvenile pacific northwest salmon of azadirachtin, neem extract, and neem based products. Bull. Environ. Contam. Toxicol., 56: 432–439.

\*\*\*\*\*