



ISSN: 0975-833X

Available online at <http://www.journalcra.com>

International Journal of Current Research
Vol. 10, Issue, 12, pp.75954-75959, December, 2018

DOI: <https://doi.org/10.24941/ijcr.30812.12.2018>

INTERNATIONAL JOURNAL
OF CURRENT RESEARCH

RESEARCH ARTICLE

TWO MINIPLATE VERSUS ONE LARGE PLATE IN THE TREATMENT OF MANDIBULAR SYMPHYSIS/BODY FRACTURE

*Ateeq, M.A., Suresh Kumar, M., Konda Amarnath, Visalakshi, G.

Department of Oral and Maxillofacial Surgery, Meghna Institute of Dental Sciences, Mallaram, Nizamabad

ARTICLE INFO

Article History:

Received 22nd September, 2018
Received in revised form
27th October, 2018
Accepted 03rd November, 2018
Published online 29th December, 2018

Key Words:

Two Miniplates, One Large Plate,
Mandibular Symphysis and Body
Fractures.

ABSTRACT

Aim: To compare and evaluate the efficacy of two miniplate and one large plate in treatment of mandibular body and symphysis fractures. **Materials and Methods:** A Prospective cohort study was performed on patients who were surgically treated for mandibular fractures from the year 2015 to 2017. The primary predictor variable was fixation technique, which was conventional 2.0 two miniplates and one large plate with bicortical locking screws. The outcome variables were complications, stability and wound dehiscence. **Results:** Out of 20 cases 10 were included under Group A and 10 under Group B. In Group A patients were treated with two miniplates and in Group B patients were treated with one large plate. There were no statistically significant differences in occlusal or osseous healing outcomes. However, there were significant differences in treatment outcomes for several variables, including wound dehiscence, plate exposure, the need for plate removal, and tooth root damage between the groups. **Conclusion:** The use of 2 miniplates was associated with more postoperative complications than the use of 1 stronger plate, but both techniques produced sufficient stability for healing

Copyright © 2018, Wisam Al-Hathlol et al. This is an open access article distributed under the Creative Commons Attribution License, which permits unrestricted use, distribution, and reproduction in any medium, provided the original work is properly cited.

Citation: Ateeq, M.A., Suresh Kumar, M., Konda Amarnath, Visalakshi, G. 2018. "Two miniplate versus one large plate in the treatment of mandibular symphysis/body fracture", *International Journal of Current Research*, 10, (12), 75954-75959.

INTRODUCTION

Injuries to the maxillofacial region are clinically highly significant as they affect both function and esthetics. There is often a psychological aspect associated with the injury secondary to patients concern regarding permanent scarring and subsequent facial disfigurement. Increased urbanization, improved transport systems and use of sophisticated motor vehicles has led to an increase in the number of trauma cases over the years. Fractures of mandible are the most common bone injuries because of its prominence and exposed position within the facial skeleton accounting for 23% - 97% of all facial fractures². A Fracture may be defined as "a sudden, violent solution of continuity of bone and may be complete (or) incomplete in character" and Trauma may be defined as "a physical force that results in injury"³. The most common mechanisms of injury to mandible include interpersonal violence, motor vehicle crashes, falls, fights and sport injuries. The parasymphysis and body region of the mandible are more prone for fractures. The main aim of treating a fracture was to reduce the fracture segment followed by stabilization of fractured fragments. The age old practice as ancient as 500BC by Sushruta to modern concept of traumatology is use of various aids to

reduce fracture and stabilize the fractured fragments by using various aids like bamboo sticks and glue like material to wiring to use of miniplates in the modern traumatology.

Aim of the study: The purpose of this study was to evaluate outcomes in patients treated by application of 2 small miniplates or 1 larger plate in the management of fractures of mandibular symphysis/body.

Objectives

- Evaluate clinical result of 1 larger plate with bicortical screws in stabilization of fractured segments, need for intermaxillary fixation.
- To assess the efficacy of stability and rigidity of 1 larger plate in osteosynthesis.
- To demonstrate the biocompatibility of 1 larger plate with surrounding bone and soft tissues.
- To compare the above objectives with conventional miniplate

Armamentarium

MATERIALS AND METHODS

The study was carried out in the Department Of Oral And Maxillofacial Surgery, Meghna Institute of Dental Sciences, Mallaram, Nizamabad-Dist, Telangana

*Corresponding author: Ateeq, M.A.,
Department of Oral and Maxillofacial Surgery, Meghna Institute of Dental
Sciences, Mallaram, Nizamabad.

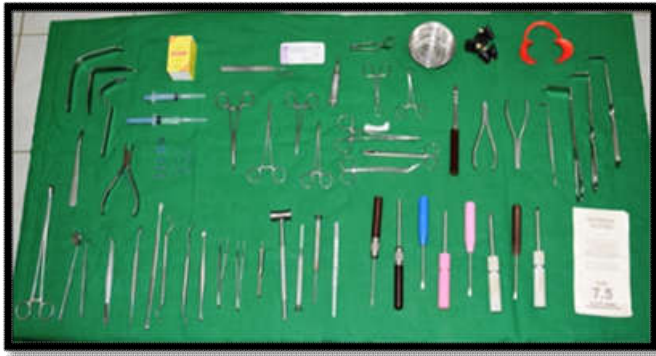

Fig. 1. Aramamentarium

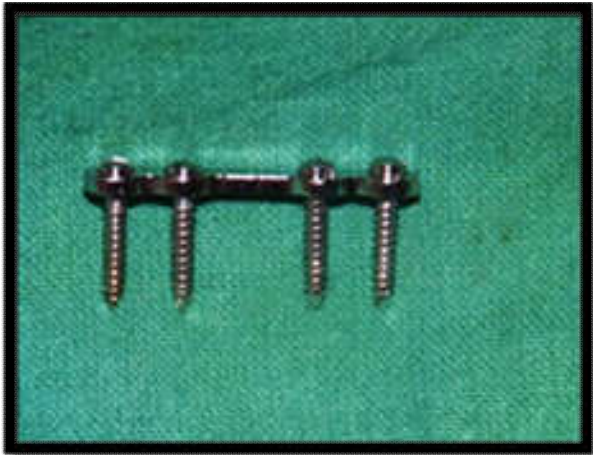

Fig. 2. Bicortical Locking Plate




Fig. 3. Conventional stainless steel mini plates

The study was designed to compare “2 bone plating methods for fractures of mandibular symphysis/body”.

Inclusion Criteria

- Simple (linear, non-comminuted) fracture of symphysis and body of the mandible.
- Tooth present in area of fracture.
- No post-operative intermaxillary fixation required

Exclusion Criteria

- Severely infected fractures with large hematoma.
- Grossly comminuted fractures with extensive damage of fractured bony segments.

- Medically compromised patients.

Sample Size:- 20 patients divided in two groups.

Group A:- 10 Patients were treated for fracture of mandibular symphysis/body with conventional stainless steel miniplates.

Group B:- 10 Patients were treated for fracture of mandibular symphysis/body using stainless steel large plate with bicortical locking screws.

Surgical technique:- Patients were operated under anesthesia (General/Local). Strict asepsis was followed.

Intra-oral approach was used in majority of cases Extraorally either Submental (or) Submandibular (or) Existing laceration/incision was placed. Blunt dissection was performed, periosteum was incised leading to exposure of fractured fragments. Anatomical reduction of fracture fragments was done followed by intermaxillary fixation with the help of tie wires. Bone plates were placed along the lines of osteosynthesis as described by Champy. Fixation in GROUP-A patients was done using conventional stainless steel miniplates 2 in no. and fixation in GROUP-B was done using stainless steel large plate with bicortical screws. After bone plate fixation intermaxillary fixation was released and occlusion checked, soft tissue closure done in layers. Patients were followed up for evaluation of parameters at 1st, 7th, 30th and 90th day.

Parameters used for evaluation:

The parameters used were

Grading system for various parameters:

Clinical parameters

Stability of occlusion

- Satisfactory - no gap between upper and lower first molar.
- Mildly deranged - gap of 1-2 mm between upper and lower first molar.
- Deranged - gap more than 2mm between upper and lower first molar.

Mobility of fracture fragments

- Stable – no movements of fragments.
- Unstable – movement of fragments present.

Wound dehiscence

- Absent.
- Present

Infection

- Absent.
- Present

Damage to tooth roots

- absent
- present

Neurological deficit scale

- absent.
- present.

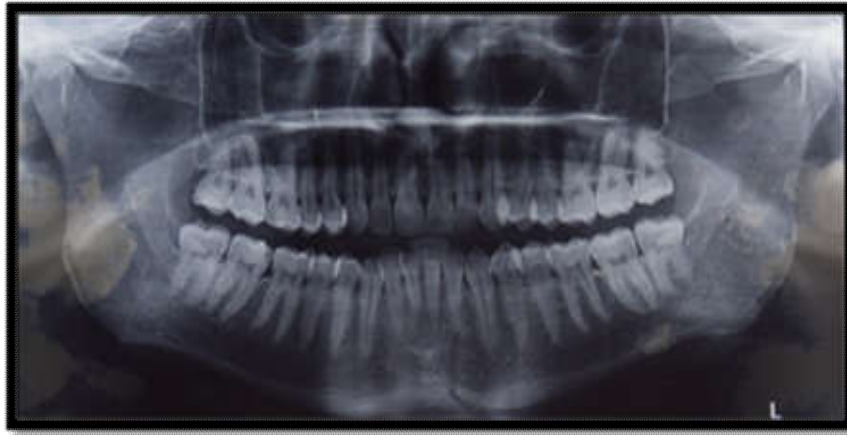

Fig. 4. Pre Operative Radiograph

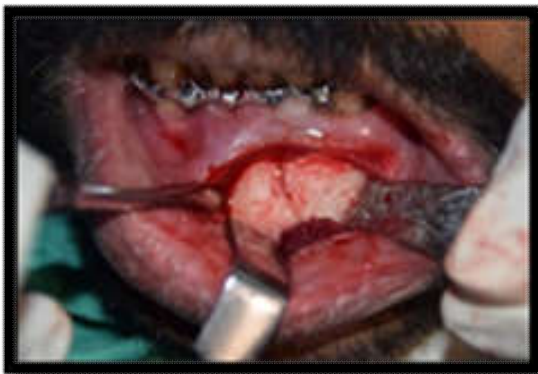

Fig. 5. Exposure of fracture site

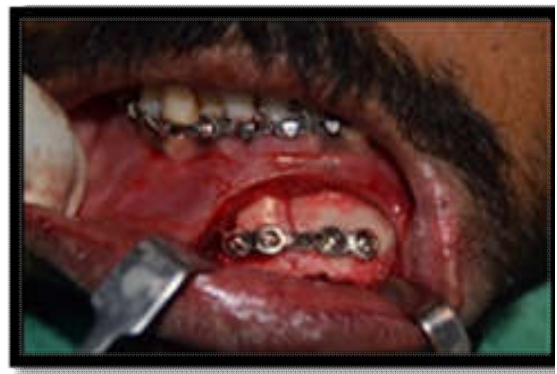

Fig.6 Fixation using bicortical locking plate

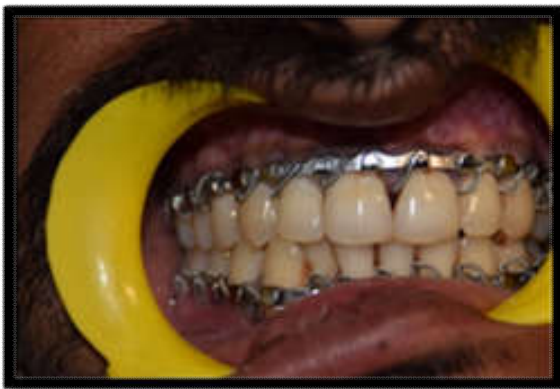

Fig. 7. Post operative occlusion

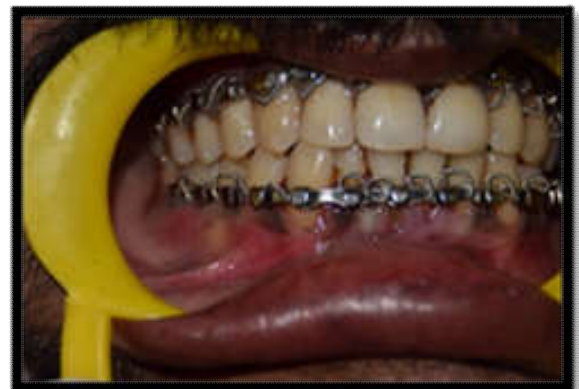

Fig. 8. Post operative occlusion

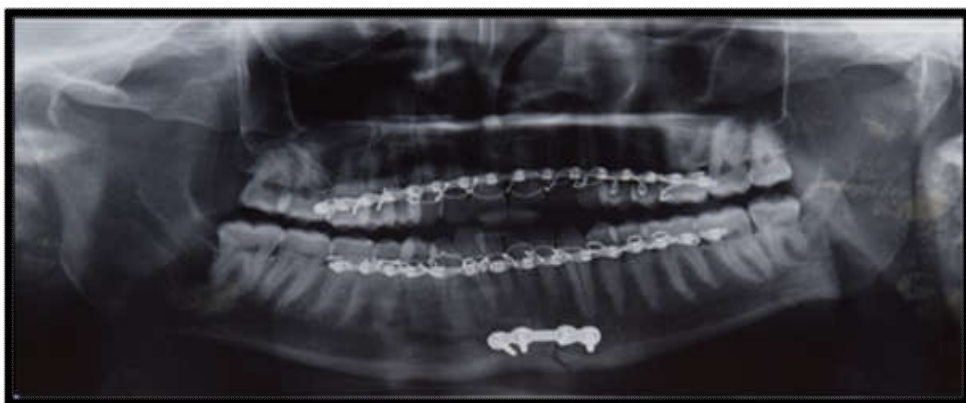

Fig. 9. Post Operative Radiograph

Table 1. Clinical parameters compared

Clinical parameters	Radiographic parameters
Infection	Displacement of fracture fragments
Wound dehiscence	Plate fracture at different time intervals
Damage to tooth roots	
Stability of fractured segments	
Malocclusion	
Neurologic deficit	
Exposure of bone plates	

Table 2. Stability of occlusion

Stability of occlusion	Pre-Operatively		1 st day Post-Op		7 th Day post-op		30 th Day post-op		90 th Day post-op	
	Severely Deranged	Mildly Deranged	Mildly Deranged	Satisfactory	Mildly Deranged	Satisfactory	Mildly Deranged	Satisfactory	Mildly Deranged	Satisfactory
Group-A	05	05	03	07	1	9	-	10	-	10
Group- B	07	03	07	03	03	07	-	10	-	10
Total	12	08	10	10	04	16		20		20

Table 3. Mobility of fracture segment

Mobility of Fracture Segment	Pre-operatively		1 st Day Post-OP		7 th Day Post-OP		30 th Day Post-OP		90 th Day Post-OP	
	Present	Absent	Present	Absent	Present	Absent	Present	Absent	Present	Absent
Group-A	08	02	01	09	-	10	-	10	-	10
Group- B	08	02	01	09	-	10	-	10	-	10
TOTAL	16	04	02	18	-	20	-	20	-	20

Wound dehiscence (W.D)

Infection (I)

Neurological deficit (N.D)

Table 4. . Wound dehiscence, infection and neurological deficit

W.D INF. N.D	Pre-Operatively			1 st Day Post-OP			7 th Day Post-OP			30 th Day Post-OP			90 th Day Post-OP		
	W.D	I	N.D	W.D	I	N.D	W.D	I	N.D	W.D	I	N.D	W.D	I	N.D
GROUP-A	-	-	05	-	-	05	-	-	04	-	-	-	-	-	-
GROUP-B	-	-	07	-	-	07	1	-	06	-	-	01	-	-	-
TOTAL	-	-	12	-	-	12	1	-	10	-	-	01	-	-	-

Wound dehiscence (W.D)

Infection (I)

Neurological deficit (N.D)

Table 5. Exposure of bone plate

Exposure of Bone Plate	Pre-Operatively		1 st day		7 th Day		30 th Day		90 th Day	
	Present	Absent	Present	Absent	Present	Absent	Present	Absent	Present	Absent
Group-A	-	-	-	10	-	10	-	10	-	10
Group- B	-	-	-	10	-	10	-	10	-	10
Total	-	-	-	20	-	20	-	20	-	20

RADIOLOGICAL PARAMETERS**Table 6. Tooth In Fracture Line**

Tooth in a line of fracture	GROUP-A	GROUP-B
Present	04	06
Absent	06	04
Total	10	10

Table 7. Displacement of fracture segments

Displacement of Fracture Segments	Pre-Operatively		1 st Day Post-OP		7 th Day Post-OP		30 th Day Post-OP		90 th Day Post-OP	
	Severely displaced	Displaced	Displaced	Undisplaced	Displaced	Undisplaced	Displaced	Undisplaced	Displaced	Undisplaced
Group-A	05	05	01	09	-	10	-	10	-	10
Group- B	07	03	03	07	01	09	-	10	-	10
Total	12	08	04	16	01	19		20		20

Exposure of bone plate (at different time intervals)

- absent
- present

Radiographic Parameters

Displacement of fracture segments

- Undisplaced
- Displaced (less than 5 mm)
- Severely displaced (greater than 5 mm)

Plate fracture at different time interval (IMPLANT FAILURE)

- Absent.
- Present

RESULTS

Clinical Parameters

Stability of Occlusion: Occlusion of the patient was evaluated preoperatively and post operatively 1st,7th,30th and 90th day.

Mobility of fracture fragments: Comparison between both the groups with respect to mobility of fracture fragments at the time interval pre-operative and post operatively 1st,7th,30th and 90th day.

Wound Dehiscence

Infection (mal union/non-union)

Neurological deficit: Comparison between both the groups with respect to Wound Dehiscence, Infection, Neurological Deficit at the time interval pre-operative and post operatively 1st,7th,30th and 90th day.

Exposure of bone plate

Tooth in a line of fracture: Comparison between both the groups for Tooth in the line of fracture pre-operatively.

Displacement of fracture segments: Comparison between both the groups for Displacement Of Fracture Segments at the time interval pre-operative and post operatively 1st,7th,30th and 90th day.

Plate fracture at different time interval: Comparison between both the groups with respect to Plate Fracture at the time interval pre-operative and post operatively 1st,7th,30th and 90th day

DISCUSSION

Over the past 100 years, many achievements have been made in the care of victims of Maxillofacial trauma. The main goal in the treatment of fracture is to restore pre injury anatomical form, with associated aesthetics and function. The goal must be accomplished by means that will produce the least disability, risk and shortest recovery period for the patient⁴. Two schools of thought emerged. The first, proposed by the AO=ASIF (Arbeitsgemeinschaft für Osteosynthesfragen=Association for the Study of Internal Fixation), required rigid stability with strong plates and screws and compression for primary healing (Luhr, Spiessl). The other was the use of small, semirigidnoncompression plates placed along the lines of ideal osteosynthesis on the mandible (Champy, Michelet). Both systems have produced good clinical results, though the use of smaller plates is currently more popular⁵. Champy performed a series of experiments with miniplate that delineated “ideal lines of osteosynthesis” within the mandible. Plates placed along these lines were thought to provide optimal fixation and stability. Ideal plate placement for angle fractures was along the superior border of the mandible above or just below the superior oblique ridge.

Table 8. Plate fracture

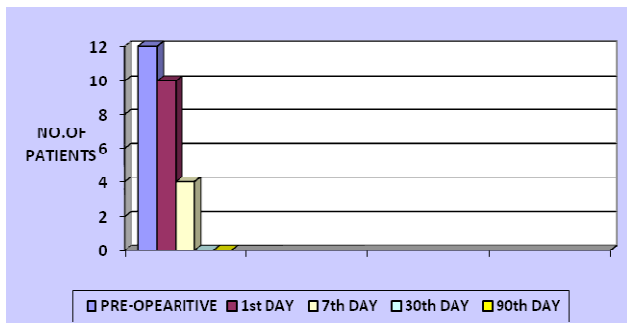
Plate fracture	Pre-Operatively		1 st Day		7 th Day		30 th Day		90 th Day	
	Present	Absent	Present	Absent	Present	Absent	Present	Absent	Present	Absent
Group-A	-	-	-	10	-	10	-	10	-	10
Group- B	-	-	-	10	-	10	-	10	-	10
Total	-	-	-	20	-	20	-	20	-	20

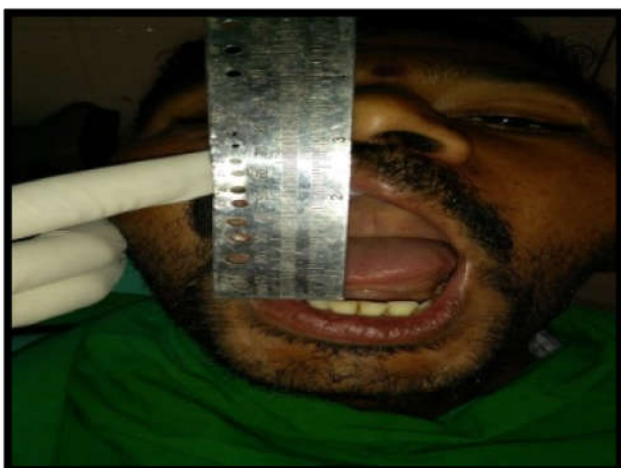

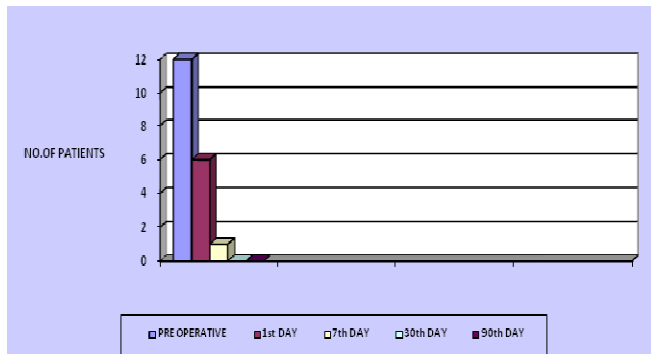
Fig . 10. Post operative mouth opening

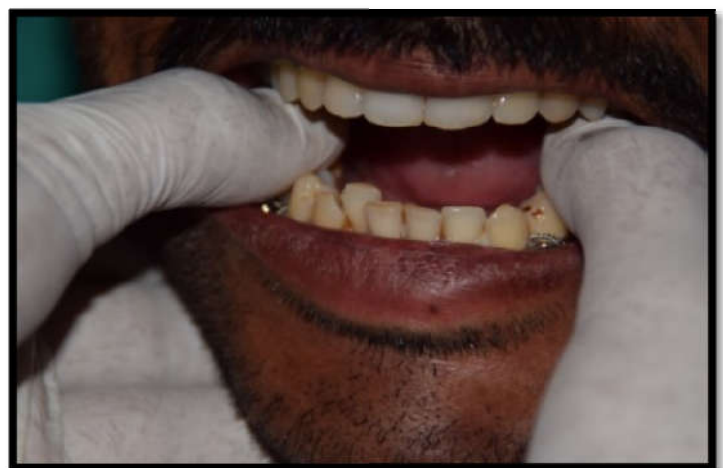

Fig .11. Post operative mobility of fracture segment



Graph 1. Assesment of Stability Of Occlusion



Graph 2. Assesment Of Displacement Of Fracture Segments

Because these plates were small and monocortical screws, placement was possible without damaging the tooth roots. Champy states that this miniplate system also gives sufficient support and stability to the bone fragments to allow immediate function. Subsequent clinical studies corroborated the effectiveness of the Champy technique (Nandini, 2011). When open reduction and internal fixation is chosen as a treatment, many internal fixation schemes can be employed. Perhaps the most common is the application of 2 small (mini) plates or 1 larger plate with or without an arch bar (Edward Ellis, 1978). There are no studies in literature comparing these 2 techniques. The selection of 1 technique over another depends on surgeons' preference, experience, availability of internal fixation hardware, or other factors rather than documented outcome measurements. The purpose of the study was to evaluate the outcomes of patients treated by 1 of these 2 internal fixation schemes for fracture of mandibular symphysis/body (Edward Ellis, 1978).

Summary and conclusion

This study was designed with an aim of evaluating the efficacy of 1 large thick plate compared to 2 miniplates in the treatment of mandibular symphysis/body, and complications encountered during their use were also recorded and reported in this study. Total of twenty patients with mandibular fractures, were treated using 1 large plate and 2 miniplates in our study. The resulting osteosynthesis were evaluated with the scoring system for 9 parameters and complications in the procedures were noted.

The following inferences could be drawn from the study:

- Larger thicker plates stabilize the bone fragments. Due to better inter-fragmentary stability, supplemental fixation in the form of IMF/MMF is not necessary, thereby enhancing the overall comfort, convenience and wellbeing of the patients.
- Larger thicker plate holds the fracture segments rigidly by resisting the forces namely shearing, bending and torsional forces occurring on the fracture site in function.
- Our clinical results and biomechanical investigations have shown a good stability of the 1 larger plates in the osteosynthesis of mandibular fractures without major complications.
- In summary, the 2 plating techniques used in the present study show very good outcomes, but the application of a second bone plate increased the incidence of wound dehiscence, plate exposure, and need for plate removal.
- All the patients in our study appreciated early recovery of normal jaw function, uneventful healing and good union at the fracture site with minimal weight loss due to early reinstatement of the masticatory function. There was great patient acceptance of this treatment modality.
- 1 larger plate were indeed easy and simple to use. Significant reduction in operating time could be achieved with the use of 1 plate which makes it a time-saving alternative to conventional miniplates.

REFERENCES

- Anshul J. Rai, Abhay N. Datarkar, Rajeev M. Borle. 2009. Customised screw for intermaxillary fixation of maxillofacial Injuries. *British Journal of Oral and Maxillofacial Surgery* 47 325–326.
- Cawood JI. 1985. Small plate osteosynthesis of mandibular fractures. *Br J Oral Maxillofac Surg.*, 23:77.
- Edward Ellis III A Study of 2 Bone Plating Methods for Fractures of the Mandibular Symphysis/Body: *J Oral Maxillofac Surg* 69:1978-1987, 2011
- Hashemi HM., Parhiz A. 2011. Complications using intermaxillary fixation screws. *J Oral Maxillofac Surg.* May;69(5):1411-4.
- Johnathan D. McGinn, Fred G. Fedok. 2008. Techniques of maxillary – mandibular fixation: Operative Techniques in *Otolaryngology* 19, 117-122.
- Mukherji, R., Mukerji G. et al. 2006. Mandibular fractures: Historical perspective *British Journal of Oral and Maxillofacial surgery* 44 222-228.
- Nakamura S., Takenoshita Y., Oka M. 1994. Complications of miniplate osteosynthesis for mandibular fractures. *J Oral Maxillofac Surg.*, 52:233.
- Nandini, G. D., Ramdas Balakrishna, Jyotsna Rao. 2011. Self Tapping Screws v/s Erich Arch Bar for Inter Maxillary Fixation: A Comparative Clinical Study in the Treatment of mandibular fractures *J. of maxillofac oral surg.* 10[2]: 127-131.
