



CASE STUDY

LAPAROSCOPIC TRACHELECTOMY FOR CERVICAL STUMP WITH CIN3 AND PERSISTANT PELVIC PAIN FOLLOWING SUBTOTAL HYSTERECTOMY

*Chandil, N., Manchanda, R., Sharma, R.

ICOG Fellow at MEC, PSRI Hospital, New Delhi, India

ARTICLE INFO

Article History:

Received 27th May, 2018
Received in revised form
20th June, 2018
Accepted 16th July, 2018
Published online 30th August, 2018

Key Words:

Laparoscopic Trachelectomy

ABSTRACT

A P3L3,39 yr old women had history of total abdominal hysterectomy for dysmenorrhea with ASCUS on pap smear in 2013 in Nigeria presented to us with severe pain abdomen and bleeding from last 3 yr. Bleeding was irregular, occur every 2-3 month. On diagnostic hysteroscopy and laparoscopy, remnant of uterus along with cervix and right ovary and fallopian tube was found. So, laparoscopic removal of remnant uterus and cervix with right salpingoophorectomy done under GA on 29-6-18. Here auther wish to enlighten the ease of visualization and operability along with clarity of anatomy during laparoscopic trachelectomy following subtotal hysterectomy.

Copyright © 2018, Chandil et al. This is an open access article distributed under the Creative Commons Attribution License, which permits unrestricted use, distribution, and reproduction in any medium, provided the original work is properly cited.

Citation: Chandil, N., Manchanda, R., Sharma, R. 2018. "Laparoscopic Trachelectomy for Cervical stump with CIN3 and Persistant pelvic pain following subtotal hysterectomy", *International Journal of Current Research*, 10, (08), 72435-72437.

INTRODUCTION

Cervical stump extirpation or trachelectomy is the removal of the cervix following supracervical hysterectomy. Subtotal or supracervical hysterectomy is an alternative to total hysterectomy (removal of uterine fundus and cervix) in women undergoing hysterectomy for many benign indications. The laparoscopic removal of a cervical stump following a supra cervical (subtotal) hysterectomy was first described by Nezhat *et al.* (1996)¹. The advantages of the laparoscopic approach are stump adhesiolysis, assesment and removal of adnexa satisfactorily, adequate postoperative vault support, and assessment of the pelvic lymph nodes.

Case report

39 yr old P3L3 female presented with severe pelvic pain and bleeding from last 3 year. She had history of total abdominal hysterectomy done in Nigeria for dysmenorrhea and ASCUS on pap smear in 2013. On general examination, pt was well built, well nourished and hydrated. No pallor/cyanosis /clubbing/oedema /lymphadenopathy. Vitals were stable. Cardiovascular, central nervous system and Respiratory systems were normal. Abdomen was soft, non tendar with no hepatospeenomegaly.

There was a right paramedian scar present of previous surgery. A hypertrophied cervix was present on speculam examination. Uterus felt small ? 5-6 cm, AV with clear B/L fornix on bimanual examination. PAP smear was taken, later reported as ASCUS. Cervix is well visualized (4.0×2.9 cm) and shows multiple nabothian cyst (1.8×1.6 cm) on ultrasound. A small uterine stump is also visualized (1.2 cm) with thin endometrial echoes (2.9 mm).Right ovary shows multiple follicles with a cyst measuring 2.6 ×2.0 ×1.4 cm with multiple septation ? hemorrhagic cyst. Left ovary is not visualized on USG. On diagnostic hysteroscopy (Fig 1) cervical canal was normal but elongated, uterine fundus and bilateral ostia were not seen. Small lower uterine segment with some amount of endometrium was present. on the basis of clinical examination, USG and hysteroscopy ,diagnosis of Persistant vaginal bleeding and pelvic pain following subtotal/supracervical hysterectomy with ASCUS was made and pt opted for laparoscopic trachelectomy with salpingoophorectomy. Her laparoscopic findings (Fig 2) reveals partial uterus and cervix along with right sided ovary and fallopian tube was present. Left sided fallopian tube and ovary was absent. Right ovary is enlarge and cystic. Bowel and omentum was adhered to anterior abdominal wall. Removal of remnant of uterus and cervix (Fig 3) with bilateral salpingoophorectomy was done under GA on 29-6-18. Her histopathology report shows full thickness atypia in cervical tissue suggestive of high grade sqamous intraepithelial lesion (CIN3) and hemorrhagic corpus luteal cyst in right ovary.

*Corresponding author: Chandil, N.,
ICOG Fellow at MEC, PSRI Hospital, New Delhi, India
DOI: <https://doi.org/10.24941/ijcr.32014.08.2018>

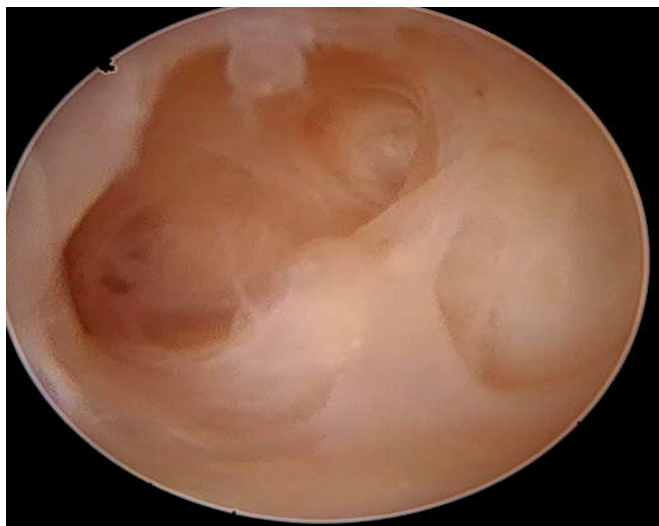

Fig. 1. Hysteroscopic picture

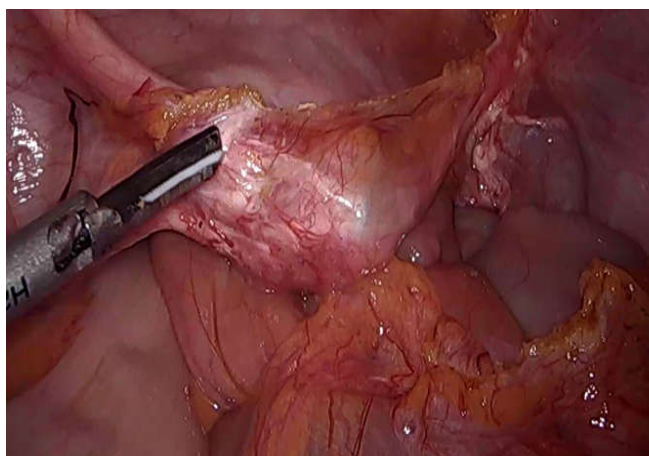


Fig 2. Laparoscopic findinds

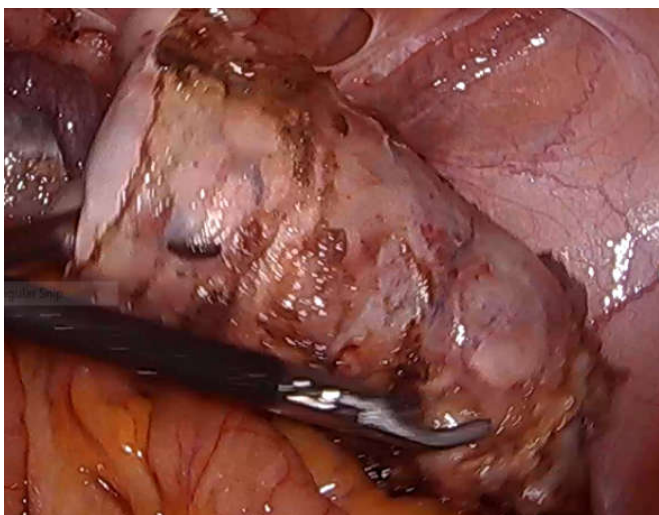


Fig 3 Trachelectomy specimen

DISCUSSION

Although supracervical hysterectomy involves shorter surgical time, lower blood loss and lower ureteric injury, It has also been associated with problem related to cervical stump like persistent cyclic menstrual bleeding (0 % to 25 %) and pelvic pain after surgery. Development of cervical stump carcinoma

that is estimated to occur in less than 1% of patients may be a grievous outcome of subtotal hysterectomy. Sasaki *et al.* (2014)² were conducted a retrospective study on persistant bleeding after laparoscopic supracervical hysterectomy from 2003 to 2012 concluded that young women and those with endometriosis were more likely to have post operative bleeding at more than 12 week . In this present case, indication of her previous supracervical hysterectomy was adenomyosis, this favour the possibility of remnant endometriotic tissue on cervical stump resulting vaginal bleeding after surgery. Ghomi *et al.* (2005) conducted a study on incidence of cyclical bleeding after laparoscopic supracervical hysterectomy concluded that overall incidence of post LSH cyclical bleeding is 19% and this may be reduced to 17% when uterus is amputated at or below the level of internal os . In this present case amputation of uterus was done above the level of internal os (diagnosed on hysteroscopy and usg), which may be responsible for postoperative cyclical bleeding. The incidence of cervical stump carcinoma within 10 year after subtotal hysterectomy has been estimated to be between .5% to 1.0% (Jeffcoate, 1967). Some has reported 3% (Storm *et al.*, 1992)⁵ to 11% (Kilkku *et al.*, 1982)⁶. In this present case histopathology report confirmed CIN III in resected specimen. NICE guideline (ipg239)⁷ of laparoscopic technique for hysterectomy mentioned a case series of 1405 women undergoing LSH develop symptoms related to cervical stump and adenomyosis included pelvic pain and deep dyspareunia between 2 and 9 years after LSH. Laparoscopic surgery was required to make a final diagnosis and to remove them.

Conclusion

Persistant pelvic pain and bleeding is more commonly occur in young women those with endometriosis or adenomyosis underwent supracervical hysterectomy. Stump carcinoma is one of the grievous outcome of supracervical hysterectomy. Ease of operability and adhesiolysis, clarity of anatomy because of magnified view, decrease morbidity and expeditious recovery in post op period can be achieved with skilled laparoscopic trachelectomy

Recommendation

Younger patients and those with endometriosis who desired to have no further vaginal bleeding may benefit from total hysterectomy over supracervical hysterectomy. Subtotal hysterectomy should not be offered in populations at risk of developing cancer of the uterine cervix. Specials attention should be paid to cervical stump following subtotal hysterectomy. Laparoscopic trachelectomy is a valuable means of achieving safe and reproducible outcome hence should be preffered over abdominal or vaginal route.

REFERENCES

1. Nezhat, CH., Nezhat, F., Roemisch, M., Seidman, DS. and Nezhat, C. 1996. Laparoscopic trachelectomy for persistent pelvic pain and endometriosis. *Fert Steril.*, 66:925-8.
2. Sasaki, K.J., Singh, A.C., Sulo, S. and Miller, C.E. 2014. Persistent Bleeding After Laparoscopic Supracervical Hysterectomy. *JSLs* October-December; Volume 18 Issue 4 e2014.002064 1.

3. Ghomi, A., Hantes, J. and Lotze, E.C. 2005. Incidence of cyclical bleeding after laparoscopic supracervical hysterectomy. *JMIG* 12, 201-205.
4. Jeffcoate, TNA. 1967. Principles of Gynecology. London ; Butterworths.
5. Storm, HH., Clemmenson, IH., Manders, T. and Brinton, LA. 1992. Supravaginal uterine amputation in Denmark 1978-1988 and risk of cancer. *Gynecol Oncol.*, 45:198-201.
6. Kilkku, P. and Gronroos, M. 1982. Perioperative electro coagulation of the endocervical mucosa and later carcinoma of the cervical stump. *Acta Obstet Gynecol Scand.*, 61:265-267.
7. Laparoscopic techniques for hysterectomy. Interventional procedures guidance Published: 28 November 2007 nice.org.uk/guidance/ipg239
