



ISSN: 0975-833X

Available online at <http://www.journalcra.com>

International Journal of Current Research
Vol. 10, Issue, 09, pp.73364-73369, September, 2018

DOI: <https://doi.org/10.24941/ijcr.32323.09.2018>

INTERNATIONAL JOURNAL
OF CURRENT RESEARCH

RESEARCH ARTICLE

CHRONIC SUBDURAL HAEMATOMA: A COMPARATIVE STUDY OF BURR-HOLE CRANIOTOMY AND SMALL CRANIOTOMY AS INITIAL MANAGEMENT

¹Dr. Debajyoti Pathak, ^{2,*}Dr. Kaushik Roy, ³Dr. Suniti Kumar Saha, ⁴Dr. Nakul Pahwa and ⁵Dr. Abta Bachchan

¹M.S. Gen. Surgery, MRCS, (UK), M. Ch Resident, Dept. of Neurosurgery, N.R.S. Medical College, Kolkata West Bengal, India

²M.Ch Neurosurgery, Associate Professor, Dept. of Neurosurgery, N.R.S. Medical College, Kolkata, West Bengal, India

³M.S. Ortho, M.Ch, Neurosurgery, Professor and Head of Department, Dept. of Neurosurgery, N.R.S. Medical College, Kolkata, West Bengal, India

⁴M.S. Gen. Surgery, M. Ch Resident, Dept. of Neurosurgery, N.R.S. Medical College, Kolkata, West Bengal, India

⁵M.S. Gen. Surgery, M. Ch Resident, Dept. of Neurosurgery, N.R.S. Medical College, Kolkata, West Bengal, India

ARTICLE INFO

Article History:

Received 20th June, 2018

Received in revised form

17th July, 2018

Accepted 05th August, 2018

Published online 30th September, 2018

Key Words:

Chronic Subdural Haematoma,
Small Craniotomy,
Burr-Hole Craniostomy.

ABSTRACT

Background: Despite being one of the most common pathologies encountered by a neurosurgeon, management of chronic subdural haematoma (cSDH) continues to be tricky, often requiring multiple interventions with varied complications. **Objective:** The aim of this study was to compare small craniotomy with burr-hole craniostomy as a treatment modality in evacuation of cSDH at a tertiary care Hospital. **Methods:** A retrospective study encompassing chronic subdural haematoma patients presenting to the Department of Neurosurgery, NRS Medical College & Hospital over a period of one year was performed. Patients who underwent burr-hole craniostomy or a small craniotomy were included in the study. Patients with intrahaematomal membranes or organized cSDH were selected for craniotomy. The patients were followed up during their stay in the hospital and their demographic profiles, operative duration, hospital stay, complications and prognosis were thoroughly studied. A pre-operative and post-operative clinical assessment of the patients was done using Markwalder's Grade Scale. **Results:** There was no difference in the pre-operative criteria in the two groups, however a significant difference was noted in the duration of surgery and hospital stay between the two groups. The burr-hole group also had more complications and re-operation than the craniotomy group. **Conclusion:** Small craniotomy seems to be a better alternative than burr-hole craniostomy for the management of chronic subdural haematomas with intrahaematomal membranes.

Copyright © 2018, Debajyoti Pathak et al. This is an open access article distributed under the Creative Commons Attribution License, which permits unrestricted use, distribution, and reproduction in any medium, provided the original work is properly cited.

Citation: Dr. Debajyoti Pathak, Dr. Kaushik Roy, Dr. Suniti Kumar Saha, Dr. Nakul Pahwa, Dr. Abta Bachchan, 2018. "Chronic Subdural Haematoma : A comparative study of burr-hole craniostomy and small craniotomy as initial management", *International Journal of Current Research*, 10, (09), 73364-73369.

INTRODUCTION

Chronic subdural haematoma (cSDH) has been defined as a liquefied haematoma in the subdural space with a characteristic outer and inner membrane and occurring, if known, at least 3 weeks after head injury. It is one of the most common pathological conditions presenting to the neurosurgical emergency with an incidence of 1-2 per 100,000, having a predilection for elderly age group, with a male preponderance (Fogelholm *et al.*, 1975). Although burr-hole craniostomy has been the most commonly used procedure for this condition, there has been no consensus regarding the best surgical

procedure for treating these lesions (Lee, 2009). We hereby report our experience with burr-hole craniostomy and small craniotomy in the management of cSDH at our institute in this study.

MATERIALS AND METHODS

A retrospective study was performed using the data over 1 year, from 1st of August, 2017, at the Department of Neurosurgery, NRS Medical College and Hospital. Computed tomography (CT) scan was the primary imaging modality in the study population. Burr hole craniostomy with subgaleal suction drain for 48 hours was done in those patients who had no evidence of non-liquefied haematoma without any septations.

*Corresponding author: Dr. Kaushik Roy,

M.Ch Neurosurgery, Associate Professor, Dept. of Neurosurgery, N.R.S. Medical College, Kolkata, West Bengal, India.

However, patients with mixed density or hyperdense lesions, intrahaematoma membranes, organized or calcified cSDH and those with recurrence were selected for a small craniotomy. A craniotomy of diameter 3-4 cm was performed centering the most prominent part of the haematoma. The dura was cut in a cruciate manner. The outer membranes were removed. The haematoma cavity was repeatedly irrigated with normal saline until the effluent was clear. The inner membrane was left undisturbed, except in two cases where there was underlying collection of blood breakdown products and there was no expansion of the brain. In these cases the inner membrane was sharply incised with the tip of a no. 23 needle, and separated from the underlying arachnoid by hydro-dissection. On completing the procedure proper hemostasis was ensured and the tips of the dural flaps were apposed. The dural cut margins were properly coagulated. The bone flap was replaced and secured with absorbable sutures. Skin and galea were closed over a 14 Fr. suction drain. Neurological assessment of the patients was preoperatively and postoperatively evaluated by "Markwalder's Neurological Grading System", the most commonly used neurological grading system for cSDH (vide Table 7).

RESULTS

Of the 70 patients, included in our study, 55 underwent burr-hole and 15 underwent craniotomy. The mean age in the two groups, burr-hole and craniotomy group were 62.7 and 64.3 respectively, with a p value of 0.92 between the two groups (vide Table 1, 6). 41 patients in the burr-hole group were male as compared to 10 patients in the craniotomy group (vide Table 2). While 12 patients in the burr-hole group had bilateral cSDH, only one patient in the craniotomy group had bilateral cSDH.

The patient with bilateral cSDH in the craniotomy group underwent craniotomy in one side and burr-hole in the other side, at a later date. Majority of patients in burr-hole group had a Markwalder Grade Scale (MGS) of "1" at presentation while majority of patients in the other group had a MGS of 2. Despite this, the mean age in the first group was higher (1.9) than the second group (1.7), due to the fact that quite a few patients in the burr-hole group had a MGS of 4 at presentation, while no patient in the craniotomy group had a MGS of 4 at presentation. Similarly, the mean MGS at discharge was higher in the burr-hole group (0.9) as compared to the craniotomy group (0.2). However, the p value in the two groups was not significant statistically (vide Table 3, 5, 6). The operative time was significantly higher in the craniotomy group than in the burr-hole group (p value <0.0001) (vide Fig 1, Table 5,6). Since burr-hole craniotomy often resulted in incomplete evacuation of cSDH, and re-operations were frequently required, thereby increasing the patient's stay in hospital. The mean hospital stay in this group was found to be significantly higher than that in the craniotomy group (vide Table 5). Re-operation was frequently required in patients undergoing burr-hole. 6 out of 55 patients required to be operated again, while none in the craniotomy group required re-operation. The reason for re-operation in the burr-hole group was residual collection of cSDH. All such patients underwent a repeat burr hole except one who was transferred to the craniotomy arm. The patients undergoing re-operation had a significantly longer hospital stay than those who didn't need a revision surgery (vide Table 6). Only one patient in the craniotomy group developed pneumonia.

Table 1. Age distribution in burr-hole and craniotomy group

Age (years)	Burr-hole (n=55)	Craniotomy (n=15)
21-30	2	0
31-40	4	0
41-50	4	0
51-60	14	5
61-70	16	9
>70	15	1

Table 2. Sex distribution in burr-hole and craniotomy group

Sex	Burr-hole (n=55)	Craniotomy (n=15)
Male	41	10
Female	14	5

Table 3. MGS score distribution (on admission and discharge) in two groups

MGS Score	Burr-hole		Craniotomy	
	On admission	At discharge	On admission	At discharge
0	0	29	0	11
1	23	14	6	4
2	18	3	8	0
3	9	4	1	0
4	5	5	0	0

Table 4. Table showing post-operative complications in the two patient groups

Complication	Burr-hole	Craniotomy
Residual cSDH	6	0
Acute SDH	3	0
Wound infection	3	0
Pressure Sores	2	0
Systemic Complication	1	1

Table 5. Illustration of various parameters studied in the 2 patient groups with their mean values

Parameter	Burr-hole (n=55)	Craniotomy (n=15)
Male/Female	41/14	10/5
Age	62.7±29.8	64.3±12.2
Unilateral/Bilateral	43/12	14/1
MGS on admission	1.9±1.9	1.7±1.2
Duration of operation(minutes)	56.2±32.8	90.3±52.4
Hospital stay (days)	19.8±10.5	15.2±6.4
MGS at discharge	0.9±2.6	0.2±0.9
Complication rate		
- Residual cSDH	0.11	0.00
- Acute SDH	0.05	0.00
- Wound infection	0.05	0.00
- Pressure sores	0.04	0.00
- Systemic complications	0.02	0.67
Re-operation rate	0.11	0
Mortality	0.04	0.07

Table 6. Statistical analysis of various parameters in this study

Parameter	P value	Interpretation
Age	0.92	NS
Sex	0.54	NS
Laterality	0.18	NS
Duration of operation	<0.0001	Significant
Hospital stay	0.000	Significant
Complication	0.225	NS
Re-operation	0.18	NS
Mortality	0.67	NS

[NS = Not significant]

Table 7. Mark walder’s Neurological Grading System

Grade 0	No neurologic deficits
Grade 1	Mild symptoms (i.e. headache, absent or mild neurologic deficits like reflex asymmetry)
Grade 2	Drowsiness or disoriented with variable neurologic deficit (i.e. hemiparesis)
Grade 3	Stupor, severe focal neurologic deficit (i.e. hemiplegia)
Grade 4	Coma, posturing, or absence of motor response to noxious stimulation

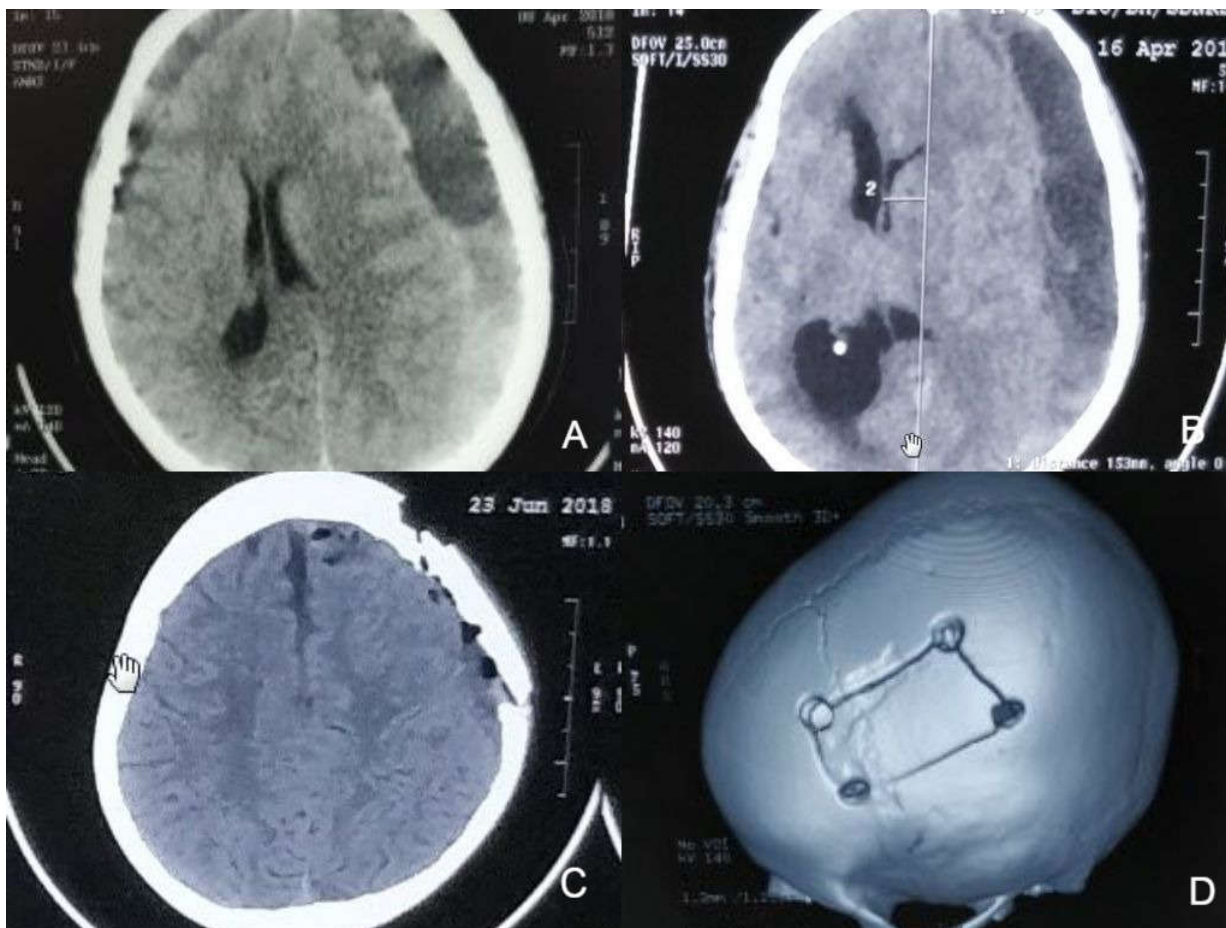

Fig 1. [A] Bilateral cSDH with intrahaematomal membranes on the left side. [B] Left Fronto-parietal cSDH with intrahaematomal membranes. [C] Post-operative CT scan following a small craniotomy for cSDH. [D] 3D reconstructed CT scan image of the craniotomy flap of the same individual in Fig 1.

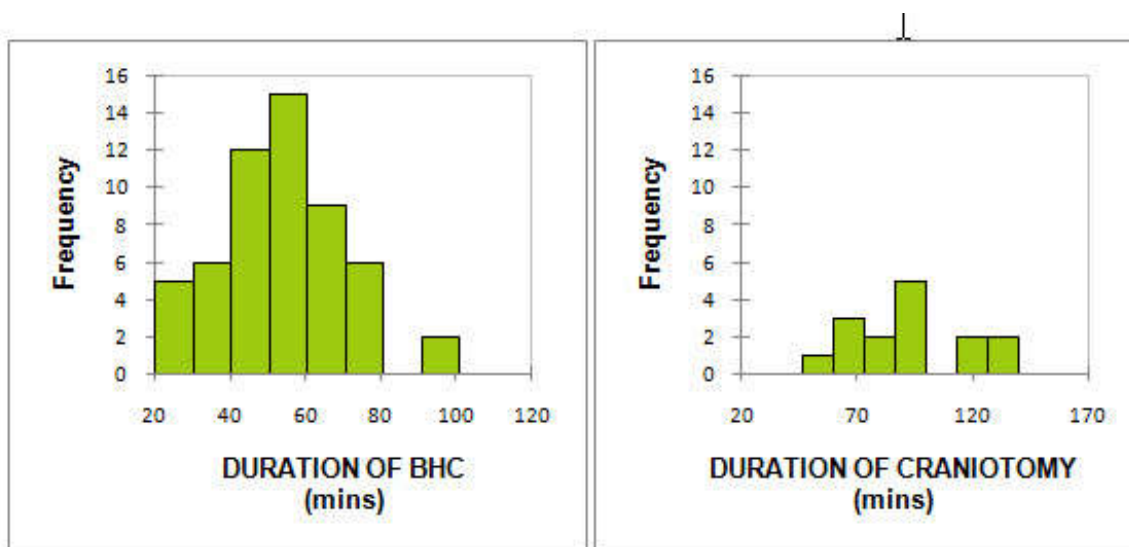


Fig. 2. Histogram illustrating duration of surgery in the two patient groups

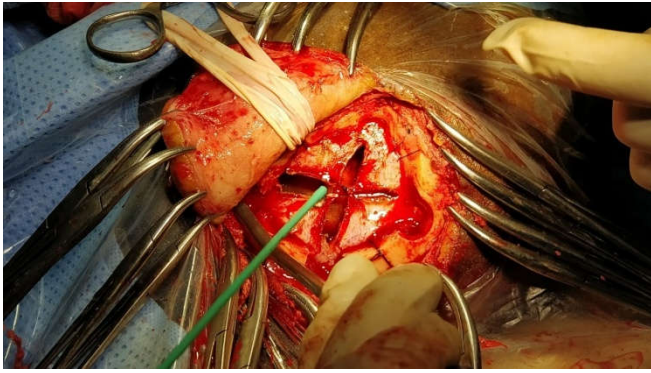


Fig. 3. Peri-operative image showing technique of dural closure following small craniotomy

No other local or systemic complication was seen in any other patient in this group. 11 patients developed complications in the burr-hole group, of which 3 had wound infection, 3 developed new onset acute SDH, 6 patients had residual collection of cSDH, 1 patient developed pneumonia and 2 had developed pressure sores. However, no statistically significant difference was noted between the two groups (vide Table 4,5,6). There was no significant difference in mortality in the two groups of patients (vide Table 6). 2 patients died in the burr-hole group, one due to pneumonia and the other due to sepsis following pressure sore. There was one death in the craniotomy group due to pneumonia.

DISCUSSION

Chronic subdural haematoma has been documented as one of the most common conditions encountered by a neurosurgeon (Lee, 2009). Although a variety of surgical treatment modalities has been availed for treating cSDH, there has been quite controversy in selecting the particular type of treatment for this condition. The evolution of surgical management options for cSDH has been very well documented in literature (Markwalder, 1981). These lesions were initially treated by craniotomy or craniectomy, in the pre-CT era, often with membranectomy (Markwalder, 1981). Although membranectomy had been dismissed as an essential component for treatment of cSDH (Markwalder, 1981), a recent meta-analysis in 2017 suggested that craniotomy with membranectomy yields a lower likelihood of cSDH recurrence and secondary interventions (Sahyouni, 2017). In the initial days of CT scan era, a number of articles were published which reported successful decompression of cSDH by using twist drill craniostomy (TDC) or burr-hole craniostomy (BHC) with significantly lower mortality and morbidity than previous techniques (Camel, 1986; Markwalder, 1985). Weigel *et al.* (Weigel, 2003), published the first evidence based review on the topic, demonstrating 1) higher morbidity with craniotomy compared with bore TDC and BHC, 2) non-statistically significant higher mortality rate with craniotomy, 3) similar cure rates between craniotomy and BHC, and 4) higher recurrence rates with TDC, suggesting craniotomy only be used as the last resort. In Markwalder's review on cSDH in 1981 (Markwalder, 1981), he proposed craniotomy only for the following conditions : 1)subdural reaccumulation, 2)failure of the brain to re-expand, and 3) removal of solid clot . Many other surgical techniques have been reported such as reservoir shunting for continuous irrigation and drainage (Aydin, 2004), percutaneous needle trephination and open system drainage with repeated saline rinsing (Van Eck, 2002), replacement of

the hematoma with oxygen via percutaneous subdural tapping without irrigation and drainage (Takeda, 2006), continuous subgaleal suction drainage (Gazzeri, 2011), etc. But these techniques were not popular worldwide nor are they practiced recently (Lee, 2009). Very few articles are available in literature analyzing the role of small craniotomy in management of cSDH and their comparison with BHC (Lee, 2009). In this article we report the preliminary results of our experience with BHC and small craniotomy in cSDH. Our study population comprises of 70 patients who were divided into two groups: Group I (n = 55), who underwent burr-hole, and Group II (n = 15), who underwent small craniotomy. Computed tomography (CT) scan was the primary imaging modality in our study. Rochi *et al.* (2007), suggested that MRI should always be performed in the following cases: 1) unusual appearance on CT scan, heterogeneous areas with high density margins, multiple compartments, septations and various bleeding foci, 2) cases of recurrent SDH, and 3) enhancement of some portion of the haematoma and its membranes on contrast enhanced CT scan. Furthermore, they insisted that craniotomy be primarily performed in the above mentioned cases. In addition to these conditions, Isobe and colleagues (Isobe, 2008) recommended craniotomy primarily for organized or calcified cSDH. They reviewed six patients diagnosed with an organized CSDH, five of whom had a history of burr-hole surgery. These patients collectively underwent four small craniotomies and two enlarged craniotomies. The authors emphasized that it was important to remove the organized CSDH and the outer membrane in proportion to the hematoma expansion. Imaizumi *et al.* (2001), reported five cases with organized cSDH and proposed that large craniotomy is the best treatment modality for these cases associated with progressive symptoms. In our study, four cases had organized cSDH for which craniotomy was done, with excellent post-operative results.

Tanikawa *et al.* (2001), based on T2-weighted MR sequence obtained from gradient echo sequence, classified intrahaematoma membranes into two groups, namely type B, which included subdural haematoma which had no intrahaematoma membranes or had monolayer multilobuli and, type C, in which haematoma was divided into multiple layers by intrahaematoma membranes. While burr-hole was offered to all patients of type B membranes, craniotomy was done in majority of patients with type C membranes (55.2%). In our study craniotomy was done in 15 patients (21.43%). The primary reason for selection for craniotomy in our cases was intrahaematoma membranes and organized cSDH except one, which was operated for residual haematoma following a burr-hole craniostomy. The mean age of the patients who underwent burr hole and craniotomy in our study was 62.7 yrs and 64.3 yrs respectively. The findings were at par with those of Kim *et al.* (2011), and Tanikawa *et al.* (2001). Of the 55 patients who underwent burr-hole craniostomy, 43 were male and 12 were female, whereas the craniotomy group had 10 male and 5 female patients. Lee and colleagues reported Male : Female ratio of 16 : 9 in the burr hole group and 24 : 6 in the craniotomy group (Lee, 2009). Lee and colleagues (Lee, 2009), in their study found that, at presentation, the mean Markwalder's score in the burr hole craniostomy group and craniotomy group were 1.44 and 1.27 respectively, whereas, Kim *et al.* (2011), reported a mean of 1.48 and 2.37 in the respective groups. In our study the mean Markwalder score at presentation in the burr hole craniostomy group and craniotomy group were 1.9 and 1.7 respectively, the

difference not being statistically significant. It is quite obvious that making a single burr-hole will require less time than performing a craniotomy followed by irrigation. Since there is a chance of epidural haematoma following craniotomy, proper dural hitch sutures, careful handling of subdural membranes, tight dural closure followed by autologous bone flap fixation is needed. All these procedures mandate increase in operating time in case of a craniotomy (Lee, 2009). Lee *et al.*, found statistically significant difference in operating time between burr hole craniostomy and craniotomy group (Lee, 2009). Regan and colleagues also reported similar findings in their study (Regan, 2015). In our study the mean operating time in the two sets of patients (BHC & craniotomy) were 56.2 minutes and 90.3 minutes respectively, which were significantly different statistically.

In contrary to the other studies, patients in the craniotomy series in our study did not undergo a watertight dural closure. The tips of the dural flaps were apposed and the cut margins were coagulated before replacing the bone flap. Although the criteria for selection of patients for craniotomy for cSDH evacuation have been discussed in many articles, there is no proper standardization regarding the size of craniotomy. While many authors considered a craniotomy of 3-4 cm to be small (Lee, 2009; Kim, 2011), others specified a 4-5 cm craniotomy as a small one (Tanikawa, 2001). There are also no proper guidelines proposed for selection of patients for either a small or large craniotomy. Kim *et al.* (2011), have mentioned in their article that the choice of a small or large craniotomy was dependant on the operating surgeon's judgment, factors influencing this judgment being CT/MRI findings, age and neurological status of the patients. However, no significant difference was found in the two groups, considering the criteria for which craniotomy was planned. In our study no comparison has been done between cases with small and large craniotomy.

One of the limitations in many studies is that it was poorly defined as to whether membranectomy was of the outer subdural membrane or inner subdural membrane (Sahyouni, 2017). The outer membrane is attached to the dura and vascular in nature whereas the inner layer is thin and avascular and adherent to the underlying arachnoid. Stripping the outer layer has been frowned upon in recent literature because of tendency to bleed from the margins of the exposed dura. The inner layer may be microdissected off from the underlying arachnoid thereby releasing the underlying accumulated blood breakdown products and allowing the brain to re-expand. However, arachnoid tear may occur causing CSF to leak in the subdural space (Hohenstein, 2005; Shim, 2007). A recent meta-analysis on role of membranectomy in cSDH reveals lower likelihood of cSDH recurrence and secondary interventions with comparable mortality and morbidity rates of craniotomy with membranectomy to burr hole craniostomy or craniotomy without membranectomy (Sahyouni, 2017). In our study outer membranectomy was done in 12 cases and total membranectomy was done in 3 cases in the craniotomy group. There was no recurrence of cSDH in the craniotomy group. There was no CSF leak in the patients who underwent total membranectomy. Lee *et al.* (2009), reported 12.6% overall complication rate following evacuation of cSDH, of which 22.8% occurred following burr hole and 6.7% occurred following craniotomy. Complications included wound infection, cerebral hemorrhage, venous infarction, subdural hygroma, tension pneumocephalus, decreased mentality, pneumonia, seizures and hemiparesis.

The p value of post-operative complication rate was 0.037 which was not statistically significant. Hamilton *et al.* (1993), and Kim *et al.* (2011), also did not find any statistically significant difference in post-operative complication rate between the burr hole and craniotomy group. Another meta-analysis by Ducruet and colleagues in 2012 reported a complication rate of 9.3% following burr hole and 3.9% following craniotomy (Ducruet, 2012). In our study, 11 patients in the burr-hole group developed complications, of which 3 had wound infection, 3 developed new onset acute SDH, 6 patients had residual collection of cSDH, 1 patient developed pneumonia and 2 had developed pressure sores. Only 1 patient in the craniotomy group developed pneumonia. Kim *et al.* (2011), reported operative mortality of 3.5% in the craniotomy group and 8.1% in the burr hole group with no significant difference (p value=0.671). In a study by Tanikawa and colleagues, only one death was reported following burr hole craniostomy unrelated to cerebral decompression (Tanikawa, 2001). However, Ducruet *et al.* (2012), reported a mortality rate of 12.2% following craniotomy and 3.7% following burr hole craniostomy in their meta-analysis. In our study mortality in the BHC and craniotomy group were 3.6% and 6.7% which were not significantly different.

There has been mixed review regarding post operative hospital stay following burr hole and craniotomy. While some studies suggest a longer hospital stay in the burr-hole group than craniotomy, others report otherwise. Tanikawa *et al.*, noted a mean hospital stay of 22.6 days in the burr hole group and 16.8 days in the craniotomy group post-operatively, which was not significantly different statistically (Tanikawa, 2001). A study by Lee *et al.*, revealed a mean hospital stay of 20.6 days and 37.9 days in the craniotomy and burr hole group respectively with a p value of 0.01 (Lee, 2009). However, in contrary, Regan and colleagues recorded a shorter hospital stay in the burr hole group than the craniotomy group (Regan, 2015). The results of our study were similar to the initial studies, the burr-hole group patients having a significantly more hospital stay than the craniotomy group.

Considering the revision rate of surgery, Lee *et al.*, reported a revision rate of 3.3% in the small craniotomy group which was significantly lower (p value = 0.043) than that in the burr hole group (17.5%) (Lee, 2009). Tanikawa and colleagues in their study noted a revision rate of 30.8% in the burr hole group for patients with type C membranes, whereas no re-operation was required for any patient in the craniotomy group (Tanikawa, 2001). However, Kim *et al.*, reported a significantly lower revision rate in the burr-hole group (8.88%) than the small craniotomy group (50%) (Kim, 2011). The reasons for re-operation in their series were recollection of subdural fluid and a small rebleed with collection of cSDH. On the other hand, the causes for revision surgery in the burr-hole group were residual subdural fluid in the haematoma cavity and failure of the brain to re-expand due to intrahaematoma septations. Acute rebleeding was the least common cause for re-operation in this group (Kim, 2011). Their opinion on this matter was that the limited surgical view and partial membranectomy associated with small craniotomy caused difficulty in coagulating the neovascularized vessels and removal of the membranes beyond the craniotomy margin, which resulted in rebleeding and recollection of the subdural fluid. They suggested a large craniotomy as a better alternative in this situation for superior and safer dealing of the haematoma, its membranes and occasional troublesome bleeding.

However, no significant age difference was noted in the two groups in this series (Kim, 2011). We noted a revision rate of 10.9% in the burr-hole group. No patient in the craniotomy group had to be re-operated.

Conclusion

There has been very limited articles in literature regarding the role of small craniotomy in management of chronic subdural haematoma with mixed response. A randomized control study comparing small craniotomy with other surgical procedures for cSDH is yet to be performed. We observed that small craniotomy is a preferable option for management of cSDH with intrahaematoma membranes and septations. However, our study populations being small, further studies with larger population, preferably a randomized control trial are suggested for confirmation of our findings.

Conflict of Interest: There were no conflicts of interest in this study.

Funding Statement: Nil

REFERENCES

- Aydin, M. 2004. The use of reservoir shunt in chronic subdural hematoma. *Neurology India*. 52(1).
- Camel, M. and R.L. Grubb Jr, 1986. Treatment of chronic subdural hematoma by twist-drill craniostomy with continuous catheter drainage. *Journal of neurosurgery*. 65(2): p. 183-187.
- Ducruet, A.F., et al., 2012. The surgical management of chronic subdural hematoma. *Neurosurgical review*. 35(2): p. 155-169.
- Fogelholm, R., O. Heiskanen, and O. Waltimo, 1975. Chronic subdural hematoma in adults: influence of patient's age on symptoms, signs, and thickness of hematoma. *Journal of neurosurgery*, 42(1): p. 43-46.
- Gazzeri, R., et al., 2007. Continuous subgaleal suction drainage for the treatment of chronic subdural haematoma. *Acta neurochirurgica*. 149(5): p. 487-493.
- Hamilton, M.G., J.B. Frizzell, and B.I. Tranmer, 1993. Chronic subdural hematoma: the role for craniotomy reevaluated. *Neurosurgery*. 33(1): p. 67-72.
- Hohenstein, A., et al., 2005. Increased mRNA expression of VEGF within the hematoma and imbalance of angiopoietin-1 and-2 mRNA within the neomembranes of chronic subdural hematoma. *Journal of neurotrauma*, 2005. 22(5): p. 518-528.
- Imaizumi, S., et al., 2001. Organized chronic subdural hematoma requiring craniotomy. *Neurologia medico-chirurgica*. 41(1): p. 19-24.
- Isobe, N., et al., 2008. Six cases of organized chronic subdural hematoma. *No shinkei geka. Neurological surgery*. 36(12): p. 1115-1120.
- Kim, J.-H., et al., 2011. Chronic subdural hematoma treated by small or large craniotomy with membranectomy as the initial treatment. *Journal of Korean Neurosurgical Society*, 2011. 50(2): p. 103.
- Lee, J.K., et al. 2009. Chronic subdural hematomas: a comparative study of three types of operative procedures. *Journal of Korean Neurosurgical Society*, 46(3): p. 210.
- Markwalder, T.M. and R.W. Seiler, 1985. Chronic subdural hematomas: to drain or not to drain? *Neurosurgery*, 16(2): p. 185-188.
- Markwalder, T.-M., Chronic subdural hematomas: a review. *Journal of neurosurgery*, 1981. 54(5): p. 637-645.
- Regan, J.M., et al., Burr hole washout versus craniotomy for chronic subdural hematoma: patient outcome and cost analysis. *PLoS One*, 2015. 10(1): p. e0115085.
- Rocchi, G., et al., 2007. Membranectomy in organized chronic subdural hematomas: indications and technical notes. *Surgical neurology*. 67(4): p. 374-380.
- Sahyouni, R., et al. 2017. Membranectomy in chronic subdural hematoma: meta-analysis. *World neurosurgery*, 104: p. 418-429.
- Shim, Y.S., et al., 2007. What are the causative factors for a slow, progressive enlargement of a chronic subdural hematoma? *Yonsei medical journal*, 48(2): p. 210-217.
- Takeda, N., et al., 2006. A new simple therapeutic method for chronic subdural hematoma without irrigation and drainage. *Acta neurochirurgica*. 148(5): p. 541-546.
- Tanikawa, M., et al., 2001. Surgical treatment of chronic subdural hematoma based on intrahematoma membrane structure on MRI. *Acta neurochirurgica*, 143(6): p. 613-619.
- Van Eck, A., C. De Langen, and W. Börm, 2002. Treatment of chronic subdural haematoma with percutaneous needle trephination and open system drainage with repeated saline rinsing. *Journal of clinical neuroscience*. 9(5): p. 573-576.
- Weigel, R., P. Schmiedek, and J. Krauss, 2003. Outcome of contemporary surgery for chronic subdural haematoma: evidence based review. *Journal of Neurology, Neurosurgery & Psychiatry*. 74(7): p. 937-943.
