



ISSN: 0975-833X

Available online at <http://www.journalcra.com>

International Journal of Current Research
Vol. 10, Issue, 10, pp.74610-74613, October, 2018

DOI: <https://doi.org/10.24941/ijcr.32426.10.2018>

INTERNATIONAL JOURNAL
OF CURRENT RESEARCH

CASE STUDY

THE LPAC SYNDROME AN UNKNOWN ENTITY BUT EXISTS: STUDY OF THREE CASES

^{1,*}Wissem Triki, ²Sonia Ben Hamida, ¹Oussema Baraket, ³Imen Ganzoui, ¹Abdelmajid Baccar, ¹Sarra Belakhoua and ¹Sami Bouchoucha

¹CHU Habib Bougatfa Bizerte, service de Chirurgie Générale, Université Tunis Elmanar, Faculté de Médecine de Tunis, Tunisie

²CHU Habib Bougatfa Bizerte, Service de Gastroenterologie, Université Tunis Elmanar, Faculté de Médecine de Tunis, Tunisie

³CHU Habib Bougatfa Bizerte, Service de Radiologie, Université Tunis Elmanar, Faculté de Médecine de Tunis, Tunisie

ARTICLE INFO

Article History:

Received 06th July, 2018
Received in revised form
27th August, 2018
Accepted 29th September, 2018
Published online 31st October, 2018

ABSTRACT

Low Phospholipid Associated Cholelithiasis syndrome (LPAC) is a disease of the young woman. The diagnosis is suspected by the presence of certain criteria and confirmed by genetic testing. We report the case of three brothers who have presented with recurrent biliary pain and an abnormal liver function. Their parents were first degree cousins who had been surgically treated for a biliary disease. The diagnosis of LPAC was backed by clinical and radiological arguments. The three brothers were treated by ursodesoxycholic acid with regression of clinical signs and normalization of liver function.

Key words:

MDR3, ABCB4,
ursodeoxycholic acid,
phospholipids, cholelithiasis, Biliary
Cirrhosis.

Copyright © 2018, Wissem Triki et al. This is an open access article distributed under the Creative Commons Attribution License, which permits unrestricted use, distribution, and reproduction in any medium, provided the original work is properly cited.

Citation: Wissem Triki, Sonia Ben Hamida, Oussema Baraket, Imen Ganzoui, Abdelmajid Baccar, Sarra Belakhoua and Sami Bouchoucha. 2018. "The LPAC syndrome an unknown entity but exists: study of three cases", *International Journal of Current Research*, 10, (10), 74610-74613.

INTRODUCTION

LPAC (Low Phospholipid Associated Cholelithiasis), is a particular form of cholelithiasis that was first described in 2001 (Rosmorduc *et al.*, 2001). It is caused by an ABCB4 gene mutation which codes for the phospholipid transport protein MDR3. The diagnosis is based on multiple criteria but can only be confirmed by genetic testing. This disease is medically treated by ursodésoxycholic acid (UDCA) (Nicolaou *et al.*, 2012). Surgical treatment is sometimes needed, it ranges from a simple cholecystectomy to hepatic transplantation. We report the case of three brothers who have a family history of gallstones. We have suspected LPAC syndrome by referring to the diagnostic criteria.

Observation 1: A 29 year-old male patient who has been complaining for six years for paroxystic right upper quadrant pain with sub-jaundice and dark urine but no fever.

***Corresponding author:** Wissem Triki,

CHU Habib Bougatfa Bizerte, service de Chirurgie Générale, Université Tunis Elmanar, Faculté de Médecine de Tunis, Tunisie.

Lab tests showed moderately elevated liver enzymes at 2 times the normal value (ALT 82 UI/l, AST 73 UI/l), no cholestasis. HVB and HVC serologic tests were negative. Three years later, the pain became more intense with abnormal laboratory results: WBC 10400 /mm³, Hb 13g/dl, platelets à 241000/mm³, CRP 4mg/l, AST 820 UI/l (20 N) and ALT 611 UI/l (15N) GGT 450 UI/l (9N) ALP 150 UI/l1.5, PT 60%. Abdominal ultrasound showed a discrete dilation of the common bile duct with no detectable obstacle and a gallstone-free gallbladder. The biliary MRI concluded to a dilation of the intrahepatic bile ducts and the common bile duct (9mm) by two small gallstones blocking the lower common bile duct (Fig.1). The patient underwent a cholecystectomy followed by an ERCP with extraction of multiple stones (Fig.1). Three months later, the recurrence of symptoms was explored by an abdominal ultrasound showing a gallstone of the lower common bile duct. The patient was prescribed UDCA with regression of pain and normalization of hepatic function.

Observation 2: A 25 year-old male patient who underwent an emergency cholecystectomy five years prior for acute cholecystitis caused by an 18mm gallstone clogging the

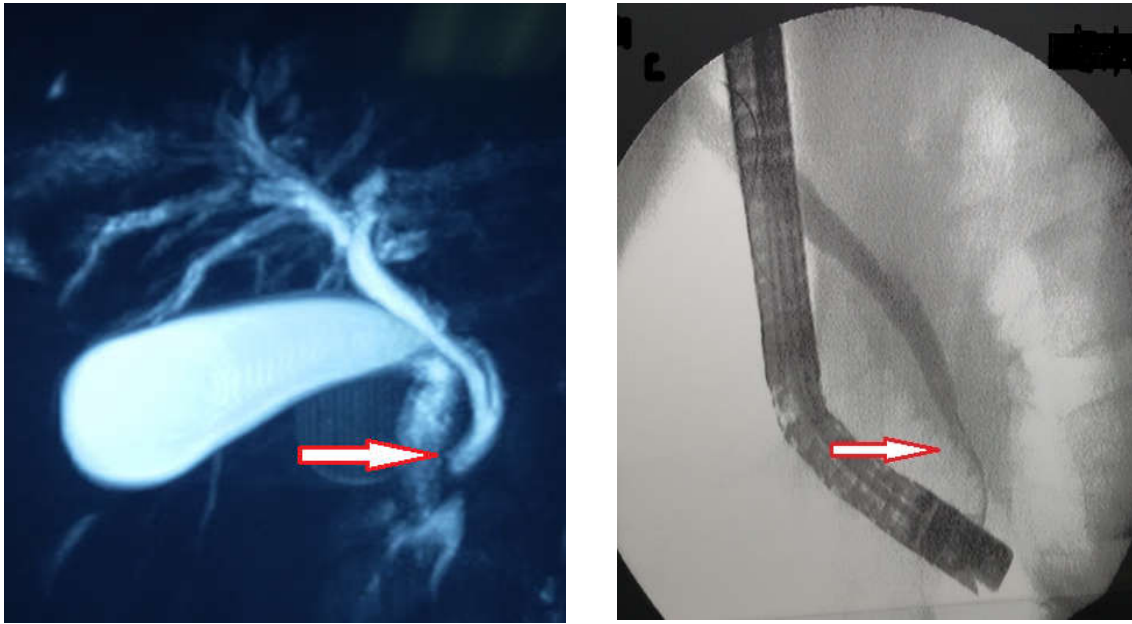


Fig.1. Moderate dilatation of the intrahepatic bile ducte with stone in choledoc

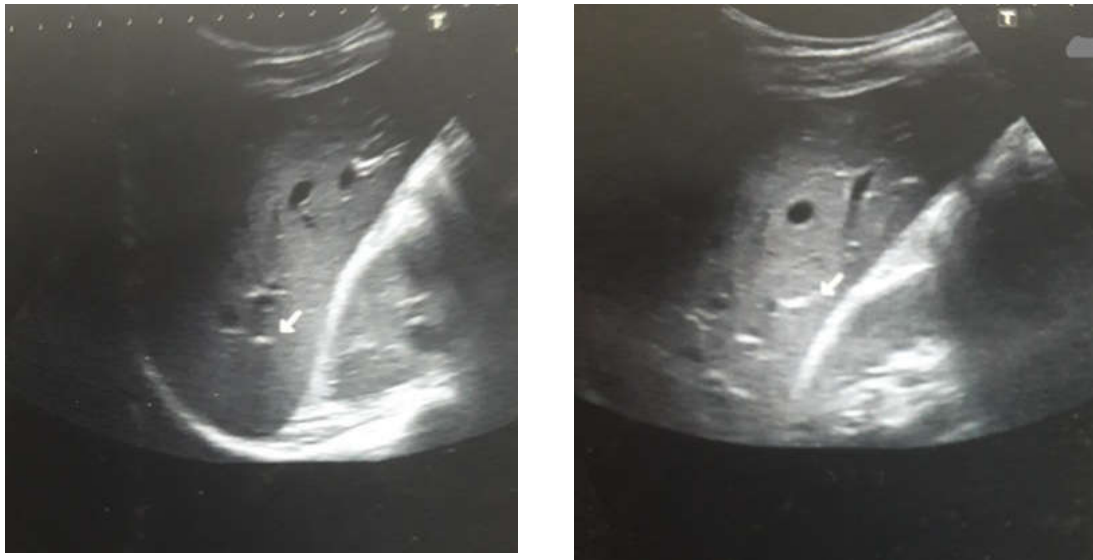


Fig.2. Intrahepatic lithiasis with upstream dilatation

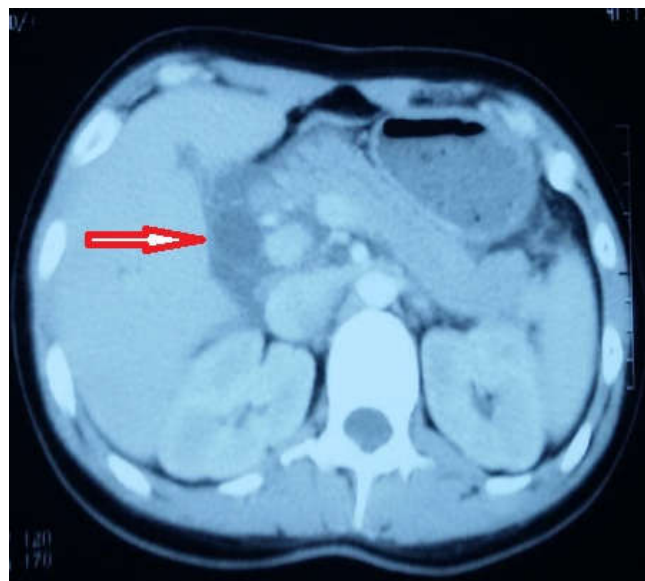


Fig. 3. Bile duct dilatation

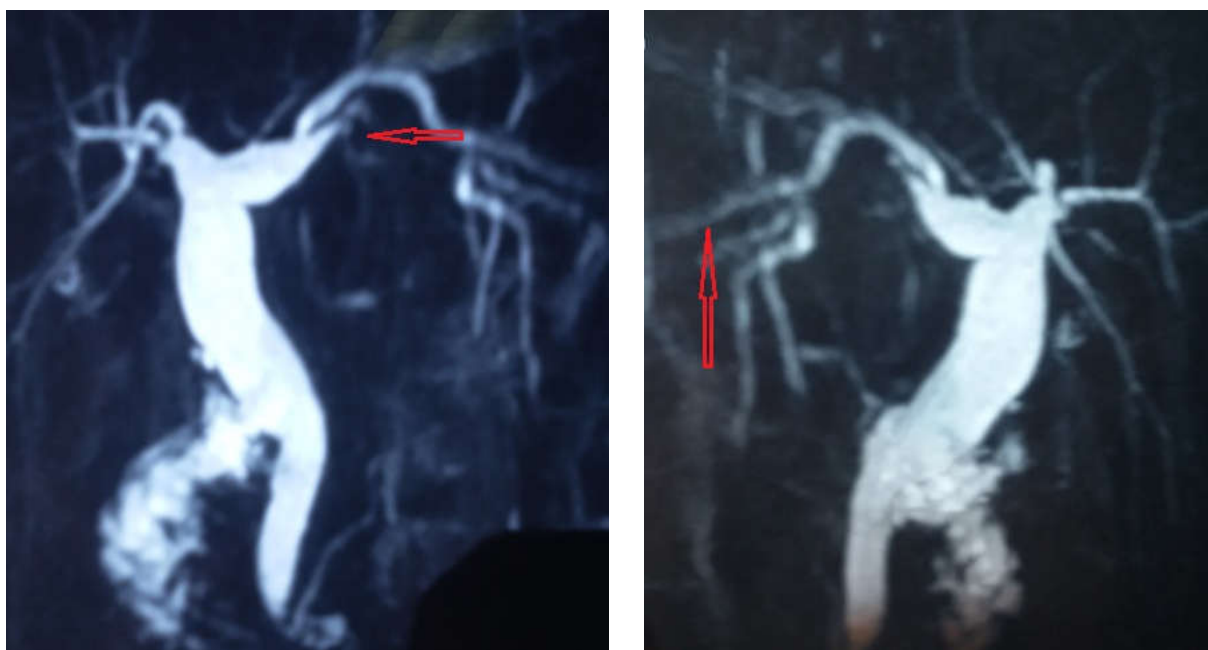


Fig.4. dilation of the common bile duct and of the 5th segmental duct with lacunary images in segment V associated to a bad visualization of segment III due to intrahepatic biliary microlithiasis

gallbladder's infundibulum. He had been complaining from right upper quadrant pain described as intermittent hepatic colic for 3 years associated to dyspepsia. Laboratory results: ALT at 66 UI/l, AST at 55 UI/l, PT at 91 %, GGT at 100 UI/l. An abdominal ultrasound was performed showing a hyperechoic image with posterior acoustic shadowing corresponding to a biliary microlithiasis (Fig.2). Knowing that his brother had LPAC, we prescribed UDCA. The patient had a favorable clinical and biological followup.

Observation 3: A 22 year-old female patient who had undergone a cholecystectomy at the age of 13 years old, presented with acute abdominal pain. On examination, there was epigastric impaction. The rest of the abdomen was soft. Laboratory results showed WBC at 1200/mm, lipase 1500 U/l, ALT 188 U/l, AST 92 U/l, PT 82%. The diagnosis of acute pancreatitis was made as lipase levels were very high and the CT Scan showed stage C pancreatitis (Fig.3). The abdominal ultrasound was normal and the biliary MRI showed a segmental dilation of the intrahepatic bile ducts and lacunary images in segment V. Segment III was not visualized well due to the presence of intrahepatic biliary microlithiasis (Fig.4). The followup was marked by the persistence of right upper quadrant pain with moderately elevated liver enzymes (ALT at 80 IU/l and AST at 75 IU/l) and anicteric cholestasis (GGT at 150 IU/l, ALP at 50 IU/l (Normal)). Hepatitis viruses A, B and C serum testing was negative. Two abdominal ultrasounds were performed and showed no abnormalities. The biliary MRI showed a dilatation of the common bile duct and of the 5th segmental duct. There were lacunary images in segment V associated to a bad visualization of segment III due to intrahepatic biliary microlithiasis.

DISCUSSION

LPAC syndrome is a disease characterized by recurrent symptoms and relapsing gallstones in young adults. It was described in 2001 by Rosmorduc and al (Rosmorduc *et al.*, 2001). It was later defined as a clinical syndrome involving at least two of the following criteria (Rosmorduc, 2007):

Onset of symptoms before 40 years of age, recurrence of biliary symptoms after a cholecystectomy, hyperechoic intrahepatic lesions on ultrasound, a personal history of gravid cholestasis, a first degree family history of symptomatic gallstones before the age of 30 years. Certain authors add an impressive efficiency of UDCA therapy, i.e a regression of symptoms within 6 months of therapy. Although the prevalence of LPAC syndrome is still unknown, it is estimated at about 5% of symptomatic gallstones (Erlinger, 2012). For our patients, the diagnosis was made by referring to the aforementioned criteria, no genetic testing was done due to high costs. The median age of symptom onset varies between 26 and 32 years old according to different studies (Poupon *et al.*, 2013). The first symptoms of LPAC can sometimes occur after the age of 40 years, but the onset of symptoms after the age of 50 years is exceptional. Otherwise, LPAC is not symptomatic before the end of adolescence; it is not therefore a common cause of pediatric gallstones (Jirsa *et al.*, 2014). Women are more likely to get the disease because of the inhibition of phospholipid secretion in bile by estrogen (Poupon *et al.*, 2013). There are no specific clinical and laboratory features for this syndrome. LPAC is associated to ABCB4 gene mutation which codes for MDR3 protein. However, these mutations are observed in just about 60% of the cases (Rosmorduc *et al.*, 2003). Treatment of this syndrome relies on a prolonged AUC therapy at the dose of 10 mg/kg/day. This treatment increases the expression of MDR3 protein and facilitates the secretion of phospholipids in the bile (Erlinger, 2012). Therefore, we obtain a better solubility of cholesterol and a dissolution of cholesterol crystals and gallstones. It also allows a regression of symptoms since the first days of therapy. All of our patients were put on medical treatment and had a favorable outcome. Surgical treatment is indicated in case of: cholecystitis -which remains a rare complication- (Condat *et al.*, 2013), intrahepatic cholelithiasis treated by segmental hepatectomy, secondary biliary cirrhosis necessitating a hepatic transplantation.

Conclusion

LPAC is a rare entity distinguished by recurrent symptoms due to relapsing gallstones.

The diagnosis is made by reuniting clinical and radiological arguments. It is confirmed by genetic testing. Familial screening is legitimate in children whose parents are first-degree cousins in order to prevent possible complications, especially fibrosis, by a simple medical treatment.

RÉFÉRENCES

- Condat B., Zanditenas D., Barbu V., Hauuy MP., Parfait B., El Naggar A., Collot V., Bonnet J., Ngo Y., Maftouh A., Dugué L., Balian C., Charlier A., Blazquez M., Rosmorduc O. 2013. Prevalence of lowphospholipid-associated cholelithiasis in young female patients. *Dig. Liver. Dis.*, 45(11):915-9.
- Erlinger S. 2012. Low phospholipid-associated cholestasis and cholelithiasis. *Clin. Res. Hepatol. Gastroenterol*, 36(suppl 1):S36-S40.
- Jirsa M., Bronsky J., Dvorakova L., Sperl J., Smajstrla V., Horak J., Nevoral J., Hrebíček M. 2014. ABCB4 mutations underlie hormonal cholestasis but not pediatric idiopathic gallstones. *World J. Gastroenterol.*, 20(19):5867-74.
- Nicolaou M., Andress EJ., Zolnerciks JK., Dixon PH., Williamson C., Linton K.J. 2012. Canalicular ABC transporters and liver disease. *J. Pathol.*, 226(2):300-315.
- Poupon R., Rosmorduc O., Boëlle, PY., Chrétien Y., Corpechot C., Chazouillères O., Housset C., Barbu V. 2013. Genotype-phenotype relationships in the lowphospholipid-associated cholelithiasis syndrome: a study of 156 consecutive patients. *Hepatology*, 58(3):1105-10.
- Rosmorduc O., Hermelin B., Boelle PY., Parc R., Taboury J., Poupon R. 2003. ABCB4 gene mutation associated cholelithiasis in adults. *Gastroenterology*, 125(2):452-9.
- Rosmorduc O., Hermelin B., Poupon R. 2001. MDR3 gene defect in adults with symptomatic intrahepatic and gallbladder cholesterol cholelithiasis. *Gastroenterology*, 120(6):1459-1467.
- Rosmorduc O., Poupon R. 2007. Low phospholipid associated cholelithiasis: association with mutation in the MDR3/ABCB4 gene. *Orphanet J. Rare. Dis.*, 2:29.
