



ISSN: 0975-833X

Available online at <http://www.journalcra.com>

International Journal of Current Research  
Vol. 11, Issue, 01, pp.603-606, January, 2019

DOI: <https://doi.org/10.24941/ijcr.33775.01.2019>

INTERNATIONAL JOURNAL  
OF CURRENT RESEARCH

## RESEARCH ARTICLE

### LOBULAR CAPILLARY HEMANGIOMA (PYOGENIC GRANULOMA) WITH SATELLITOSIS OF GINGIVA: A RARE CASE REPORT

<sup>1</sup>Dr. Chandulal D. Dhalkari, <sup>2\*</sup>Dr. Sayali C. Patil and <sup>3</sup>Dr. Maya S. Indurkar

<sup>1</sup>BDS, MDS, Professor and PG Guide, Government Dental College and Hospital, Aurangabad

<sup>2</sup>3<sup>rd</sup> PG PG Student, Government Dental College and Hospital, Aurangabad

<sup>3</sup>HOD and Professor, Government Dental College and Hospital, Aurangabad

#### ARTICLE INFO

##### Article History:

Received 18<sup>th</sup> October, 2018

Received in revised form

14<sup>th</sup> November, 2018

Accepted 29<sup>th</sup> December, 2018

Published online 31<sup>st</sup> January, 2019

##### Key Words:

Capillary Haemangioma,  
Excision, Pyogenic Granuloma.

Copyright © 2019, Chandulal D. Dhalkari et al. This is an open access article distributed under the Creative Commons Attribution License, which permits unrestricted use, distribution, and reproduction in any medium, provided the original work is properly cited.

Citation: Dr. Chandulal D. Dhalkari, Dr. Sayali C. Patil and Dr. Maya S. Indurkar. 2019. "Lobular capillary hemangioma (pyogenic granuloma) with satellitosis of gingiva: a rare case report.", *International Journal of Current Research*, 11, (01), 603-606.

#### ABSTRACT

Pyogenic granulomas and hemangiomas of oral cavity are well-known benign lesions. The gingival occurrence of capillary hemangioma is considered relatively rare. The purpose of this article is to report, the clinical diagnosis of such an uncommon occurrence can be quite challenging as they sometimes mimic benign as pyogenic granuloma & in reality, it could be a more serious lesion such as malignancies. Dentists should therefore be aware of these lesions when making diagnosis and attempts at excision of apparently innocent lesions may result in serious bleeding.

#### INTRODUCTION

Pyogenic granulomas of the oral cavity are known to involve the gingiva commonly. It is a misnomer as this condition is not associated with pus and does not represent a granuloma histologically (Shafer *et al.*, 1983). In fact on the basis of the histopathological picture; it is also called lobular capillary hemangioma (Patil *et al.*, 2006). Hemangiomas are benign tumors composed of blood vessels and are classified on the basis of their histological appearance as capillary, mixed cavernous, or a sclerosing variety that tends to undergo fibrosis (Acikgoz *et al.*, 2000). Although hemangioma is a common tumor of the head and neck region, they usually occur in lips, cheeks, and tongue (Mehrotra, 1965). Hemangiomas occur in skin of 4-10% of Caucasian new born with 3- to 5-fold greater incidence in females. Dark skinned infants have a lower incidence (Mulliken, 1990). No details about incidence in the Indian population available (Murthy, 2005). Thus, the differentiation between a capillary hemangioma and pyogenic granuloma is somewhat unclear at this time. Hemangiomas are characterized by the proliferation of blood vessels (Bharti, 2012). Microscopically, capillary hemangioma (CH) consists of numerous small capillaries lined by a single layer of endothelial cells supported in the connective tissue stroma of varying density (Dahiya, 2014).

Incidence of intraoral CHs varies from 0.5 to 1.0% of all intraoral neoplasms (Kumari *et al.*, 2015). A very few cases of intraoral CHs have been reported in literature. The present case is important because of its uncommon location on the gingiva, with extension onto the alveolar mucosa and occurrence in a middle-aged individual.

**Case report:** A 32-year-old female patient reported with chief complaint of tissue growth in relation to 31, 41, 42 and 43 since 20-days (Figure 1A). Intraoral soft tissue examination revealed a solitary, pedunculated, spherical-shaped, reddish purple swelling with distinct border and irregular surface & measuring about 1.4 × 1.5cm in dimension. Surrounding mucosa was normal. On palpation the swelling was non-tender, soft to firm in consistency, blanching on pressure. Intraoral periapical radiograph revealed no loss of bone in relation to the lesion. Patient recalled after 1-month (Figure 1B). Past dental history revealed, patient had undergone epulis excision of same region 1-month prior. Medical history revealed, bleeding gets control after longer period & hemogram revealed increased clotting time (aprox. 15-min). Taking all clinical findings into consideration, a provisional diagnosis of pyogenic granuloma was made but as differential diagnosis consisted of capillary hemangioma.

**Surgical Management:** For the case, oral prophylaxis and excisional biopsy of the lesion was performed under strict aseptic conditions.

\*Corresponding author: Dr. Sayali C. Patil,  
3rd PG PG Student, Government Dental College And Hospital,  
Aurangabad.

A 1 mm narrow margin of normal mucosa was removed with the lesion in order to ensure total removal of the lesion and to prevent recurrence (Figure 2,3). Thorough curettage was done and complete hemostasis achieved. Periodontal dressing was given. The patient recalled after 1 week & 6 month, showed satisfactory evenful healing (Figure 5).

**Histologic findings:** The histopathological section of the specimen showed parakeratinised stratified squamous epithelium of varying thickness and areas of ulceration. The fibrous connective tissue showed numerous endothelial lined blood vessels of varied size and few blood vessels, which were yet to be lumenized and abnormal clustering of cells around another. Numerous mixed inflammatory components secondary to ulceration were present (Figure 4A, 4B).

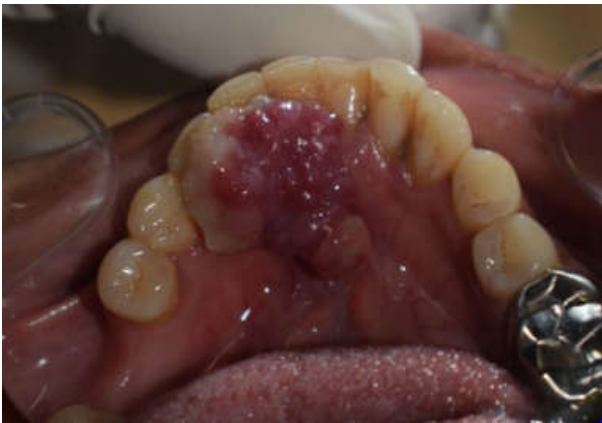

Fig 1 A. PRE-OP

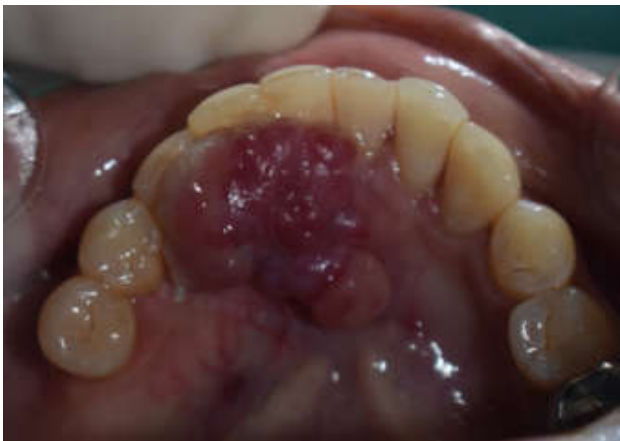

Fig 1B. Follow-UP, 1-Month After Scaling

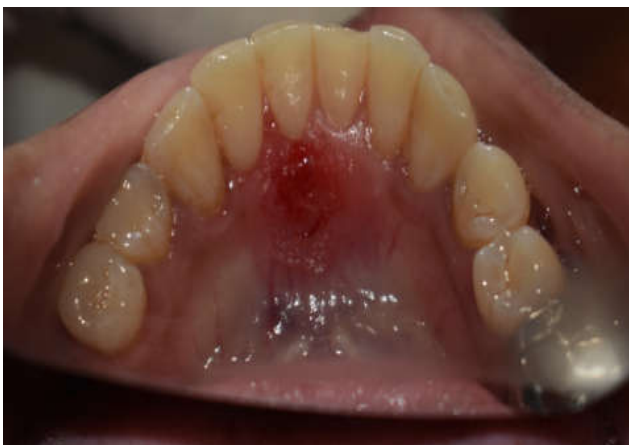

Fig 2. After Excision

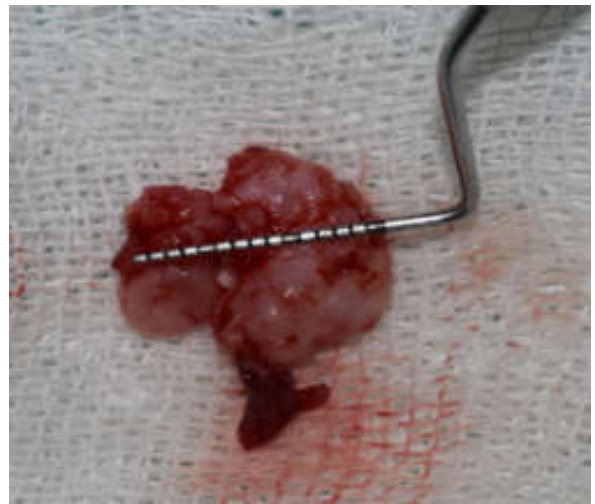


Fig. 3. Excised Tissue

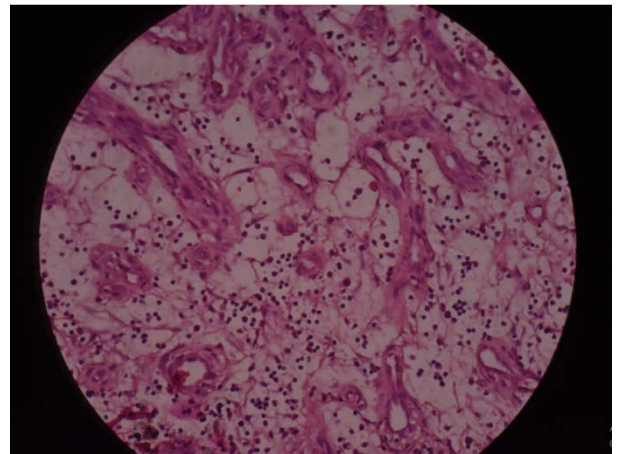
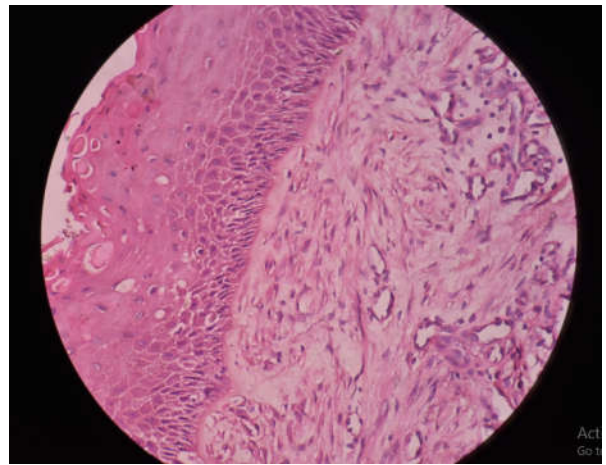


Fig 4 A,B. Histopathological picture

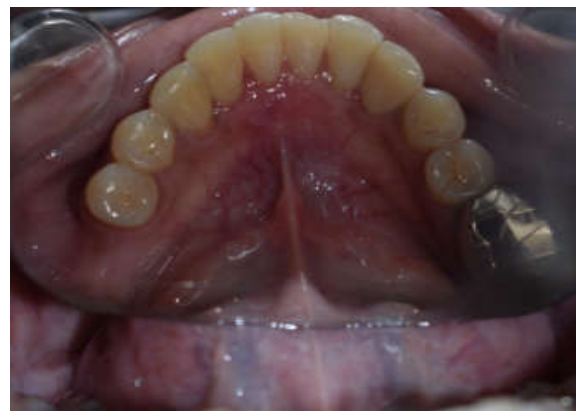

Fig 5. Follow-UP After 6-Month

The pathology report obtained from the hospital pathologist stated that "histopathological features were suggestive of lobular capillary hemangioma with satellitosis and inflammatory component, secondary to ulceration." The histopathological diagnosis was given as lobular capillary hemangioma with satellitosis by oral pathologist. Due to the dilemma, the specimen was again submitted to the general pathology department, which confirmed the original diagnosis of lobular capillary hemangioma with satellitosis.

## DISCUSSION

Hemangiomas are a common soft tissue tumor of the head and neck region that are often congenital or develop in the neonatal period (Silverman, 1991; Greene, 1990). In the case presented here, the first occurrence was reported at 32 years of age. Its occurrence in the gingival mucosa is rare. The differential diagnosis of hemangiomas includes pyogenic granuloma, chronic inflammatory gingival hyperplasia (epulis), epulis granulomatosa, and squamous cell carcinoma (Acikgoz, 2000). Histopathologically, the capillary hemangioma exhibits a progression from a densely cellular proliferation of endothelial cells in the early stages to a lobular mass of well-formed capillaries in the mature phase, often resembling the pyogenic granuloma without the inflammatory features. The present cases have clinical but not the histopathological features of a pyogenic granuloma. Therefore, biopsy of tissue specimens is often necessary for definitive diagnosis. Hemangiomas are characterized by three stages, namely, endothelial cell proliferation, rapid growth, and spontaneous involution (Kamala, 2014). They may be cutaneous, mucosal, intramuscular, and intraosseous (Bharti, 2012; Dilsiz, 2009). Exact etiology of hemangiomas is unknown (Bharti, 2012; Satish *et al.*, 2014).

Imbalance in angiogenesis plays an important role in the development of hemangiomas (Bharti, 2012; Kamala, 2014). Based on the microscopic appearance, they are classified into capillary, cavernous, mixed, and sclerosing variety (Shafer *et al.*, 1983; Patil K, Mahima, 2006; Bharti *et al.*, 2012; Dahiya R, Kathuria, 2014; Rachappa, 2010). In the present case, the lesion was capillary type of hemangioma. Both PG and CH occur at a young age, with high incidence in females (Patil *et al.*, 2006; Rachappa, 2010). These two lesions present a diagnostic dilemma to the clinician, and hence microscopic evaluation is mandatory to make a definitive diagnosis (Kumari *et al.*, 2015). Microscopically, PG is classified into two types, namely, lobular capillary hemangioma (LCH) and non-LCH (Dahiya, 2014; Kumari *et al.*, 2015; Dilsiz, 2009; Selvamuthukumar *et al.*, 2010). Microscopically, LCH type of PG consists of an attenuated endothelial lining surrounded by somewhat uniform proliferation of plump to spindle cells whereas CH consists of more prominent endothelial cells and an array of capillary-sized blood vessels with lobular architecture. In LCH type of PG, capillaries are frequently arranged perpendicular to the surface (Kumari *et al.*, 2015). Light microscopic differentiation between true hemangioma of infancy and PG may be difficult; however, the latter exhibits immunocytochemical and ultrastructural differences (Rachappa, 2010). Radiographs should be advised to rule out any bony destruction, which may be suggestive of either central variety of hemangioma or malignancy. The treatment of hemangiomas of the oral mucosa depends upon various factors such as the age of the patient, the size of the lesion, extent of the lesion, the site of involvement, and the clinical

features (Shafer, 1983; Kumari *et al.*, 2015; Dilsiz, 2009). The most common treatment modality of hemangioma is surgical excision of the lesion, with or without ligation of vessels and embolization (Kumari *et al.*, 2015). Surgical management should be done with caution because of the possibility of the bleeding intraoperatively and postoperatively. Recently developed treatment modalities include steroid therapy, electrosurgery, Nd:YAG laser, CO2 laser, cryosurgery, and sclerotherapy (Kumari *et al.*, 2015). Nowadays, sclerotherapy is used largely because of its ability and efficiency to preserve the surrounding tissue (Kamala *et al.*, 2014). Current management consists of spontaneous involution, steroid therapy, and chemotherapy ("primum non nocere") (Shafer *et al.*, 1983; Patil, 2006). In the present case, based on the provisional diagnosis of PG and taking into the consideration of small size of the lesion without bony involvement, excisional biopsy was planned.

## Conclusion

Intraoral CH is an uncommon pathologic entity. Simple surgical excision of CH may lead to intraoperative and postoperative bleeding, and hence it should be performed with caution. Therefore, dental surgeons should be aware of these risks during diagnosis, and management and should take necessary precautions prior to the excision of apparently innocent lesions.

## REFERENCES

- Acikgoz A., Sakallioğlu U., Ozdamar S., Uysal A. 2000. Rare benign tumors of oral cavity-ncapillaryvhaemangioma of palatal mucosa: A case report. *Int J Paed Dent.*, 10:161-5.
- Bharti V., Singh J. 2012. Capillary hemangioma of palatal mucosa. *J Indian Soc Periodontol*, 16:475-8.
- Dahiya R., Kathuria A. 2014. Extralingival pyogenic granuloma histologically mimicking capillary hemangioma. *J Indian Soc Periodontol*, 8:641-3.
- Dilsiz A., Aydin T., Gursan N. 2009. Capillary hemangioma as a rare benign tumor of the oral cavity: A case report. *Cases J.*, 2:8622.
- Greene LA., Freedman PD., Friedman JM., Wolf M. 1990. Capillary hemangioma of the maxilla. A report of two cases in which angiography and embolization were used. *Oral Surg Oral Med Oral Pathol.*, 70:268-73.
- Kamala KA., Ashok L., Sujatha GP. 2014. Cavernous hemangioma of the tongue: A rare case report. *Contemp Clin Dent.*, 5:95-8.
- Kumari VR., Vallabhan CG., Geetha S., Nair MS., Jacob TV. 2015. Atypical presentation of capillary hemangioma in oral cavity- A case report. *J Clin Diagn Res.*, 9:26-8.
- Mehrotra MC. 1965. Capillary hemangioma of hard palate: A case report. *J All india Dent Assn.*, 37:11-2.
- Mulliken JB. 1990. Cutaneous Vascular Anomalies. In: Mccarthy JG, editor. *Plastic Surgery: Tumors of Head & Neck & Skin*. Vol.5. Philadelphia: B Saunders Company Ltd; pp. 3194-230.
- Murthy J. 2005. Vascular anomalies. *Indian J Plst Surg.*, 38:56-62.
- Patil K., Mahima VG., Ambika L. 2006. Extralingival pyogenic granuloma. *Indian J Dent Res.*, 17:199-202.
- Rachappa MM., Triveni MN. 2010. Capillary hemangioma or pyogenic granuloma: A diagnostic dilemma. *Contemp Clin Dent.*, 1:119-22.

- Satish V., Bhat M., Maganur PC., Shah P., Biradar V. 2014. Capillary hemangioma in maxillary anterior region: A case report. *Int J Clin Pediatr Dent.*, 7:144-7.
- Selvamuthukumar SC., Ashwath N., Anand V. 2010. Unusual presentation of pyogenic granuloma of buccal mucosa. *J Indian Acad Oral Med Radiol.*, 22:S45-7.
- Shafer WG., Hine MK., Levy BM. 1983. A Textbook of Oral pathology. 4<sup>th</sup> ed. Philadelphia: WB Saunders. pp. 359-60
- Silverman RA. 1991. Hemangiomas and vascular malformations. *Pediatr Clin North Am.*, 38:811-34.

\*\*\*\*\*