



ISSN: 0975-833X

Available online at <http://www.journalcra.com>

International Journal of Current Research
Vol. 11, Issue, 03, pp.2277-2283, March, 2019

DOI: <https://doi.org/10.24941/ijcr.34674.03.2019>

INTERNATIONAL JOURNAL
OF CURRENT RESEARCH

RESEARCH ARTICLE

PATHWAYS OF GASTRO PROTECTIVE POTENTIAL OF CHAMOMILE IN INDOMETHACIN INDUCED ULCEROGENIC IN RATS

Jamilah M. Hashemi

Food and Nutrition Department, Faculty of Home Economic, King Abdulaziz University, Saudi Arabia

ARTICLE INFO

Article History:

Received 25th December, 2018
Received in revised form
04th January, 2019
Accepted 09th February, 2019
Published online 31st March, 2019

Key Words:

Gastroprotective, Chamomile,
Rats, Pathways.

ABSTRACT

Indomethacin (IND) is an extensively used drug. However, it provokes aggressive ulcerogenic potential. Chamomile is a widely used as natural herb with a powerful antioxidant activity. This study aims to assess the effects of chamomile flowers extract (CFE) in IND induced peptic ulcer (PU). Fifty rats classified to five groups; control, ulcer, and pretreated groups with CFE (200 mg/kg), pretreated with ranitidine RAN (50 mg/kg), and pretreated with CFE+RAN for 14 days pre-ulcer induction. Pretreatment with CFE and/or RAN significantly decreased ulcer index, gastric acidity, pepsin activity, gastric oxidative stress biomarkers, serum anti-inflammatory cytokines, and histopathological changes induced by IND. The pretreated groups significantly elevated gastric enzyme antioxidant activity, mucin content and gastric mucosal prostaglandin E2 with comparison to IND group. Pretreatment with CFE+RAN displayed the most gastroprotective effects compared with pretreated with either CFE or RAN alone. Collectively, the antisecretory and cytoprotective effects of antioxidant and anti-inflammatory activities demonstrated by the CFE's gastroprotective action.

Copyright ©2019, Jamilah Hashemi. This is an open access article distributed under the Creative Commons Attribution License, which permits unrestricted use, distribution, and reproduction in any medium, provided the original work is properly cited.

Citation: Jamilah M. Hashemi, 2019. "Pathways of gastro protective potential of chamomile in indomethacin induced ulcerogenic in rats", *International Journal of Current Research*, 11, (03), 2277-2283.

INTRODUCTION

One of the greatest mortality and morbidity threats to the world's population in the last two centuries is PU which cover both gastric and duodenal ulcers (Chaturvedi *et al.*, 2007). The annual global incidence of PU is 0.1 to 1.5% and the prevalence is 0.03 to 0.19% (Albaqawi *et al.*, 2017). The disturbance of the corrosive effect of gastric juice, which alters the endogenous content of cytoprotective prostaglandins, lipids membrane and glutathione cause mucosal ulcer of gastric (Abdulla *et al.*, 2009; Abdulla *et al.*, 2010). The use of non-steroidal anti-inflammatory drugs (NSAIDs) and pylori infection account for more than 70% of the causative factor of PU (Ohyama *et al.*, 2012). Despite NSAIDs benefits as anti-inflammatory drugs, these drugs may cause PU (Lee *et al.*, 2016). In experiments, the IND is known to cause stomach ulcers and is more likely to cause gastric damage than other commonly used NSAID (El-Ashmawy *et al.*, 2016). In patients taking NSAIDs, there are various pathophysiological mechanism for PU. Incidence such as inhibiting cyclooxygenase (COX), followed by reduced prostaglandin production, which is responsible for mucosa protection (Bech *et al.*, 2000). Activation of lipoxygenase (LOX) by NSAIDs which lead to increased inflammatory response and direct mucosal injury are suspected as another mechanism (Chattopadhyay *et al.*, 2006). Current treatment for PU include antacids (non-systemic and systemic) and drugs that decrease secretion of the acid, such as anti-histamine ulcer cure and anti-histamine medicines for pylori (Saaidnia *et al.*, 2011).

These drugs have reduced the morbidity rate, but can cause many adverse effects, including recurrence of disease, and are often costly (Vivatvakin *et al.*, 2017). Traditional medicine is widely used and plants continue to be a major source of natural antioxidants that can lead to new drugs. Chamomile is one of the medicinal plants most commonly used in some countries (Ramadan and Emam, 2012). It is an annual plant containing various classes of biologically active compounds, especially flavonoids, essential oils and various acetylates (Chandrashekhar *et al.*, 2012). Terpenoids, abisabolol, and chamazulene oxide are the main components of essential oil from chamomile flowers (Bakr *et al.*, 2015; Kato *et al.*, 2008). It is also has different pharmacological effects, including anti-inflammatory, antioxidant and anticancer (Singh *et al.*, 2011). The administration of food and drugs (FDA) has documented that CFE is safe because it is on the list of "generally considered safe" (GRAS) (Duke, 2001). This study examined the protective effect of CFE on IND induced PU and compared the results with standard medicine (RAN).

MATERIALS AND METHODS

Material

Plant material: Chamomile (*Matricaria chamomilla*) flowers (CF) were collected during spring season 2018 from Tabuk region, north west of Saudi Arabia. Plant was identified by botanists in Pharmaceutical and Phytochemistry Department, Faculty of Pharmacy, KAU, Jeddah, Saudi Arabia.

Experimental rats and diet: Fifty male albino rats (200-220 g) were purchased from King Fahd Medical Research Center, KAU. Basal diet was provided from Baghafar Company for Pharmaceutical and Chemical, Jeddah, KSA.

Chemicals, kits and drugs: In Jeddah, Saudi Arabia, local pharmacies purchased ranitidine (RAN) (Zydac Tablet, 150 mg) and IND (Indocin Pharmaceuticals, USA, provided 50 mg IND / capsule). Other reagents and chemicals were obtained from Sigma - Aldrich (St Louis, MO, USA).

Methods

Olive leaves extract preparation: Fresh CF flowers were dried, then pulverized with a blinder to a fine powder. Dried CF (100 g) were extracted with ethanol 80 % under agitation, After the extract was filtered and concentrated in vacuum using a rotating evaporator, the extract was finally lyophilized, weighed [100 g yield 9.11 percent] and stored at 4 ° C until it was used (Sabiua *et al.*, 2015).

Induction of ulceration: Ulceration of peptic was done by the IND (30 mg/kg) ingestion to animals after fasting as described by Sabiua *et al.*, (2015). Ulceration lesions had manifested four hours after administration of IND.

Experimental grouping: Fifty Albino rats with a mean weight (210 ± 10 g) were used in this study. Upon approval for KAU laboratory animals by the Ethical Committee. Rats were divided into five groups of ten rats: Control; rats received only distilled water. Ulcerated group; rats received only distilled water intragastrically for 2 weeks before administrated IND (30 mg/kg). CFE+IND group; rats were given the CFE (200 mg/kg/day p.o), for 14 days before an oral dose of IND. The CFE dose was chosen according to Mustafa *et al.* (2013). RAN+ IND group; rats were given the RAN (50 mg/kg) for 14 days before IND administration and served as a standard drug (Rao *et al.*, 2014). CFE+RAN+IND group; rats were given the CFE and RAN at the same given dose for 14 days before an oral dose of IND. After four h of IND administrated, the rats were sacrificed. Gastric from all rats were dissected out, and their content was evacuated into a centrifuge tube. Cleaned stomach was processed for chemical and histopathological examination.

Quantification of gastric ulceration: The degree of ulceration in all IND - treated rats was quantified using the Szabo and Hollander method (Rao *et al.*, 2014). The Image Pro Express computer analyzer system was used to quantify the gastric interface of each rat. The total area of mucosal damage was calculated as a percentage of the estimated square mm of the total ulcer area. Ulcer index and ulcer inhibition percentage were calculated using the following equations:

Ulcer index (UI) = Ulcerated area / Total area of mucosa X 100
Percentage ulcer inhibition = UI (IND group) – UI (treated group) / UI (IND group) × 100

Gastric mucosal lesion biomarkers: Stomach juice was diluted and centrifuged 10 minutes at 3000 rpm. In biochemical analyses, the supernatant was then used. The pH of the gastric juice was determined by a pH meter (Dashputre *et al.*, 2011). Pepsin activity and mucin concentrations were determined by Sanyal *et al.* (1971). Gastric acidity was detected in the supernatant by the titration of 0.01 NaOH using

the reagent Toepfer as an indicator and expressed as mEq / L. (Szabo and Hollander, 1985).

Preparation of gastric homogeneity and testing of biomarkers of oxidative stress: Gastric tissue samples (100 mg) were homogenized in ice cold 0.1 M PBS and centrifuged at 2500 rpm for 10 min using a Teflon pestle. The resulting supernatants were frozen at -20 ° C until used. Lipid peroxidation (MDA) level and the activity of superoxide dismutase (SOD) were measured by using ELISA kits as described in manufacturer's procedures.

Determination of gastric mucosal prostaglandin E2: In gastric supernatants, prostaglandin E2 (PGE2) levels were assessed in accordance with the manufacturer's instructions using an ELISA kits.

Assay serum levels of inflammatory: It used serum samples to evaluate interleukin-6 (IL-6) and tumor necrosis factor -α (TNF-α). All procedures have been carried out as described in the instructions of the manufacturer.

Histopathological studies: Fixed gastric tissues by formaldehyde (10 percent) from each group were stained with Hematoxylin-Eosin (H&E), then microscopically examined.

Statistical: The statistics were carried out using SPSS version 22 by an ANOVA one - way analysis of variance (LSD). Data were reported as mean ± SE.

RESULTS

The impact of CFE on the ulcer index and ulcer inhibition rate % are shown in Table 1. In rats, IND administration caused a significant increase in the degree of ulceration (UI) ($p < 0.001$). There was significant protection against ulceration in the level of inhibition in pretreated groups with CFE and/or RAN. Pretreatment with CFE+RAN offered better protection against ulceration compared CFE and reference drug RNA used, with percent 78.77.

Table 1. Effect of chamomile (*Matricaria chamomilla*) flowers (CF) hydroalcoholic extract and/or ranitidine (RAN) on quantification of gastric ulceration against ulcerated rats by indomethacin (IND)

Groups	UI nm ²	Ulcer inhibition rate %
Cont	0.00	-
Ulcer	34.85 ± 3.14 ^{&}	-
CFE+ Ulcer	23.60 ± 1.96 ^{*,*}	32.28
RAN+ Ulcer	21.55 ± 1.47 ^{*,*,&}	38.16
CFE+ RAN+ Ulcer	7.40 ± 0.76 [#]	78.77

Results are illustrated as mean ± SE (n = 10). [&] Significant versus cont, [#] Significant versus ulcer, * Significant versus CFE+ RAN+ Ulcer, and [@] Significant between CFE +Ulcer and RAN+ Ulcer group.

The effect of CFE and/or RAN on ulcerated IND rats' gastric secretions is shown in Table 2. In a group of ulcers. The pH value decreased significantly compared to control rats, with a significant increase in total gastric acidity. The CFE and/or RAN pretreatment resulted in a significant decrease in total gastric acidity and a significant increase in pH compared to IND ulcerated rats. The oral administration of 30 mg/kg of IND led to a significant increase in pepsin activity, with a significant reduction in the mucin content of gastric juice compared to control rats. Pretreatment with CFE and/or RAN induced significantly attenuated in these parameters, where

Table 2. Effect of chamomile (*Matricaria chamomilla*) flowers (CF) hydroalcoholic extract and/or Ranitidine (RAN) on gastric mucosal lesions biomarkers against ulcerated rats by indomethacin (IND)

Groups	Gastric pH	Gastric acidity	Pepsin activity ($\mu\text{g/ml}$)	Mucin content ($\mu\text{g/ml}$)
Cont	3.93 \pm 0.13	54.86 \pm 2.67	102.10 \pm 2.86	368.20 \pm 4.29
Ulcer	2.51 \pm 0.19 ^{&}	169.58 \pm 11.43 ^{&}	288.93 \pm 4.25 ^{&}	214.10 \pm 5.32 ^{&}
CFE+Ulcer	3.36 \pm 0.21 [#]	92.38 \pm 5.04 ^{#,*}	154.83 \pm 2.40 ^{#,*}	326.40 \pm 4.84 ^{#,*}
RAN+Ulcer	3.61 \pm 0.12 [#]	75.09 \pm 7.60 ^{#,@}	136.30 \pm 1.55 ^{#,*,@}	357.00 \pm 11.66 ^{#,*,@}
CFE+RAN+Ulcer	3.77 \pm 0.15 [#]	65.97 \pm 4.23 [#]	123.10 \pm 3.07 [#]	381.30 \pm 4.69 [#]

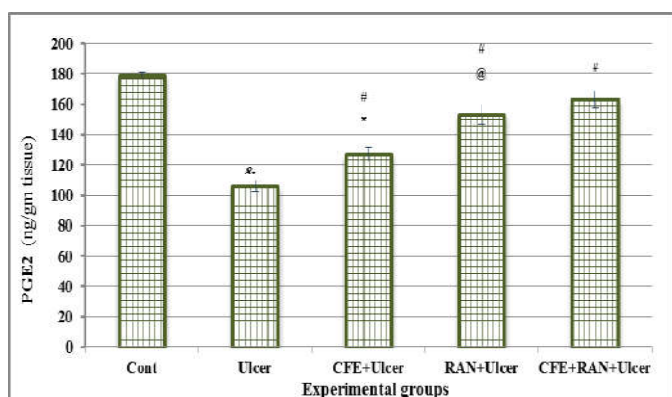
Results are illustrated as mean \pm SE (n = 10). [&] Significant versus cont, [#] Significant versus ulcer, ^{*} Significant versus CFE+ RAN+ Ulcer, and [@] Significant between CFE +Ulcer and RAN+ Ulcer group.

Table 3. Effect of chamomile (*Matricaria chamomilla*) flowers (CF) hydroalcoholic extract and/or Ranitidine (RAN) on oxidative stress biomarkers against ulcerated rats by indomethacin (IND)

Groups	MDA ($\mu\text{mol/g tissue}$)	SOD ($\mu\text{mol/g tissue}$)
Cont	0.26 \pm 0.011	70.94 \pm 2.18
Ulcer	0.91 \pm 0.092 ^{&}	47.99 \pm 2.54 ^{&}
CFE+Ulcer	0.28 \pm 0.008 [#]	70.26 \pm 2.49 [#]
RAN+Ulcer	0.34 \pm 0.031 ^{#,@}	59.04 \pm 1.67 ^{#,@}
CFE+RAN+Ulcer	0.24 \pm 0.013 [#]	72.18 \pm 2.39 [#]

Results are illustrated as mean \pm SE (n = 10). [&] Significant versus cont, [#] Significant versus ulcer, ^{*} Significant versus CFE+ RAN+ Ulcer, and [@] Significant between CFE +Ulcer and RAN+ Ulcer group.

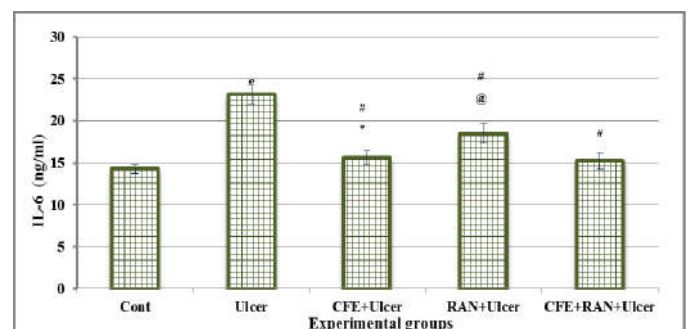
pepsin activity was significantly reduced and the mucin content of gastric juice was significantly increased compared to IND ulcerated rats. Pretreatment with both CFE + RAN showed strong efficacy in attenuated gastric juice in both pepsin and mucin compared to pre-treated CFE or RNA groups. Table 3 shows the biomarkers of oxidative stress. IND administration significantly increased the level of gastric MDA with a significant decline in gastric SOD compared to the control group. Pretreatment with CFE and/or RNA significantly reduced the level of stomach MDA and significantly increased the activity of stomach SOD compared to the IND ulcerated group. Oral administration of both CFE + RAN showed the most effective outcome compared to pretreatment with either CFE or RNA alone, there was a significant difference compared to the RNA treated reference drug group. Administration of IND significantly decline the gastric PGE2 level compared with control rats. Pretreatment with CFE and /or RNA significantly increased the gastric PGE2 level compared with IND ulcerated group. Pretreatment with both CFE+RAN showed the potent effective compared with either pretreated with CFE or RNA alone, there were significant difference compared with reference drug RNA-pretreated group Figure 1.



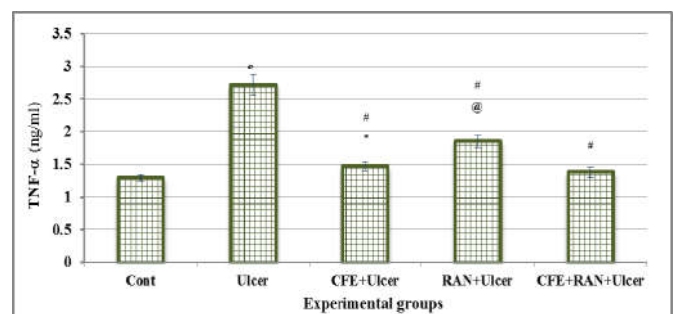
Results are illustrated as mean \pm SE (n = 10). [&] Significant versus cont, [#] Significant versus ulcer, ^{*} Significant versus CFE+ RAN+ Ulcer, and [@] Significant between CFE +Ulcer and RAN+ Ulcer group.

Figure 1. Effect of chamomile (*Matricaria chamomilla*) flowers (CF) hydroalcoholic extract and/or Ranitidine (RAN) on gastric mucosal prostaglandin E2 (PGE2) against ulcerated rats by indomethacin (IND)

Interleukin-6 (IL-6) and tumor necrosis factor α (TNF- α) have been increased by IND administration. The CFE and/or RNA pretreated groups significantly reduces serum IL-6 and TNF- α levels compared to IND ulcerated group. Pretreatment with both CFE+RAN showed the most effective compared with either pretreated with CFE or RNA alone, there was a significant difference compared with reference drug RNA-pretreated group Figures 2 and 3.



Results are illustrated as mean \pm SE (n = 10). [&] Significant versus cont, [#] Significant versus ulcer, ^{*} Significant versus CFE+ RAN+ Ulcer, and [@] Significant between CFE +Ulcer and RAN+ Ulcer group.

Figure 2. Effect of chamomile (*Matricaria chamomilla*) flowers (CF) hydroalcoholic extract and/or Ranitidine (RAN) on serum interleukin-6 (IL-6) against ulcerated rats by indomethacin (IND)

Results are illustrated as mean \pm SE (n = 10). [&] Significant versus cont, [#] Significant versus ulcer, ^{*} Significant versus CFE+ RAN+ Ulcer, and [@] Significant between CFE +Ulcer and RAN+ Ulcer group.

Figure 3. Effect of chamomile (*Matricaria chamomilla*) flowers (CF) hydroalcoholic extract and/or Ranitidine (RAN) on serum tumor necrosis factor α (TNF- α) against ulcerated rats by indomethacin (IND)

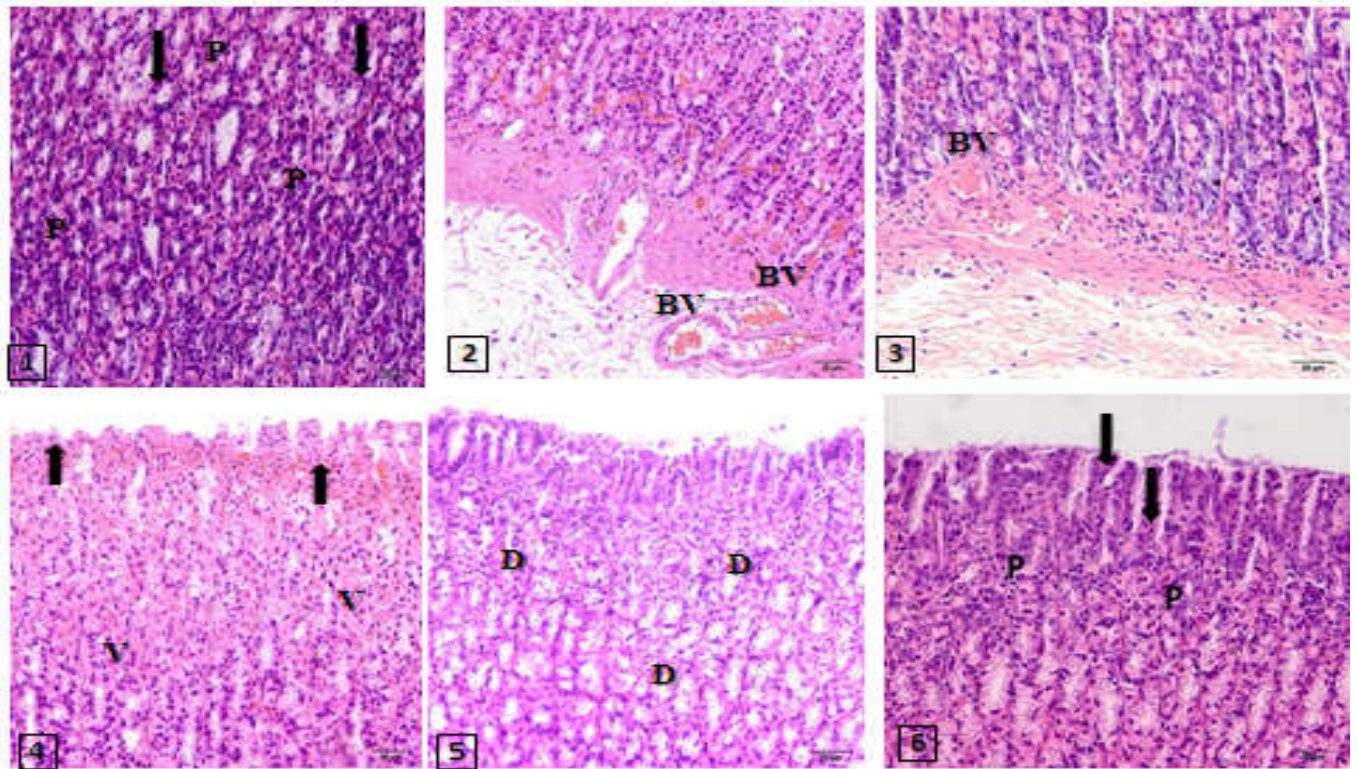


Figure 4. Effect of chamomile flowers (CF) hydroalcoholic extract and/or Ranitidine (RAN) on the gastric tissue ulcerated with indomethacin (IND) in rats (H&E staining). Stomach photomicrograph of a control rat showing central rounded nuclei (P) and eosinophilic cytoplasm, basal oval surface epithelial nuclei (arrows) and flat basal nuclei mucous neck cells [1]. An IND-group stomach showing areas with loss of surface epithelium architecture, mononuclear cell infiltration and dilated blood vessels (BV) in the mucosa and submucosa. Notice spacing of connective tissue fibers are wide [2 and 3]. A photomicrograph of the stomach of a CFE +IND group showing vacuolization of the cytoplasm of parietal cells (V) and gastric pits with hyperemia (arrows) [4]. A photomicrograph of the stomach of a RNA+IND group showing the apparently near-normal stomach architecture. The lumen of the gland is dilated (D). Increased vascularity is also apparent [5]. A photomicrograph of the stomach of a CFE+RNA+IND group showing the apparently normal glands. There are areas of mucous secreting cells that cover the surface and alternate with areas of deep eosinophilic surface ,epithelial cells and mucous neck cells with flat basal nuclei (arrows)

Figure 4.1 showed control stomach with no histopathological changes. The administration of IND induced loss of the stomach architecture of superficial epithelium, mononuclear cellular infiltration and dilated blood vessels in the mucosa and submucosa (Fig. 4.2 and Fig.4.3). Pretreatment with CFE pre-IND ingestion showing hyperemia vacuolization of parietal cells cytoplasm and gastric pits (Fig.4.4). The lumen of the gland is dilated with increased vascularity in as well as the stomach of RNA + IND group showing almost normal stomach architecture (Fig. 4.5). A photomicrograph of the CFE + RNA + IND group's stomach showing the apparently normal glands (Figure 4.6).

DISCUSSION

The main risk factor for PU is the use of NSAIDs (Abdel-Rahman *et al.*, 2015). The proposed gastric damage mechanism caused by NSAIDs is to inhibit the synthesis of prostaglandin and proliferate epithelial cells in the ulcer margin, which is critical to the incidence of ulcer (Hiruma-Lima *et al.*, 2006). Peptic ulcer disease is a problem of the gastrointestinal tract characterized by mucosal damage caused by gastric acid and pepsin secretion (Kalyanakrishnan *et al.*, 2007). The objective of the study was to estimate the influence of CFE as antiulcer and to compare its effect to the antiulcer reference drug RAN. The results showed a significant increases in the total gastric acidity and ulcer index with a significant decrease in pH in the ulcerated group compared to the control group.

Pretreatment with CFE as well as RAN showed marked improvement on the gastric lesions and gastric oxidative stress biomarkers as well as PGE₂, TNF- α and IL-6 compared with IND ulcerated rats. The most effective protective pretreatment was seen in the rats co-pretreated with both CFE and RAN compared with other pretreated groups. The obtained results were in the same line with the study done by Shahin *et al.* (2018) who demonstrated that the elevated gastric acidity associated with ulceration induced by IND was reduced compared with RAN treated group. The NSAIDs inhibit cyclooxygenase and thus blocking PGE₂, Which had cytoprotective effects on gastric mucosa that could explain the observed effects of IND as a major cause of ulceration on prostaglandins (Ohyama *et al.*, 2012). Ranitidine is a histamine 2 receptor antagonist. It is used to treat PU and other gastrointestinal acid conditions (Minai-Tehrani *et al.*, 2012). In addition, Brzozowski *et al.* (2000) reported that RAN suppressed the secretion of gastric acid and gastric ulcer. The CFE's influence as antiulcer characterized by a reduction in the secretion of acid, pepsin and the volume of gastric juice (Karbalay-Doust *et al.*, 2009). Its activity against ulcers can be attributed to its active compounds, including, numerous phenolic compounds in particular flavonoids, various acetylates and essential oils (McKay and Blumberg, 2006). Chamazulene oxide and α -bisabolol terpenoids are the main components of the essential oil extracted from chamomile (McKay and Blumberg, 2006). In the etiology of gastric mucosal damage caused by IND, these active compounds may stimulate the secretion of mucus, bicarbonate, and

prostaglandin. as well as counteract the deteriorating effects of reactive species of oxygen (Naito *et al.*, 2005). Mucine is an important protective factor for gastric mucosa, which consists of glycoprotein covering the entire gastrointestinal mucosa (Penissi and Piezzi, 1999). In this study, the reduction of mucin secretion in IND rats led to a reduction in the ability of the mucosal membrane to protect the mucosa against physical damage. Endogenous and exogenous active oxygen and free radicals can easily cause mucosal damage (Repetto *et al.*, 2012). Increased production of mucus helps in healing the ulcer against irritant secretions of the stomach (pepsin and HCl) and thus increases the rate of local healing. Increasing the mucin content in CFE pretreatment group protected the gastrointestinal mucosa from damage. It contribute to the protection of oxidative damage of the gastric mucosa (McKay *et al.*, 2006). It is known that IND induces reactive metabolites of oxygen in animal models that can cause mucosal injury to cell enzymes (Chattopadhyay *et al.*, 2006). This may lead to increased damage to the tissue during stomach ulceration. The results of this study showed that IND administration led to a significant increase in gastric MDA with a reduction in gastric SOD activity and PGE2 in ulcerated rats. The obtained results agreed with Vivatvakin *et al.* (2017). In addition, Parvan *et al.* (2017) informed that IND induces an increase in lipid peroxidation and produces free radicals in gastric mucosa. These changes lead to increased toxic radicals of oxygen superoxide. Moreover, Koc *et al.* (2008) summarized that IND had a significant reduction in antioxidant enzyme levels and an elevatio in MDA compared to the RAN group.

The IND's effects had been explained by inhibiting the release of protective factors like PGE2, cyclooxygenase-1 (COX-1), mucus and bicarbonate (Sheeba *et al.*, 2016). However, Sahoo and Kanhar (2017) reported that the activity of all antioxidant enzymes in gastric mucosa were significantly reduced 6 hours after oral administration of IND compared to control rats, indicating acute inflammatory injury. In the present study the results revealed that RAN showed a protective effect against oxidative stress induced by IND. The RAN pretreated group and the IND group differed significantly these results agreed with Kath and Gupta (2006) who demonstrated that in the group orally administered RAN increases SOD, thus possibly because its main role is blockade of H2 receptors. Antioxidant act as radical scavengers, inhibit lipid peroxidation and other processes mediated by free radicals, so they can protect against various diseases caused by radical reactions (Czinner *et al.*, 2001). In the present study pretreatment with CFE showed an antioxidant effects, there was a marked improvement in oxidative stress biomarker MDA and significant increase in SOD activity compared with IND ulcerated rats. The obtained results agreed with Giorgi *et al.* (Giorgi *et al.*, 2009). A variety of mineral elements, including magnesium and 1-2 percent volatile oils in chamomile flowers, can be associated with the anti-ulcer action of CFE (McKay *et al.*, 2006). Hwang *et al.* (2008) reported that the CFE contains many components that can have antiulcer effects. The main flavonoids in the flower are phenolic and flavonoids, quercetin, luteolin, patuletin, and their glycosides. Karbalay and Noorafshan (Karbalay *et al.*, 2009) summarized oral intake of CFE at four hundred mg/ kg can prevent gastric ulceration in mice. The TNF- α and IL-6 are pro-inflammatory cytokines that during ulcerative stress are increasingly secreted by macrophages (Hamaguchi *et al.*, 2001). They stimulate neutrophil infiltration into the gastrointestinal mucosa (Wei *et al.*, 2003). Inhibition of IL-6 and TNF- α infiltration inhibits the destruction of tissues by

reactive species of oxygen (Kwiecien *et al.*, 2002). The IND increased TNF- α and IL-6 significantly compared to the control group in the study. This finding coincided with Appleyard *et al.* (1996) who documented that the pretreatment of rats with CFE at 200 mg/ kg was significantly reduced serum anti-inflammatory cytokines concentrations. Anti-inflammatory activity of CFE could be attributed to the suppression of anti-inflammatory cytokines production, which affects the myeloperoxidase catalytic reactions (Glowania *et al.*, 1997). Histological results of the Ketuly *et al.* (Ketuly *et al.*, 2011) summarized that the gastric walls of ulcer groups induced by IND had severe damage to the gastric mucosa, edema, infiltration of the submucosal layer and leucocytes. The same results were shown in the recent study. On the other hand, the control and pre-treated groups in a recent study showed normal architecture in the gastric mucosa. The CFE pretreated rats showed improvements in their examined stomach tissues. Therefore the protective effect of CFE confirmed by histopathological and biochemical examinations, In conclusion, the results of the current work prove that CFE's antioxidant and anti-inflammatory activities have inhibited physiological and histopathological changes caused by IND. Therefore, CFE exhibited a possible therapeutic option to prevent IND- induced PU.

REFERENCES

- Chaturvedi, A., Kumar, M.M., Bhawani, G., Chaturvedi, H., Kumar, M. and Goel, K.R. 2007. Effect of ethanolic extract of *Eugenia Jambolana* seeds on gastric ulceration and secretion in rats. *Indian J. physiol. Pharmacol.*, 51(2): 131-140.
- Albaqawi, A.S.B., El-fetoh, N.M.A., Alanazi, R.F.A., Alanazi, N.S.F., Alrayya, S. E., Alanazi, A.N.M., Alenezi, S.Z.T., Alanazi, R.A.A., Alshalan, A.M., Alenezi, O.T. and Ali, W.M.B. 2017. Profile of peptic ulcer disease and its risk factors in Arar, Northern Saudi Arabia. *Electron Physician*, Vol.9(11): 5740-5745.
- Abdulla, M.A., Ali, H.M., Ahmed, K.A.A., Noor, S.M. and Ismail, S. 2009. Evaluation of the anti-ulcer activities of *Morus alba* extracts in experimentally-induced gastric ulcer in rats. *BioMed Research International*, Vol.20(1):35-39.
- Abdulla, M.A., Al-Bayaty, F.H., Younis, L.T., & Hassan, M.I.A. 2010. Anti-ulcer activity of *Centella asiatica* leaf extract against ethanol-induced gastric mucosal injury in rats. *Journal of Medicinal Plants Research*, Vol.4 (13):1253-1259.
- Ohyama, K., Shiokawa, A., Ito, K., Masuyama, R., Ichibangase, T., Kishikawa, N., Imai, K. and Kuroda, N. 2012. Toxicoproteomic analysis of a mouse model of nonsteroidal anti-inflammatory drug-induced gastric ulcers. *Biochemical and Biophysical Research Communications*, Vol. 420(1): 210-215.
- Lee, H.L., Chua, S.S. and Mahadeva, S. 2016. Utilization of gastroprotective strategies for nonsteroidal anti-inflammatory drug-induced gastrointestinal events in a major teaching hospital. *Her Clin Risk Manag*, Vol.12: 1649-1657.
- El-Ashmawy, N.E., Khedr, E.G., El-Bahrawy, H.A. and Selim, H.M. 2016. Gastroprotective effect of *garlic* in indomethacin induced gastric ulcer in rats. *Nutrition*, Vol.32 (7-8):849-854.
- Bech, P.L., Xavier, R., Lu, N., Nanda, N.N., Dinauer, M., Podolsky, D.K. and Seed, B. 2000. Mechanisms of

- NSAID-induced gastrointestinal injury defined using mutant mice. *Gastroenterology*, 119(3):699-705.
- Chattopadhyay, I., Bandyopadhyay, U., Biswas, K., Maity, P. and Banerjee, R.K. 2006. Indomethacin inactivates gastric peroxidase to induce reactiveoxygen-mediated gastric mucosal injury and curcumin protects it by preventing peroxidase inactivation and scavenging reactive oxygen. *Free Radic. Biol. Med.*, 40(8):1397-1408.
- Saeidnia, S., Gohari, A. R., Mokhber-Dezfuli, N. and Kiuchi, F. 2011. A review on phytochemistry and medicinal properties of the genus *Achillea*. *Journal of Faculty of Pharmacy*, Vol.19(3):173-186.
- Vivatvakin, S., Werawatganon, D., Somanawat, K., Klaikeaw, N. and Siriviriyakul, P. 2017. Genistein-attenuated Gastric Injury on Indomethacin-induced Gastropathy in Rats. *Pharmacogn Mag*, Vol.13(2): 306-310.
- Conforti, F., Sosa, S., Marrelli, M., Menichini, F., Statti, G., Uzunov, D., Tubaro, A. and Menichini, F. 2009. The protective ability of mediterranean dietary plants against the oxidative damage: The role of radical oxygen species in inflammation and the polyphenol, flavonoid and sterol contents, *Food Chemistry*, Vol. 112: 587-594.
- Ramadan, K. S. and Emam, M. A. 2012. Biochemical evaluation of antihyperglycemic and antioxidative effects of *matricaria chamomilla* leave extract studied in streptozotocin-induced diabetic rats, *International Journal of Research in Management and Technology*, Vol. 2: 2249-2263.
- Chandrashekhar, V. M., Nirav, M., Nidavani, R. B., Jignesh, N. and Ganapaty, S. 2012. Anti-ischemic effect of german Chamomile (*matricaria recutita* L. against ischemia/reperfusion induced myocardial damage in isolated rat heart, *Pharmacologia*, Vol. 3: 406-412.
- Bakr, S.H. and S.M. Baz, 2015. Therapeutic role of ginger and chamomile aqueous extract for peptic ulcer using experimental rats. *Life Sci. J.*, 12(6): 92-99.
- Kato, A., Minoshima, Y., Yamamoto, J., Adachi, I., Watson, A. and Nash, R. 2008. Protective effects of dietary Chamomile tea on diabetic complications, *J. Agric. Food Chem.*, Vol. 56: 8206-8211.
- Singh, O., Z. Khanam, N. Misra and M.K. Srivastava, 2011. Chamomile (*Matricaria chamomilla* L.): An overview. *Pharmacogn. Rev.*, 5: 82-95.
- Duke, J.A., 2001. Handbook of Medical herbs. 2 Ed., CRC Press LLC, pp: 398.
- Sabiua, S., Garuba, T., Sunmonuc, T., Ajani, E., Sulymana, A., Nuraina, I., Balogunc, A. 2015. Indomethacin-induced gastric ulceration in rats: Protective roles of *Spondias mombin* and *Ficus exasperate*. *Toxicology Reports*, 2 :261-267.
- Mustafa, C., Ezgi, Y.1, and Mehmet, E. B. 2013. Protective effect of *Matricaria chamomilla* on ethanol induced acute gastric mucosal injury in rats. *African Journal of Biotechnology*, 12(18): 2378-2385.
- Rao, M.R.K., Ganesan, A., Sundari, G.R., Kumar, M.S. and Jha, N.K. 2014. Treatment of peptic ulcer in animal model by *Sirucinni uppu* (Herbal salt of *Acalypha fruticosa* Forssk. *Der Pharmacia Lettre*, 6(3): 20-6.
- Szabo, S. and Hollander, D. 1985. Pathways of gastrointestinal protection and repair: mechanisms of action of sucralfate, *Am J Med.*, 86 (6A):23-31.
- Dashputre, N.L. and N.S. Naikwade, 2011. Evaluation of anti-ulcer activity of methanolic extract of *Abutilon indicum* Linn leaves in experimental rats. *Int. J. Pharm. Sci. Drug Res.*, 3:97-100.
- Sanyal, A.R., Denath, O.K., Bhattacharya, S.K. and Gode, K.D. 1971. The effect of cyproheptadine on gastric acidity, in: C.J. Pfeiffer (Ed.), *Peptic ulcer*, Scandinavian University Books, Munksgaard, 1971, pp. 312-318.
- Corne, S.J., Morrissey, S.M. and Woods, R.J. 1974. Proceedings: a method for the quantitative estimation of gastric barrier mucus, *J Physiol.*, 242 (2):116-117.
- Abdel-Rahman, R. F., Alqasoumi, S. I., El-desoky, A. H., Soliman, G. A., Pare, P. W. and Hegazy, M. E. F. 2015. Evaluation of the anti-inflammatory, analgesic and anti-ulcerogenic potentials of *Achillea fragrantissima* (Forssk). *South African Journal of Botany*, Vol.98: 122-127.
- Hiruma-Lima, C.A., Calvo, T.R., Rodriguez, C.M., Andrade, F.D.P., Vilegas, W. and Brito, A.R.M. 2006. Antiulcerogenic activity of *Alchornea castaneaefolia*: effects on somatostatin, gastrin and prostaglandin. *J. Ethnopharmacol.*, 104(1-2):215-224.
- Kalyanakrishnan, F. and Robert C. 2007. Peptic ulcer disease. *Am. Fam. Physician*, 76 (12), 1005-1013.
- Shahin, N. N., Abdelkader, N. F. and Safar, M. M. 2018. A novel role of irbesartan in gastroprotection against indomethacin-induced Gastric injury in rats: Targeting DDAH/ADMA and EGFR/ERK Signaling. *Scientific Reports*, Vol. 8(1):4280.
- Ohyama, K., Shiokawa, A., Ito, K., Masuyama, R., Ichibangase, T., Kishikawa, N., Imai, K. and Kuroda, N. 2012. Toxicoproteomic analysis of a mouse model of nonsteroidal anti-inflammatory drug-induced gastric ulcers. *Biochemical and Biophysical Research Communications*, Vol. 420(1): 210-215.
- Minai-Tehrani, D., Ghaffari, M., Sobhani-Damavandifar, Z., Minoui, S., Alavi, S., Osmani, R. and Ahmadi, S. 2012. Ranitidine induces inhibition and structural changes in sucrase. *Journal of Enzyme Inhibition and Medicinal Chemistry*, Vol. 27(4): 553-557.
- Brzozowski, T., Konturek, P. C., Konturek, S. J., Drozdowicz, D., Kwiecien, S., Pajdo, R., Bielanski, W. and Hahn, E. G. 2000. Role of gastric acid secretion in progression of acute gastric erosions induced by ischemia-reperfusion into gastric ulcers. *European Journal of Pharmacology*, Vol. 398(1): 147-158.
- Karbalay-Doust, S. and Noorafshan, A. 2009. Antiulcerogenic Effects of *Matricaria Chamomilla* Extract in Experimental Gastric Ulcer in Mice. *Iran. J. Med. Sci.*, 34(3), 198-203.
- McKay, D.L. and Blumberg, J.B., 2006. A review of the bioactivity and potential health benefits of chamomile tea (*Matricaria recutita* L. *Phytother. Res.*, 20, 519-530.
- Naito, Y., Yoshikawa, T., Matsuyama, K., Yagi, N., Arai, M., Nakamura, Y., Nishimura, S., Yoshida, N. and Kondo, M. 1995. Effects of oxygen radical scavengers on the quality of gastric ulcer healing in rats. *J. Clin. Gastroenterol.*, 21 Suppl 1:S82-S86.
- Penissi, A. and Piezzi, R. 1999. Effect of dehydroleucodine on mucus production: A quantitative study. *Dig. Dis. Sci.*, 44 (4):708-712.
- Repetto, M.G. and Llesuy, S.F. 2002. Antioxidant properties of natural compounds used in popular medicine for gastric ulcers. *Braz. J. Med. Biol.*, 35(5):523-534.
- Chattopadhyay, I., Bandyopadhyay, U., Biswas, K., Maity, P. and Banerjee, R.K. 2006. Indomethacin inactivates gastric peroxidase to induce reactiveoxygen-mediated gastric mucosal injury and curcumin protects it by preventing peroxidase inactivation and scavenging reactive oxygen. *Free Radic. Biol. Med.*, 40(8):1397-1408.

- Vivatvakin, S., Werawatganon, D., Somanawat, K., Klaikeaw, N. and Siriviriyakul, P. 2017. Genistein-attenuated Gastric Injury on Indomethacin-induced Gastropathy in Rats. *Pharmacogn Mag*, Vol.13(2): 306-310.
- Parvan, M., Sajjadi, S.-E. and Minaiyan, M. 2017. Protective effect of two extracts of *cydonia oblonga miller (quince)* fruits on gastric ulcer induced by indomethacin in rats. *International Journal of Preventive Medicine*, Vol.8: 58.
- Koc, M., Imik, H. and Odabasoglu, F. 2008. Gastroprotective and anti-oxidative properties of ascorbic acid on indomethacin-induced gastric injuries in rats. *Biological Trace Element Research*, Vol. 126(1-3):222-236.
- Sheeba, M., Philip, S., Tom, G., Gayathri, L. and ASha, V. V. 2016. Comparative evaluation of the efficacy of *Cardiospermum halicacabum linn.* on Indomethacin, Pylorus ligation and Helicobacter pylori induced gastric ulcer in rats. *Annals of Phytomedicine*, Vol.(1): 63-72.
- Sahoo, A.K. and Kanhar, S. 2017. Antioxidant and antiulcer potential of hydrolea Zeylanica (L.. vahl against gastric ulcers in rats. *International Journal of Complementary and Alternative Medicine*, Vol.10 (1): 120-29.
- Kath, R. K. and Gupta, R. K. 2006. Antioxidant activity of hydroalcoholic leaf extract of *Ocimum sanctum* in animal models of peptic ulcer. *Indian Journal of Physiology and Pharmacology*, Vol.50(4):391.
- Czinner, E., Hagymási, K., Blázovics, A., Kery, Á., Szőke, É. and Lemberkovics, É. 2001. The *in vitro* effect of *Helichrysi flos* on microsomal lipid peroxidation. *Journal of Ethnopharmacology*, Vol. 77(1): 31-35.
- Giorgi, A., Bombelli, R., Luini, A., Speranza, G., Cosentino, M., Lecchini, S. and Cocucci, M. 2009. Antioxidant and cytoprotective properties of infusions from leaves and inflorescences of *Achillea collina* Becker ex Rchb. *Phytother Res*, Vol. 23(4): 540-545.
- Hwang, H.J., Kwon, M.J., Kim, I.H. and Nam,T.J., 2008. The effect of polysaccharide extracted from the marine alga *capsosiphon fulvescens* on ethanol administration. *Food Chem. Toxicol.*, 46, 2653-2657.
- Karbalay, S. and Noorafshan, A., 2009. Antiulcerogenic Effects of Matricaria Chamomilla Extract in Experimental Gastric Ulcer in Mice. *Iran. J. Med. Sci.*, 34(3), 198-203.
- Hamaguchi, M., Watanabe, T., Higuchi, K.,Tominaga, K., Fujiwara, Y. and Arkawa, T. 2001. Mechanisms and roles of neutrophil infiltration in stress-induced gastric injury in rats. *Dig. Dis. Sci.*, 46(12):2708-2715.
- Wei, X.M., Heywood, G.J., Di Girolamo, N. andThomas, P.S. 2003. Nicorandil inhibits the release of TNF alpha from a lymphocyte cell line and peripheral blood lymphocytes. *Int. Immunopharmacol.*, 3(12):1581-1588.
- Kwiecien, S., Brzozowski, T. and Konturek, S.J. 2002. Effects of reactive oxygen species on gastric mucosa in various models of mucosal injury. *J. Physiol. Pharmacol.*, 53(1):39-50.
- Appleyard, C.B., McCafferty, D.M., Tigley, A.W.,Swain, M.G. and Wallace, J.L. 1996. Tumor necrosis factor mediation of NSAID-induced gastric damage: role of leukocyte adherence. *Am. J. Physiol. Gastrointest. Liver Physiol.*, 270:G42-G48.
- Glowania, H.J., Raulin, C. and Swoboda, M.,(1997. Effect of chamomile on wound healing- a clinical doubleblind study. *Z. Hautkr.* 62,1262-1271.
- Ketuly, Abdulla, M., A. Hadi, H., Mariod, A. and Abdelwahab, S. 2011. Anti-ulcer activity of the 9alpha-bromo analogue of Beclomethasone dipropionate against ethanol-induced gastric mucosal injury in rats. *Journal of Medicinal Plants Research*, Vol. 5(4): 514-520.
