



ISSN: 0975-833X

Available online at <http://www.journalcra.com>

International Journal of Current Research  
Vol. 11, Issue, 04, pp.2922-2924, April, 2019

DOI: <https://doi.org/10.24941/ijcr.35057.04.2019>

INTERNATIONAL JOURNAL  
OF CURRENT RESEARCH

## REVIEW ARTICLE

### BONE MARROW EXAMINATION FOR METASTATIC TUMOR–A CASE SERIES

\*<sup>1</sup>Dr. Anurita Saigal, <sup>2</sup>Dr. Pooja Murgai, <sup>3</sup>Dr. Sudarshan Kumar Sharma, <sup>4</sup>Dr. Anchana Gulati, and <sup>5</sup>Dr. Rajni Kaushik

<sup>1</sup>Junior Resident, Department of Pathology, I.G.M.C, Shimla

<sup>2</sup>Assistant Professor, Department of Pathology, I.G.M.C, Shimla

<sup>3</sup>Professor & HOD, Department of Pathology, I.G.M.C, Shimla

<sup>4</sup>Associate Professor, Department of Pathology, I.G.M.C, Shimla

<sup>5</sup>Professor, Department of Pathology, I.G.M.C, Shimla

#### ARTICLE INFO

##### Article History:

Received 07<sup>th</sup> January, 2019

Received in revised form

14<sup>th</sup> February, 2019

Accepted 07<sup>th</sup> March, 2019

Published online 29<sup>th</sup> April, 2019

##### Key Words:

Metastasis, Bone marrow,  
Aspiration, Trephine biopsy.

Copyright©2019, Anurita Saigal et al. This is an open access article distributed under the Creative Commons Attribution License, which permits unrestricted use, distribution, and reproduction in any medium, provided the original work is properly cited.

Citation: Dr. Anurita Saigal, Dr. Pooja Murgai, Dr. Sudarshan Kumar Sharma, Dr. Anchana Gulati and Dr. Rajni Kaushik. 2019. "Bone marrow examination for metastatic tumor–a case series", *International Journal of Current Research*, 11, (04), 2922-2924.

#### ABSTRACT

Bone marrow is involved in large number of diseases which primarily are not diseases of the hemopoietic system. The bone marrow biopsy is an important investigation in the work up of patients with malignancies that have a propensity to involve bone marrow. The aim of the study was to observe the clinical presentation and hematological profile of patients with metastatic bone marrow tumors. This highlights the importance of performing bilateral bone marrow aspiration and trephine biopsy in such patients and significance of correlation of the aspirate and biopsy findings.

## INTRODUCTION

The bone marrow is one of the organs involved by tumors that metastasize via the blood stream. Bone marrow examination is commonly used in the evaluation of hemato-oncological disorders and in patients with cancer of solid organs to detect metastases. In adults the tumors most often seen are carcinomas of the prostate, breast and lung, although any tumor that gives rise to blood borne metastases may infiltrate the marrow<sup>1</sup>. We studied 2 cases having clinical, hematological and pathological data with bone marrow metastases from solid tumors in Department of pathology, IGMC, Shimla.

### Case History

**CASE 1:** 45 year old male presented with upper back pain since 9 days. There was no organomegaly, no lymphadenopathy. CT chest showed multiple nodules over pleura. NCCT Dorsal spine-diffusely multiple lytic areas involving lytic areas involving cervico-dorsal vertebrae, ribs and sternum. Patient was recently diagnosed with Adenocarcinoma of lung on fine needle aspiration and histopathological examination. Adenocarcinoma of lung on fine needle aspiration and histopathological examination.

**CASE 2:** 54 year old male came with a chief complaint of generalised weakness, and loss of appetite since 14 days. On examination pallor and pedal edema were present. PSA levels were raised. AST, ALP, GGTP levels were also raised. Patient was a known case of carcinoma prostate. Bone marrow aspiration and trephine biopsy were performed on these patients to rule out metastases.

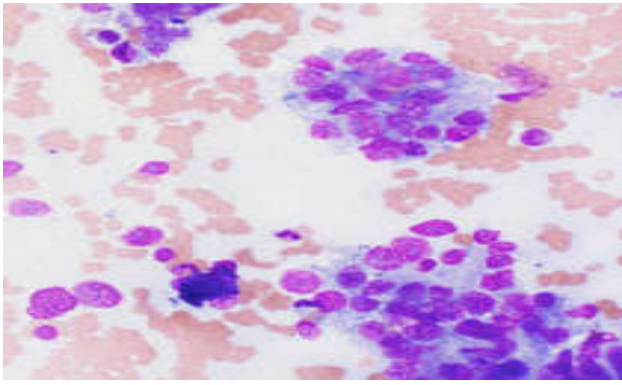
## RESULTS

Hematological profile revealed severe anemia in one patient, and thrombocytopenia in both patients. However, circulating malignant cells were not found in any of the patient. Malignant cells were present in the aspirate smears in both patients. (Figure 1,2 & 3). Bone marrow biopsy showed metastatic tumor deposits in both patients (Figure 4,5 & 6).

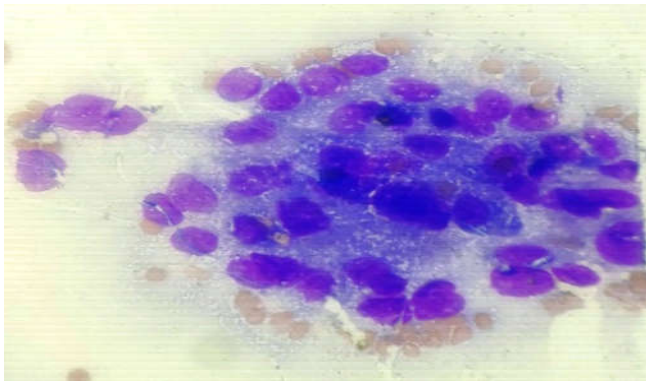
## DISCUSSION

The bone marrow metastasis by nonhematologic malignancies is a rare event. After lymphoma, in adults the tumors most often seen to metastasize are carcinomas of the prostate, breast, and lungs. It is done in patients with abnormal peripheral blood findings (presence of atypical cells/blasts, unexplained cytopenias) or with radiological investigations suggesting bone marrow involvement (Bain, 2001).

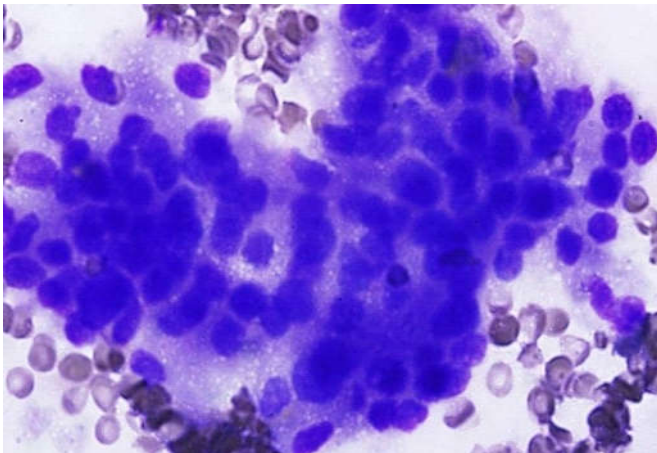
\*Corresponding author: Dr. Anurita Saigal,  
Junior Resident, Department of Pathology, I.G.M.C, Shimla



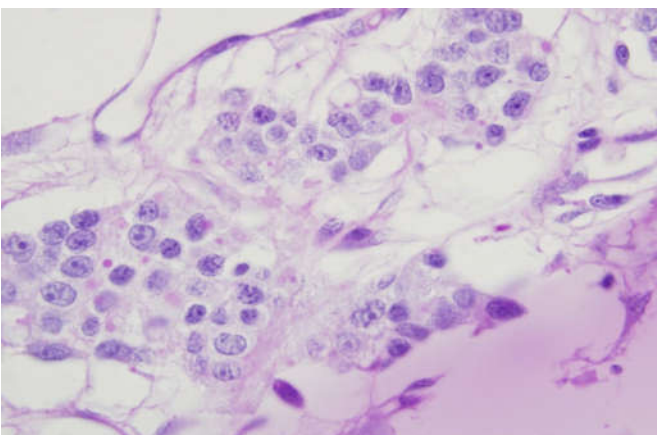
**Figure 1. Metastasis by tumor cells in aspiration smears (known case of lung carcinoma) (H & E 400X)**



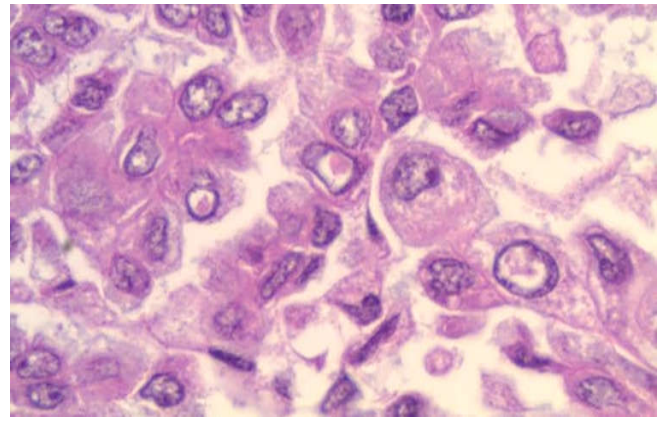
**Figure 2. Metastasis by tumor cells in aspiration smears (K/C/O of carcinoma prostate) (H & E 1000X)**



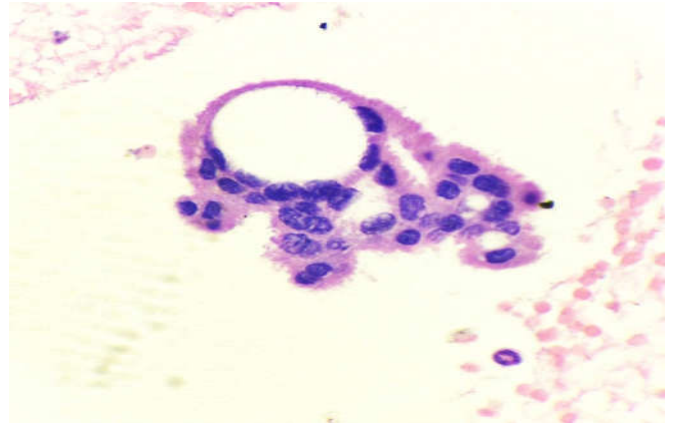
**Figure 3. Metastasis by tumor cells in aspiration smears (K/C/O of carcinoma prostate) (H & E 1000X)**



**Figure 4. Bone marrow biopsy shows metastatic tumor deposits (Lung carcinoma) (H & E 400X)**



**Figure 5. Bone marrow biopsy shows metastatic tumor deposits (carcinoma lung) (H & E 1000X)**



**Figure 6. Bone marrow biopsy shows metastatic tumor deposits (carcinoma prostate) (H & E 1000X)**

Metastatic tumors in bone marrow may influence the tumor stage, response to treatment, and predicts the survival of patient; hence, it is important to diagnose such cases at the earliest (Vardiman, 2005). Infiltration of the bone marrow may be suspected on the basis of: (i) Bone pain; (ii) pathological fractures, lytic lesions or sclerotic lesions demonstrated radiologically; (iii) unexplained “hot spots” on isotopic bone scans; (iv) hypercalcemia or elevated serum ALP levels; and (v) unexplained cytopenias or a leukoerythroblastic picture on routine blood and peripheral smear examination (Bain, 2001). However, bone marrow examination is confirmatory. While cytologic preparation of bone marrow obtained by aspiration allows excellent visualization of cell morphology, the bone marrow biopsy allows optimal evaluation of cellularity, fibrosis, or infiltrative disease (Ozkalemkas, 2005). The dramatic increase in modern immunological and molecular techniques which have been added to the diagnostic repertoire of clinical haematology has largely bypassed the BM trephine. However, bone marrow aspiration and biopsy is the most sensitive, easiest, cheapest, for the diagnosis of clinically suspected bone marrow involvement (Bain, 2001).

### Conclusion

Bone marrow aspiration and trephine biopsy are an effective method for evaluating solid tumors metastatic to bone marrow. A clue to the primary site can also be suggested if the primary is unknown and metastatic lesions are detected in the bone marrow. Bilateral trephine biopsy is most sensitive and it is considered the gold standard when performed simultaneously with bone marrow aspiration in a patient with any malignancy potentially infiltrating the bone marrow.

**REFERENCES**

- Bain, B.J., Clark, D.M., Wilkins, B.S., Lampert, I.A. Metastatic tumors. In: Bain BJ, Clark DM, Wilkins BS, editors. Bone Marrow Pathology. 3rd ed. England, Malden, MA: Blackwell Science, Bon Oxford; 2001. p. 430-61.
- Ozkalemkas, F., Ali, R., Ozkocaman, V., Ozeelik, T., Ozan, U., Ozturk, H., et al. 2005. The bone marrow aspirate and biopsy in the diagnosis of unsuspected nonhematologic malignancy: A clinical study of 19 cases. BMC Cancer., 5:144.
- Vardiman, J.W., Brunning, R.D., Arber, D., Le Beau MM. Introduction and overview of the classification of myeloid neoplasms. In: Swerdlow SH, Campo E, Harris NL, Jaffe ES, Pileri SA, Stein H, et al., editors. WHO Classification of Tumours of Haematopoietic and Lymphoid Tissues. 4th ed. Lyon, France: IARC Press; 2008. p. 19-20.

\*\*\*\*\*