



RESEARCH ARTICLE

CLINICAL AND RADIOGRAPHIC EVALUATION FOR LOCAL DRUG DELIVERY OF CHLORHEXIDINE CHIP IN CHRONIC PERIODONTITIS

1,*Dr. Muzafar Ahmad Bhat, 2Mirza Aumir Beg and 3Shafia Nisar kakroo

¹Registrar Department of Periodontics Govt Dental College and Hospital Srinagar

²senior Lecturer, Sudha Rastogi college of Dental Sciences and Research Faridabad

³lecturer Dept. of Dermatology, Hamdard Institute of Medical Sciences, New Delhi

ARTICLE INFO

Article History:

Received 15th October, 2017

Received in revised form

14th November, 2017

Accepted 08th December, 2017

Published online 30th January, 2018

Key Words:

Chlorhexidine,
Local Drug Delivery,
Periodontitis.

*Corresponding author:

Copyright©2018, Muzafar Ahmad et al. This is an open access article distributed under the Creative Commons Attribution License, which permits unrestricted use, distribution, and reproduction in any medium, provided the original work is properly cited.

Citation: Dr. Muzafar Ahmad, Dr. Shafia Nisar Kakroo and Dr. Mirza Aumir Beg. 2018. "Clinical and radiographic evaluation for local drug delivery of chlorhexidine chip in chronic periodontitis", *International Journal of Current Research*, 10, (01), 76812-76815.

ABSTRACT

Aims: The aim of the present study was to evaluate the efficacy of a controlled release biodegradable chlorhexidine chip when used as an adjunct to scaling and root planing in the treatment of periodontitis
Materials and Methods: In the present study, patients diagnosed with chronic periodontitis of age group, 25-60 were included. Local drug delivery of chlorhexidine chip (CHX) was administered after SRP (scaling and root planing). Test sites received CHX chip while control site received placebo. Plaque index, gingival index, probing pocket depth, Relative attachment level & gingival margin position were assessed at baseline, 1, 3, 6 and 9 months. Radiographs were taken at baseline 6 and 9 months. **Statistical Analysis:** Mean, standard deviation, Chi-square test, "t" test for equality of means and paired samples correlations were used. **Results:** There was significant difference (P value < 0.001) of PI and GI scores in CHX group. The gain of attachment and reduction in pocket depth was found statistically significant at 6 and 9 months in CHX group. No radiographic bone fill found at 6 months and 9 months in both groups. **Conclusions:** The results of the present study, favor the use of CHX chip as an adjunct to SRP in the treatment of chronic periodontitis.

INTRODUCTION

The standard treatment of periodontitis remains highly unspecific, consisting of scaling and root planing (SRP) with an objective of reducing total bacterial load. However, a small although relevant proportion of sites do not respond adequately to SRP (Walker, 1993). The persistence of periodontal pathogens is one of the factors proposed to explain the non-responsiveness (Haffajee et al., 1988; Haffajee, 1995; Renvert et al., 1990). Adjunctive administration of systemic antimicrobials is useful in treating recurrent periodontal pockets, aggressive periodontitis or patients with medical conditions (Finkelman, 1998). However, the doses necessary to achieve sufficient local concentrations of antimicrobials in the periodontal environment is associated with undesirable side-effects. Therefore, the local administration can be considered as an alternative to systemic drugs (Herrera, 2002). Goodson et al.(1979) first proposed the concept of controlled drug delivery in the treatment of periodontitis. Local antimicrobial therapy in periodontitis involves direct placement of an antimicrobial agents into subgingival sites. Various antimicrobials have been used by researchers as local drug delivery agents, which includes tetracycline, metronidazole, doxycycline, minocycline and chlorhexidine (Herrera et al., 2002; Goodson, 1979;

Soskolene , 1997; Drisko , 1998; Quirynen , 2002; Hanes , 2003; David, 2008) Chlorhexidine (CHX) mouth rinses of 0.1–0.2% concentrations have a long history of use in plaque control. CHX at low concentrations requires controlled release delivery to exert effective killing of subgingival microorganisms (Bonesvoll, 1978). A controlled local delivery system containing 2.5 mg of CHX incorporated into a biodegradable chip of hydrolyzed gelatin was introduced for subgingival antimicrobial treatment (Steinberg, 1990). Use of the CHX chip in conjunction with SRP has shown some effectiveness in reducing bleeding on probing, periodontal probing depth and clinical attachment loss. Hence, in the present study an attempt was made to evaluate and compare clinically and radiographically the efficacy of local drug delivery of CHX chip in the treatment of chronic periodontitis patients when used as an adjunct to SRP.

MATERIALS AND METHODS

Patients with chronic periodontitis, PPD \geq 5 mm with age group 25-60 were included in the study.

Inclusion criteria

- Patients with age group between 25-60 years.

- Patients with minimum of 10 natural teeth and periodontal disease characterized by presence of at least 4 teeth with probing pocket depth of ≥ 5 mm.
- Patients who have not undergone any type of regenerative periodontal therapy for last 6 months
- Patients without any antibiotic usage in last 6 months.

Exclusion criteria

- Aggressive periodontitis
- Any systemic disease.
- Allergic to chlorhexidine.
- Pregnant and lactating mothers.
- Patients with habitual smoking habit or use of tobacco in any other form.

After a detailed case history the following clinical parameters were assessed at baseline and subsequently 1, 3, 6 & 9 months.

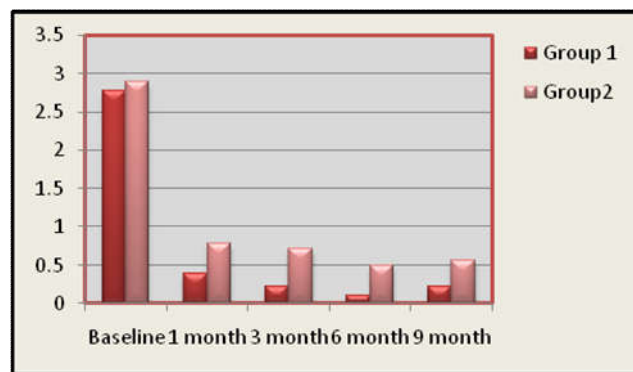
- Plaque Index (PI) (Silness and Loe, 1964)
- Gingival Index (GI) (Loe and Silness, 1963)
- Probing Pocket Depth (PPD)
- Relative Attachment Level (RAL)

University of North Carolina probe; UNC-15 was used to record clinical finding. SRP was done under local anesthesia by gracey curettes & ultrasonic scaler. To standardize the measurements, occlusal stents were fabricated with cold cure acrylic resin. CHX chip in test site (Periocol-CG, Eucare pharmaceuticals, Chennai, India) & placebo chip in control site were placed. CHX is incorporated in a biodegradable fish collagen vehicle in Periocol-CG, while placebo chips without chlorhexidine. Intraoral periapical radiographs with long cone technique were measured with the grid system in radiovisuography. A total of 14 patients and 20 bilateral sites i.e. 40 sites with pocket depth ≥ 5 mm were selected accordingly. Within one week supragingival scaling & polishing and thorough SRP for all the sites except the sites selected for the study was done. After one week, two sites were selected such that the minimum of two teeth were present between them. Along with SRP, test sites received CHX chip while control site received placebo chip. The test site and the control site were randomly assigned by the flip of a coin. To avoid dislodgement of chip, periodontal dressing was placed and patients were instructed to refrain from brushing and flossing those sites for 1 week. After one week the patients were recalled for pack removal and evaluation of any inflammatory response. Patients were reevaluated at 1, 3, 6 and 9 months. The chip placement was to be repeated where pocket depth remains more than 5 mm at recall visit every 3 months.

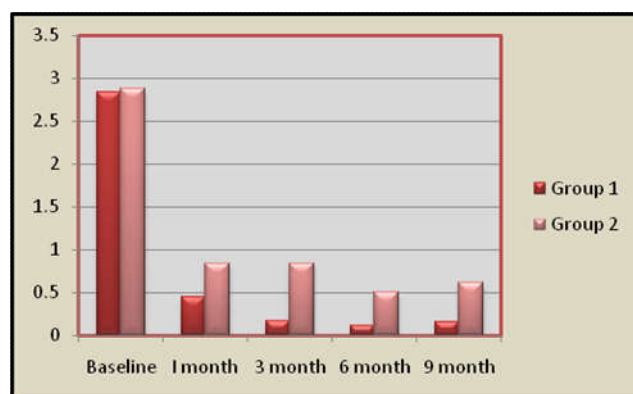
Statistical Analysis: Statistical software 'Graph Pad Prism version 5.2' was used for the analysis of the Friedman test, One way- ANOVA, Wilcoxon on match-pairs signed rank test and Unpaired t test. Statistical analysis could not be applied to the radiographic analysis as the difference was nonsignificant.

RESULTS

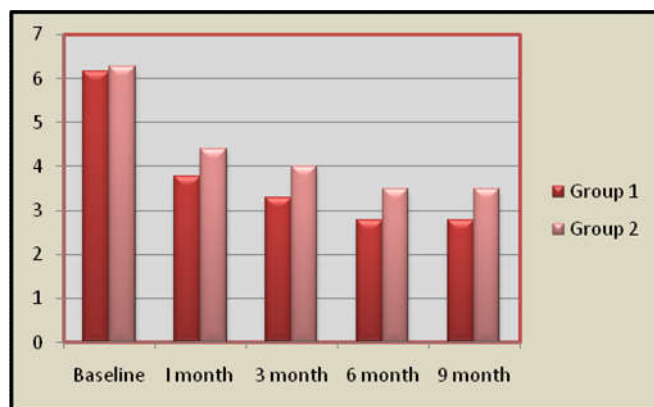
Eighteen bilateral sites i.e. 36 sites with pocket depth ≥ 5 mm from 12 patients out of 14 patients completed the study. The two drop-out were due to not report for the recall visits. Graph-1 & Graph 2 shows the mean reduction in PI and GI for patients receiving CHX and placebo chip adjunct to SRP.



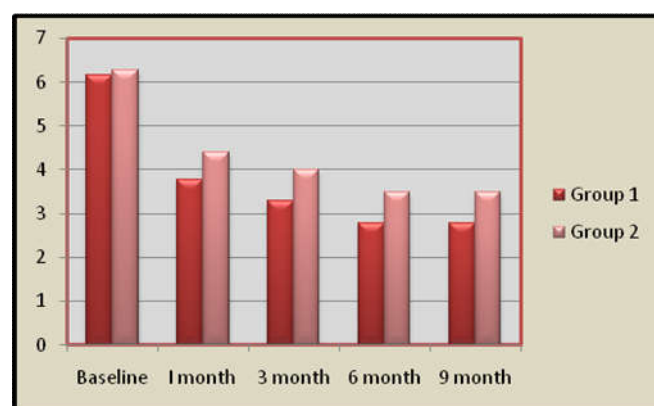
Graph 1. Plaque Index Scores in selected tooth sites between both the groups at Baseline, 1, 3, 6 and 9 months



Graph 2- Gingival Index Scores in selected tooth sites between both the Groups at Baseline, 1, 3, 6 and 9 months



Graph 3- Probing pocket depth in selected tooth sites between both the Groups at Baseline, 1, 3, 6 and 9 months



Graph 4. Clinical attachment level in selected tooth sites between both the Groups at Baseline, 1, 3, 6 and 9 months

A significant improvement was observed in CHX chip compared to placebo chip over the 9 months period ($P < 0.05$). Graph 3 shows the mean reduction in PD for patients receiving CHX chip. A significant improvement was observed in CHX and placebo chip adjunct to SRP over a period of 9 months ($P < 0.05$). At 9 month the change in probing depth was 3.5 ± 0.916 and 2.778 ± 1.003 for CHX and placebo chip respectively. Graph 4 shows RAL improved over the 9 months study period for the CHX and placebo chip adjunct to SRP at 6 and 9 months ($P < 0.05$). For radiographic analysis the vertical distance between the cemento-enamel junction (CEJ) and the most apical level of the marginal bone was measured on the intraoral periapical radiovisuography. The measurements were made with grid system in radiovisuography 0-150 mm. There was no difference in both groups at baseline, 6 months & 9 months follow up.

DISCUSSION

This randomized, split mouth clinical trial evaluated effectiveness of 2.5 mg bioabsorbable controlled release of CHX chip. The main purpose of split-mouth design was to remove all differences between subjects. A large multi-center study on CHX chip was conducted by Jeffcoat. (Jeffcoat, 2000) Claffey reported similar healing response when a single instrumentation as compared to 3 instrumentations, each separated by 3 months (Claffey, 1990) Drisko had earlier pointed out the efficacy of the local delivery system when used every 3 or 4 months (Drisko, 1998). However, Zafiropoulos *et al.* reported that no significance difference was observed between the application of 1 or 2 CHX chips. Three months was selected as treatment interval for CHX chip placement. This period correspond to typical recall interval for periodontal patients. CHX group showed significantly improved clinical parameters than placebo group at 1, 3, 6 & 9 months. These findings are in accordance with the results of Jeffcoat *et al.* (1998); Jeffcoat *et al.*, 2000. These results may be due to recolonization of the pocket by the bacteria occurs. Similar to other studies, clinical results showed improvements at 3 and 6 months periods. These assessments were in accordance with Soskolne *et al.* although a second CHX chip was inserted into each test pocket with $PD \geq 5$ mm, whereas only one chip was inserted at baseline in the present study.

There was a statistically significant greater percentage reduction of PI & GI scores at 6 months & 9 months in CHX group. These results were in accordance with Soskolne *et al.* (1997), Mizrak *et al.* (2006), & Jeffcoat *et al.* (1998), CHX group showed significant reduction in PPD at 3, 6 months & 9 months and gain in CAL at 6 & 9 months. These findings were in accordance with previous studies Soskolne *et al.* (1997), Jeffcoat *et al.* (1998), Jeffcoat *et al.* (2000), Mizrak *et al.* (2006) & Paolantonio *et al.* (2008). In the study by Grisi *et al.* (2002), the gingival recession obtained at CHX chip treatment was greater than obtained by the SRP alone. The greater gingival recession observed in sites that received CHX chip was related to greater reduction in gingival margin inflammation. Soskolne *et al.* (1997), & Jeffcoat *et al.* (1998), kept time limitation for SRP to 1 hour, whereas no limitation was introduced in present study. Time limitation affects the effectiveness of SRP. PPD and RAL in the present study in SRP group are in line with the report by Badersten (1981) & Adriaens (2004). The changes are comparable to those obtained by a skilled operator using local anesthesia and with unlimited time to perform the SRP. Radiovisuography along with grid

system was used in the present study. Radiovisuography is more accurate to estimate bone gain. It records bone gain less than millimeters as compared to conventional grids. There was no significant difference in both groups at 6 and 9 months radiographs. These results are in contrast to Jeffcoat *et al.* (2000). This might be due to the difference in methodology. However, our study is in accordance with Isidor *et al.* (1985), who reported no bone gain in sites with SRP alone as compared to the sites treated with regenerative surgical therapy. In the present study, no further CHX chip placement was done as the criteria for insertion of the chip was more than 5 mm of pocket depth and after 3 months none of the pocket depth was greater than 5 mm.

Conclusion

The result of the present study favors the use of chlorhexidine gluconate chip as an adjunct to SRP in treatment of chronic periodontitis. This study, states that CHX chip placement is safe. The clinical effects achieved with the CHX chip may reduce the need for further comprehensive and advanced surgical periodontal treatment. This would limit morbidity for the patients, the time of treatment and the cost of therapy.

REFERENCES

- Adriaens P., Adriaens L. 2004. Effects of nonsurgical periodontal therapy on hard and soft tissues. *Periodontol*, 36: 121-145.
- Badersten A., Nilveus R., Egelberg J. 1981. Effect of nonsurgical periodontal therapy. I. Moderately advanced periodontitis. *J Clin Periodontol.*, 8: 57-72.
- Bonesvoll P., Gjermo P. 1978. A comparison between chlorhexidine and some quaternary ammonium compounds with regard to retention, salivary concentration and plaque-inhibiting effect in the human mouth after mouth rinses. *Arch Oral Biol.*, 23: 289-294.
- Claffey N., Nylund K., Kiger R., Garret S., Egelberg J. 1990. Diagnostic predictability of scores of plaque, bleeding, suppuration and probing depth for probing attachment loss. 3.5 years of observation following initial periodontal therapy. *J Clin Periodontol*, 17: 108-114.
- David WP., Ryan MR. 2008. Locally delivered antimicrobials: Clinical Evidence and Relevance. *J Dent Hyg.*, 83(6): 10-14.
- Drisko CH. 1998. Comments: Local delivery of chemotherapeutic agents in periodontal therapy: Has its time arrived? *J Clin Periodontol.*, 25;
- Finkelman RD., Williams RC. 1998. Local delivery of chemotherapeutic agents in periodontal therapy: Has its time arrived? *J Clin Periodontol.*, 25: 943-946.
- Goodson JM., 1979. Haffajee A & Socransky SS. Periodontal therapy by local delivery of tetracycline. *J Clin Periodontol.*, 6: 83-92.
- Grisi DC., Salvador SL., Figueiredo LC., Souza SL., Novaes AB., Grisi MF. 2002. Effect of a controlled-release chlorhexidine chip on clinical and microbiological parameters of periodontal syndrome. *J Clin Periodontol.*, 29: 875-881.
- Haffajee AD., Dibart S., Kent RL. & Socransky SS. 1995. Clinical and microbiological changes associated with the use of 4 adjunctive systemically administered agents in the treatment of periodontal infections. *J Clin Periodontol.*, 22: 618-627.

- Haffajee AD., Socransky SS., Dzink JL., Taubman MA. & Ebersole JL. 1988. Clinical, microbiological and immunological features of subjects with refractory periodontal diseases. *J Clin Periodontol.*, 15: 390-398
- Hanes PJ. and James PP. 2003. Local anti-infective therapy: Pharmacological agents. A systemic review. *Ann Periodontol*, 8: 79-98.
- Herrera D., Sanz M., Jepsen S., Neeleman I., Roldan S. 2002. A Systematic review on the effect of systemic antimicrobials as an adjunct of scaling and root planing in periodontitis patients. *J Clin Periodontol.*, 29(Supp. 3): 136-159.
- Isidor F., Attstrom R., Karring T. 1985. Regeneration of alveolar bone following surgical and non-surgical periodontal treatment. *J Clin Periodontol*, 12: 687-696.
- Jeffcoat MK., Bray KS., Ciancio SG., Dentino AR., Fine DH., Gordon JM., Gunsolley JC., Killoy WJ., Lowenguth RA., Magnusson NI., Offenbacher S., Palcanis KG., Proskin HM., Finkelman RD., Flashner M. 1998. Adjunctive use of a subgingival controlled-release nchlorhexidine chip reduces probing depth and improves attachment level compared with scaling and root planing alone. *J Periodontol*, 1998; 69: 989-997.
- Jeffcoat MK., Palcanis KG., Weatherford TW., Reese M., Geurs NC., Flashner M. 2000. Use of a biodegradable chlorhexidine chip in the treatment of adult periodontitis: clinical and radiographic findings. *J Periodontol.*, 71: 256-262.
- Mizrak T., Guliz N., Guncu, Feriha C., Ansal BT., Aktar GS., Fikret I. 2006. Effect of a controlled-release chlorhexidine chip on clinical and microbiological parameters and prostaglandin E2 levels in gingival crevicular fluid. *J Periodontol*, 77: 437-443.
- Paolantonio M., Angelo MD., Grassi RF., Perinetti G., Piccolomini R., Pizzo G., Annunziata M., Archivio DD., Nardi G. 2008. Clinical and microbiologic effects of subgingival controlled-release delivery of chlorhexidine chip in the treatment of periodontitis: A multi center study. *J Periodontol*, 79: 271-282.
- Quirynen M., Teughels W., Marc DS. & Daniel VS. 2002. Topical antiseptics and antibiotics in the initial therapy of chronic adult periodontitis: microbiological aspects. *Periodontol*, 28: 72-90.
- Renvert SN., Wikstrom MB., Dahlen GG., Slots J., Egelberg J. 1990. On the inability of root debridement and periodontal surgery to eliminate *Actinobacillus actinomycetemcomitans* from periodontal pockets. *J Clin Periodontol.*, 17: 351-355.
- Research Science & Therapeutic Committee of American Academy of Periodontology (Position Paper). The role of Controlled Drug Delivery for Periodontics. *J Periodontol*, 2000; 71: 125-140.
- Soskolne WA. 1977. Subgingival delivery of therapeutic agents in the treatment of periodontal diseases. *Crit Rev Oral Biol Med.*, 8(2): 164-174.
- Soskolne WA., Heasman PA., Stabholz A., Smart Jr. G., Palmer M., Flashner M., Newman HN. 1997. Sustained local delivery of chlorhexidine in the treatment of periodontitis: A multi-center study. *J Periodontol.*, 68: 32-38.
- Steinberg D., Friedman M., Soskolne A., Sela MN. 1990. A new degradable controlled release device for treatment of periodontal disease: In vitro release study. *J Periodontol.*, 61: 393-398.
- Walker CB., Gordon JM., Magnusson I., Clark WB. 1993. A role for antibiotics in the treatment of refractory periodontitis. *J Periodontol*, 64: 772-781.
- Zaffirpolous GG., Kalyakis G., Cianco S., Ho AA. 1997. A chlorhexidine sustained release dosage system for the treatment of periodontal disease. *J Periodontol*, 68: 419.
