



ISSN: 0975-833X

Available online at <http://www.journalcra.com>

International Journal of Current Research  
Vol. 11, Issue, 07, pp.5779-5781, July, 2019

DOI: <https://doi.org/10.24941/ijcr.35909.07.2019>

INTERNATIONAL JOURNAL  
OF CURRENT RESEARCH

## CASE REPORT

### PHANTOM TUMOR OF THE LUNG: A CASE OF LOCALIZED INTERLOBAR EFFUSION IN CONGESTIVE HEART FAILURE

\*Dr. Shinu A., Dr. Anil Saxena, Dr. Babulal Bansiwala and Dr. Abdul Qayyoom Ansari

Department of Pulmonary Medicine, GMC Kota, Rajasthan, India

#### ARTICLE INFO

##### Article History:

Received 17<sup>th</sup> April, 2019  
Received in revised form  
08<sup>th</sup> May, 2019  
Accepted 12<sup>th</sup> June, 2019  
Published online 31<sup>st</sup> July, 2019

##### Key Words:

Phantom tumour  
Congestive heart failure  
Diuretics,  
Pleural effusion .

\*Corresponding author: Dr. Shinu, A.

Copyright © 2019, Shinu et al. This is an open access article distributed under the Creative Commons Attribution License, which permits unrestricted use, distribution, and reproduction in any medium, provided the original work is properly cited.

Citation: Dr. Shinu A., Dr. Anil Saxena, Dr. Babulal Bansiwala and Dr. Abdul Qayyoom Ansari, 2019. "Phantom tumor of the lung: A case of localized interlobar effusion in congestive heart failure", *International Journal of Current Research*, 11, (07), 5779-5781

#### ABSTRACT

**Background:** Phantom tumour or Vanishing tumour stands for a localized transudative interlobar collection of pleural fluid in congestive heart failure. It is named so because of the resemblance to a tumour on the CXR and its tendency to disappear following therapy for cardiac failure. It was first reported by Stewart in 1928 as "interlobar hydrothorax". **Case report:** A 80 year old man presented Shortness of breath and swelling over legs generalized tiredness and dry cough since five days. He had no history of Tuberculosis nor any other co-morbidities On Examination he had clubbing of fingers, B/l Pitting Pedal Edema along with raised JVP. Chest was barrel in shape. Bilateral fine inspiratory crepitations were present in Lower Lung Fields. No Cardiac Murmurs were audible. Chest x ray PA View showed sharply demarcated oval homogenous dense shadow about 3x4 cm size in the Right Middle Lobe. USG Thorax was done and showed fluid in the interlobar fissure. Echocardiography was done and showed Left Ventricular Hypertrophy, Global Hypokinesia of Left Ventricle with LVEF of 45%, Mild Tricuspid Regurgitation, jerky septum in motion. Parenteral diuretic therapy was started along with fluid restriction. After five days of therapy repeat chest X rays revealed significant resolution of homogenous opacity with only thin strip of opacity of 0.5cm was remaining. **Conclusion:** This case confirms efficacy of the conservative medical treatment (loop diuretics and fluid restriction) for the localized interlobar effusion in congestive heart failure. Phantom lung tumor should be considered and excluded in any patient presenting with clinical features of congestive heart failure with an apparent lung mass on a CXR. Finally, it is necessary to highlight the importance of recognizing this condition in order to avoid unnecessary, expensive, and possibly harmful diagnostic and treatment errors.

#### INTRODUCTION

Phantom tumour or Vanishing tumour stands for a localized transudative interlobar collection of pleural fluid in congestive heart failure. It is named so because of the resemblance to a tumour on the CXR and its tendency to disappear following therapy for cardiac failure. It was first reported by Stewart in 1928 as "interlobar hydrothorax" (Mislav Lozo et al., 2014; Argan, 2017). A bilateral transudative effusion is usual clinical finding in a patient of congestive heart failure

#### CASE REPORT

A 80 year old man presented Shortness of breath and swelling over legs generalized tiredness and dry cough since five days. He had no history of Tuberculosis nor any other comorbidities. There were similar episodes in the past for which he was admitted in hospital and was given medications. He had a habit of smoking 1 bundle of beedi per day since past 35 years (35 Packyears) which he stopped 2 years ago.

He used to take alcohol occasionally and now stopped since past two years. On Examination he had clubbing of fingers, B/l Pitting Pedal Edema along with raised JVP. His heart rates were 99/mt Respiratory rate of 22/mt arterial blood pressure was 108/70 mmhg in Right upper Limb in sitting posture. Oxygen saturation was 96 % at room air. Chest was barrel in shape. Bilateral fine inspiratory crepitations were present in Lower Lung Fields. No Cardiac Murmurs were audible. Baseline Investigations showed a normal Blood counts, Renal function tests and Liver Function Tests. ECG showed normal sinus rhythm with mild right axis deviation. Chest x ray PA View showed sharply demarcated oval homogenous dense shadow about 3x4 cm size in the Right Middle Lobe. USG Thorax was done and showed fluid in the interlobar fissure. Echocardiography was done and showed Left Ventricular Hypertrophy, Global Hypokinesia of Left Ventricle with LVEF of 45 %, Mild Tricuspid Regurgitation, jerky septum in motion. Parenteral diuretic therapy was started along with fluid restriction. After five days of therapy repeat chest X rays revealed significant resolution of homogenous opacity with only thin strip of opacity of 0.5cm was remaining.

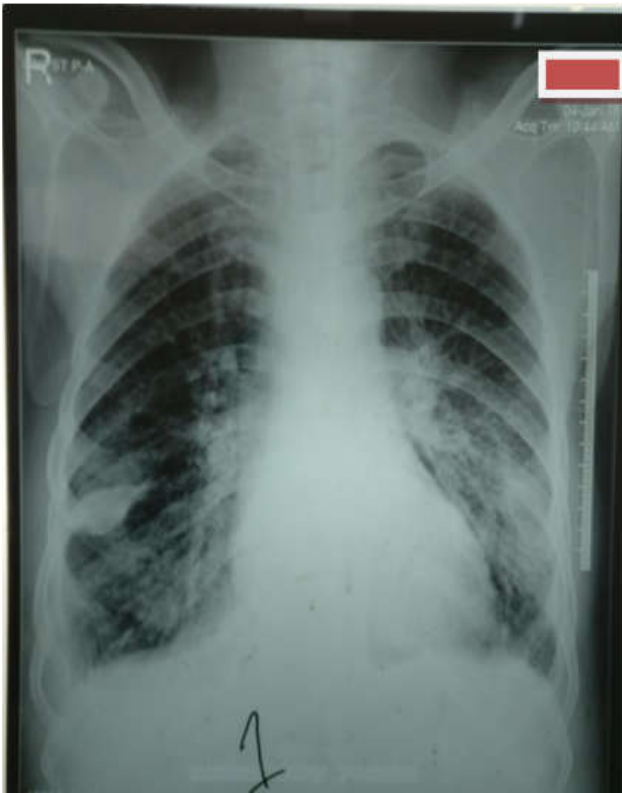

Fig. 1. CXR of the patient at the time of admission

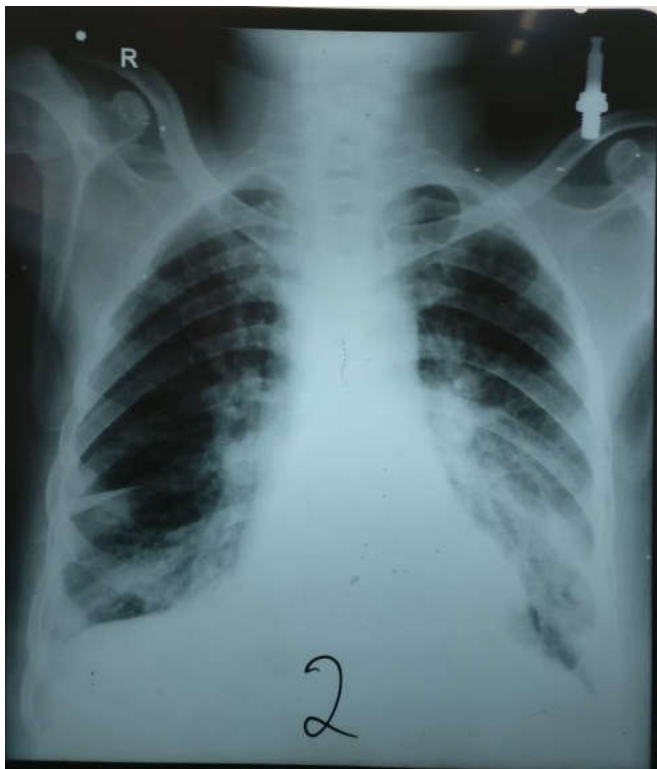


Fig. 2. Control CXR after five days of diuretic therapy

## DISCUSSION

Vanishing tumor (Phantom Tumor) of the lung is an appropriate assignment for a localized transudative interlobar pleural fluid collection in congestive heart failure. The prerequisites for the growth of a vanishing tumor of the lung or (1) congestive heart failure and, probably, (2) obliterative pleuritis (Argan, 2017; Melo *et al.*, 2012; Bedford and Lovibond, 1941).

MEASUREMENTS	NORMAL VALUES	MEASUREMENTS	NORMAL VALUES
Aorta	27 mm (21-22 mm/m <sup>2</sup> )	LA es	50 mm (21-22 mm/m <sup>2</sup> )
LV es	35 mm (16-19mm/m <sup>2</sup> )	LV ed	40 mm (19-32 mm/m <sup>2</sup> )
IVSed	12 mm (06-10mm/m <sup>2</sup> )	PW(Lved)	12 mm (07-11mm/m <sup>2</sup> )
<b>IVS MOTION</b>		<b>NORMAL / Flat / Paradoxical</b>	
<b>CHAMBERS:-</b>			
LV	Normal / Enlarged / Clear / Thrombus / <b>HYPERTROPHY</b>		
	Contraction Normal / <b>REDUCED</b>		
LA	<b>NORMAL</b> / Enlarged / Clear / Thrombus		
RA	<b>NORMAL</b> / Enlarged / Clear / Thrombus		
RV	<b>NORMAL</b> / Enlarged / Clear / Thrombus		
PERICARDIUM	<b>NORMAL</b> / Thickened / Calcification Effusion.		
<b>REMARKS:-</b>			
<ul style="list-style-type: none"> <li>* JERKY SEPTUM MOTION</li> <li>* GLOBAL HYPOKINESIA OF LEFT VENTRICLE</li> <li>* MILD TRICUSPID REGURGITATION, RAP+41mmHg</li> <li>* LVEF= 45-50%</li> <li>* NO AS/COA</li> <li>* No LV/LA CLOT</li> <li>* NO PERICARDIAL EFFUSION</li> </ul>			
<b>FINAL IMPRESSION</b>			
<ul style="list-style-type: none"> <li>* JERKY SEPTUM MOTION</li> <li>* GLOBAL HYPOKINESIA OF LV</li> <li>* MILD TR, RAP+41mmHg</li> <li>* LVEF= 45-50 %</li> </ul>			

Fig. 3. Report of 2 D echo cardiogram of the patient

Obliterative pleuritis prevents accumulation of free fluid in the pleural space so that the interlobar collection is visible. Phantom tumors arise when the transudation from the pulmonary vascular space exceeds resorptive ability of the pleural lymphatics (Oliveira *et al.*, 2012). The appearance is most often that of a well defined homogeneous density, usually in the right lung, occupying commonly the transverse, but occasionally the oblique interlobar fissures. Aspiration for diagnostic purposes is contraindicated because of the possibility of inducing hemorrhage and/or pneumothorax and hence aborted. The differential diagnosis of loculated pleural effusions within the fissure includes the following: transudates due to the left ventricular failure or renal failure, exudates (parapneumonic pleural effusions, localized malignant pleural effusions, and benign asbestos-related pleural effusions), and hemothorax, chylothorax, and fibrous tumors originating from the visceral pleura of the interlobar fissure (Mislav Lozo *et al.*, 2014; Haus *et al.*, 2003). Response to diuretics is almost confirmatory. The case stated here was an acute exacerbation of congestive heart failure. Characteristic radiographic phantom lung tumor finding was identified: a well defined pulmonary mass like lesion with smooth margins. Rapid resolution of the lesion after management of the congestive heart failure using diuretics and fluid restriction confirms the diagnosis.

## Conclusion

This case confirms efficacy of the conservative medical treatment (loop diuretics and fluid restriction) for the localized interlobar effusion in congestive heart failure. Phantom lung tumor should be considered and excluded in any patient presenting with clinical features of congestive heart failure with an apparent lung mass on a CXR. Finally, it is necessary to highlight the importance of recognizing this condition in order to avoid unnecessary, expensive, and possibly harmful diagnostic and treatment errors.

**REFERENCES**

- Ardic I, Yarlioglu M, Celik A, Kaya MG. Vanishing or Phantom Tumor of the Lung. Stainback RF, ed. *Texas Heart Institute Journal*, 2010;37(6):730-731.
- Argan, O. 2017. Tumor Appearance of the Lung in Heart Failure Patients. *J Tumor Res.*, 3:124
- Bedford DE. and Lovibond JL. 1941. Hydrothorax in heart failure. *British Heart Journal*, 3(2):93-111.
- Gilhofer, T.S., Huber, L.C. 2011. Phantom tumour of the lung. *Cardiovasc Med.*, 14:327-8.
- Haus B. M., P. Stark, S. L. Shofer, and W. G. Kuschner, 2003. "Massive pulmonary pseudotumor," *Chest*, vol. 124, no. 2, pp. 758-760.
- Kumar, A., Gupta, A.K., Aditya Kumar Gautam, Somnath Bhattacharya and Mohd Haroon Khan, 2014. "Vanishing Tumour A Case Report" *Indian J L Sci.*, 4 (1) 101-104.
- Melo BS, Serra AC, Belo MT, et al. 2012. Phantom tumor of the lung. *Rev Assoc Med Bras.*, 58:517-18
- Millard, 1971. "Vanishing of phantom tumor of the lung; localized interlobar effusion in congestive heart failure," *Chest*, vol. 59, no. 6, pp. 675-677.
- Mislav Lozo, Emilija Lozo Vukovac, Zeljko Ivancevic, and Ivan Pletikotic, "Phantom Tumor of the Lung: Localized Interlobar Effusion in Congestive Heart Failure," *Case Reports in Cardiology*, vol. 2014, Article ID 207294, 3 pages, 2014
- Oliveira E., P. Manuel, J. Alexandre, and F. Girão, "Phantom tumour of the lung," *The Lancet*, vol. 380, no. 9858, p. 2028, 2012.
- Rabinowitz, J. G. and Kongtawng, T. 1978. "Loculated interlobar air-fluid collection in congestive heart failure," *Chest*, vol. 74, no. 6, pp. 681-683.
- Stewart HJ. 1928. Pleural effusion localized in an interlobar space; report of case of heart failure together with autopsy. *Am Heart J.*, 4:227-35
- Swathi P, Chandhar S, Bhaskar E. and Rajarajan R. 2014. Pleural effusion masquerading as pseudotumor. *Lung India : Official Organ of Indian Chest Society*, 31(1):86-87. doi:10.4103/0970-2113.126000.

\*\*\*\*\*