



ISSN: 0975-833X

Available online at <http://www.journalcra.com>

International Journal of Current Research  
Vol. 12, Issue, 01, pp.9886-9888, January, 2020

DOI: <https://doi.org/10.24941/ijcr.37718.01.2020>

INTERNATIONAL JOURNAL  
OF CURRENT RESEARCH

## RESEARCH ARTICLE

### BRENNER TUMOR OF OVARY IN MULTIPAROUS WOMAN – A RARE CASE REPORT

\*Dr. Indu Yadav, Dr. Charnjeet alhuwalia, Dr. Manju Yadav and Dr. A.K Yadav

Department of Pathology, V.M.M.C & S.J.H, New Delhi, India

#### ARTICLE INFO

##### Article History:

Received 04<sup>th</sup> October, 2019

Received in revised form

10<sup>th</sup> November, 2019

Accepted 29<sup>th</sup> December, 2019

Published online 30<sup>th</sup> January, 2020

#### ABSTRACT

Brenner tumor is a rare surface epithelial group of ovarian neoplasm. It most commonly has benign presentation. They are divided into benign, borderline and malignant neoplasms. The majority of them are asymptomatic in nature and are found incidentally. On imaging, these have nonspecific findings. Microscopically demonstrate nests of benign transitional epithelium against background of numerous spindle shaped cells that are arranged in the form of diffuse sheets and fascicles. There is no consistent tumor marker and express immunohistochemical marker like CK7, uroplakin III and p63. Here, we present a rare case of Brenner tumor of ovary.

#### Key Words:

Brenner,  
Ovarian Tumor.

Copyright © 2019, Indu Yadav et al. This is an open access article distributed under the Creative Commons Attribution License, which permits unrestricted use, distribution, and reproduction in any medium, provided the original work is properly cited.

Citation: Dr. Indu Yadav, Dr. Charnjeet alhuwalia, Dr. Manju Yadav and Dr. A.K Yadav. 2019. "Brenner tumor of ovary in multiparous woman – a rare case report". *International Journal of Current Research*. 12. (01). 9886-9888.

## INTRODUCTION

Ovarian neoplasm is a group of neoplasm with different origin and histological types. It is the second most common neoplasm of the female reproductive system and one of the leading causes of death from gynecological cancer in the world (Tortolero-Luna, 1994). Ovarian cancer also has the worst prognosis and the highest mortality rate as it remains undetected until it grows in size (Coburn et al., 2017). Transitional cell tumors of the ovary, the first time described by Brenner in 1907, are rare neoplasms and account for about 2% of all ovarian tumors. They are common forms of neoplasia in women. The average age at presentation is 50 years with 71% of the patients being more than 40 years (Hemalatha, 2005). According to WHO, based on the histopathological pattern, they are classified as benign, borderline or malignant Brenner tumors, and transitional cell carcinomas. The Brenner tumors vary greatly in size from the usual small, solid, firm grayish nodules to the bigger ones which have cystic components as a result of cystic degeneration and necrosis. They are mostly benign and 95% of cases are unilateral. Malignant cases are extremely rare (roughly about 2% of all cases), and less than 5% are proliferating or borderline (Vranes et al., 2005). The radiological techniques like ultrasound and computed tomography are less sensitive methods for the diagnosis because of its nonspecific appearance hence the histopathological diagnosis is essential for subtyping confirmation.

## CASE REPORT

A 66 year old multiparous woman attended the gynecology outpatient department with a history of postmenopausal bleeding, pain in abdomen for three months and fever for one month. Ultrasonography (USG) showed solid cystic ovarian mass with endometrium thickness of 10 mm. Magnetic resonance imaging pelvis was suggestive of well defined round, predominantly solid lesion with few cystic areas measuring 3.9 cm x 3.9 cm x 4.6 cm in right adnexa. Right ovary was not seen separated from it. Solid portion was hyperintense on T1 & T2W sequence and showed intense homogenous post contrast enhancement. Ca 125 was done, and it was 19.0 µ/ml. The patient was prepared for staging laparotomy. Right oophorectomy was done. Specimen was sent for scrape cytology. Grossly the ovary measured 4.5 x 3.5 x 3 cm. The attached fallopian tube measured 4 cm in length. External surface was congested and lobulated. On cut solid grey white areas with a few cystic spaces were identified from which mucinous fluid was drained. Scrape cytology smears were highly cellular and show epithelial cells arranged in clusters, sheets and papillary structures along with few clusters of spindle shaped cells. The epithelial cells show mild to moderate pleomorphism and some cells showed intracellular mucin. Possibility of a surface epithelial tumor in which borderline and malignancy could not be ruled out and to be further confirmation on paraffin section was given. Total abdominal hysterectomy with bilateral salpingectomy with left sided oophorectomy was performed with proper hemostasis.

\*Corresponding author: Dr. Indu Yadav,  
Department of Pathology, V.M.M.C & S.J.H, New Delhi, India.

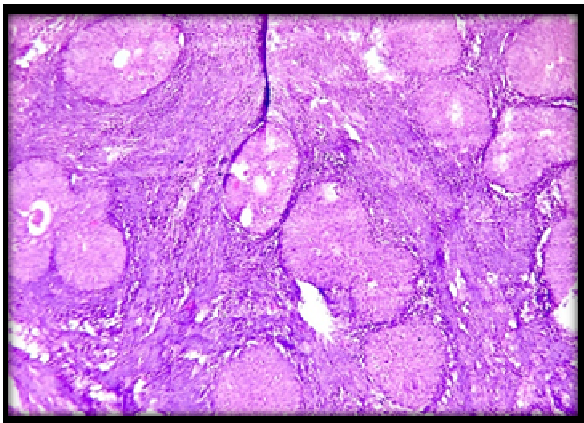
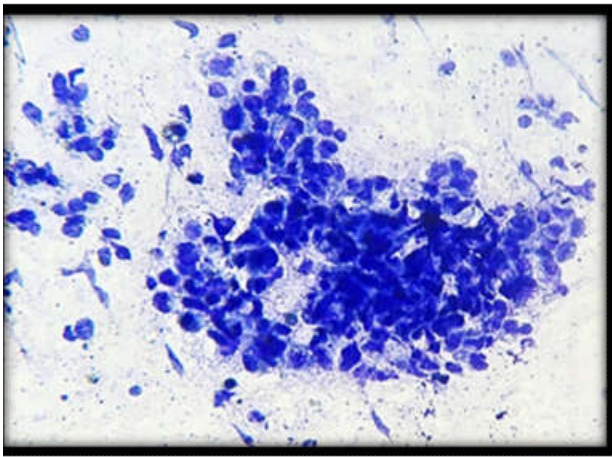


Figure 1. Scrape cytology

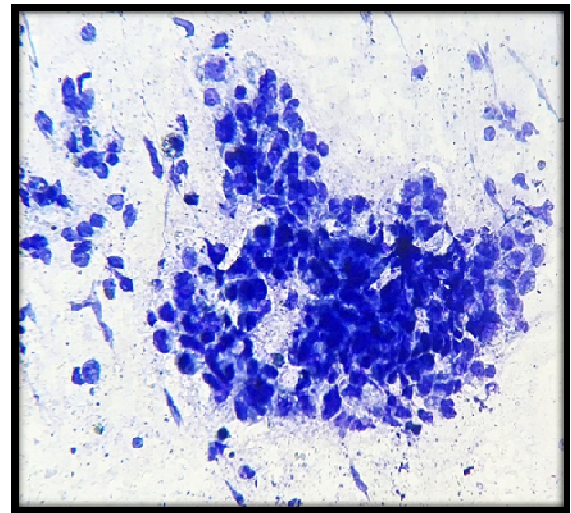
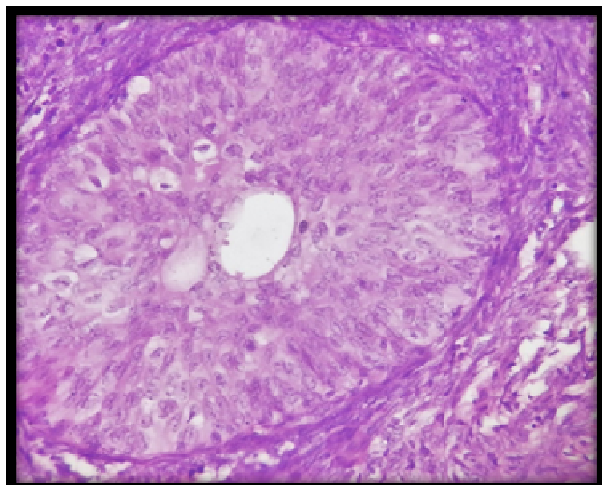
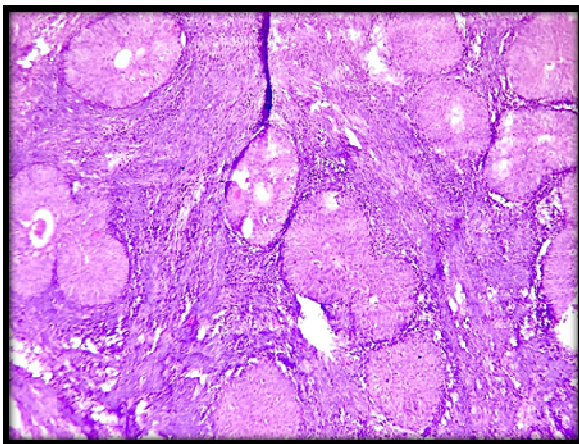


Figure 2- H &E (40X) Transitional tumor nest against a background of spindle cell

On histopathology examination sections of ovary showed presence of a tissue which displayed nest of benign transitional epithelium against background of numerous spindle shaped cells that are arranged in the form of diffuse sheets and fascicles. Some of the larger nest were showing cystic change with presence of proteinaceous fluid in the tumor. Attached fallopian tube and rest of the specimen sent for in staging laparotomy histopathological examination were within normal limits. No malignant cell was seen on cytology of peritoneal fluid. The postoperative period was uneventful, and the patient was discharged with the advice of regular follow-up.

## DISCUSSION

Brenner tumors are fibroepithelial ovarian neoplasms consisting of both epithelial and stromal elements. The majority are benign, but few can be malignant too. They were earlier known as transitional cell tumors because of their histological similarity to the urothelium. They arise from walthard cell nest, metaplastic urinary epithelium, arising either from mesonephric remnants or metaplasia of germinal epithelium. Brenner tumor of the ovary is a solid ovarian tumor that is generally asymptomatic and are frequently found incidentally on pelvic examination. Brenner tumors very rarely can occur in other locations, including the testis (Caccamo, 1991). Although they are predominantly solid on imaging and pathologic examination, association with serous and mucinous cystadenomas is up to 30% (Sternberg, 1963). 90% are unilateral same as seen in our case. On gross pathological examination, they are well circumscribed, firm and on cut section solid and grey white to yellow in colour. Size also correlates with histologic grade: most benign tumors are smaller than 5 cm, and those with borderline or malignant histologic findings are larger than 5 cm at diagnosis. 7pdf second Brenner tumor in our case was benign. Brenner tumors are characteristically cystic and multilocular with cauliflower-like papillomatous masses. Malignant Brenner tumor may be solid or cystic with mural nodules; usually without any distinctive features (Clemet, 2010). Microscopically, they are made up of the epithelial nests of transitional cells rest surrounded by abundant dense fibrous stroma. The fibrous component is less prominent with greater degree of epithelial complexity in borderline or malignant counterpart in comparison to benign lesions.

Complex cystic tumors contain varying amounts of stroma and are more commonly found with borderline or malignant histologic findings, often in the form of fibrovascular papillary projections with a branching pattern that project into a cystic lumen (Takahama, 2004). Increased mitotic activity and focal necrosis is common. Mucinous metaplasia is observed sometimes. Imaging differential diagnosis of benign Brenner tumors are fibroma, fibrothecoma, and pedunculated leiomyoma (Athey, 1987). Magnetic resonance imaging may show a T1- and T2-weighted hypointense solid component containing fibrous tissue, mimicking a fibroma. The tumors have a large fibroma or the coma component, which may be responsible for the hormonal effect (usually estrogenic) seen in some patients with Brenner tumor. Brenner tumors of the ovary usually have no hormonal activities, although there are reports of steroid hormone-producing Brenner tumors (Joh, 1995). Surgical excision is the mainstay treatment of Brenner tumor. In younger women less surgery with aim to preserve fertility and in postmenopausal women both ovaries, fallopian tube and uterus to be removed additional treatment depends on age of the patient and stage of the cancer (Nasioudis, 2016)

### Conclusion

The incidence of Brenner tumors is rare. Due to late presentation, ineffective screening and nonspecific features on radiological investigations, histopathological examination remains the gold standard for diagnosis of this entity.

**Funding:** No funding sources

**Conflict of interest:** None declared

**Ethical approval:** Not required

### REFERENCES

- Athey PA., Siegel MF. 1987. Sonographic features of Brenner tumor of the ovary. *J Ultrasound Med.*, 6(7):367-72
- Caccamo D., Socias M., Truchet C. 1991. Malignant Brenner tumor of the testis and epididymis. *Arch Pathol Lab Med.*, 115(5):524-7
- Clemet PB., Young RH. 2010. Ovarian surface epithelial – Stromal tumors. In: Mills SE, editor. *Sternberg's Diagnostic Surgical Pathology*. 5<sup>th</sup> ed. Philadelphia: Lippincott Williams and Wilkins, A Wolters Kluwer Business. p. 2278-308
- Coburn S., Bray F., Sherman M., Trabert B. 2017. International patterns and trends in ovarian cancer incidence, overall and by histologic subtype. *Int J Cancer.*, 140(11):2451–2460. doi:10.1002/ijc.30676 (PMC free article) (PubMed)
- Hautmann S., Fedrich K., Redline R., Avril S. 2017. Ovarian borderlin tumors in the 2014 WHO classification : evolving concepts and diagnostic criteria. *Virchow Arch.*, 470(2):125-142.
- Hemalatha AL., Konanahalli P. 2005. Bilateral malignant Brenner tumor of ovary. *J Obstet Gynecol India.*, 55:81-2.
- Joh K., Aizawa S., Ohkawa K., Dohzono H., Aida S., Ohgoshi E. 1995. Case report of a malignant Brenner tumor with hyperestrogenism. *Pathol Int.*, 45:75-84.
- Nasioudis D., Sisti G., Holcomb K., Kanninen T., Witkin S. 2016. Malignant brenner tumors of the ovary; a population based analysis. *Gynecol Oncol.*, 142:44-49.
- Sternberg WH., 1963. Non-functioning ovarian neoplasms. In: Grady HG, Smith DE, editors. *The Ovary*. Baltimore: Williams and Wilkins; p. 209-15.
- Takahama J., Ascher SM., Hirohashi S., Takewa M., Ito T., Iwasaki S. *et al.*, 2004. Borderline Brenner tumor of the ovary: MRI findings. *Abdom Imaging.*, 29:528-30
- Tortolero-Luna G<sup>1</sup>., Mitchell MF., Rhodes-Morris HE. 1994. Epidemiology and screening of ovarian cancer. *Obstet Gynecol Clin North Am.*, Mar;21(1):1-23.
- Vranes HS., Klaric P., Benkovik LB., Pirkic A. 2005. Brenner tumor of the ovary. *Acta Clin Croat.*, 44:271-3.

\*\*\*\*\*