



ISSN: 0975-833X

Available online at <http://www.ijournalcra.com>

International Journal of Current Research

Vol. 14, Issue, 07, pp.21950-21953, July, 2022

DOI: <https://doi.org/10.24941/ijcr.43769.07.2022>

INTERNATIONAL JOURNAL
OF CURRENT RESEARCH

CASE REPORT

LASER ASSISTED EXCISION OF PYOGENIC GRANULOMA-A REPORT OF TWO CASES

^{1,*}Dr. Sohini Banerjee and ²Dr. Debkamal Kar

¹Assistant Professor, Dept. of Periodontics, Dr. R. Ahmed Dental College & Hospital, India

²Dental Surgeon and Oral and Maxillo-facial Pathologist, India

ARTICLE INFO

Article History:

Received 09th April, 2022

Received in revised form

15th May, 2022

Accepted 14th June, 2022

Published online 30th July, 2022

ABSTRACT

Pyogenic granuloma is a reactive hyperplasia/non-specific conditional gingival over growth. The diagnosis should be made with clinical and histopathological findings. The excision by laser is a successful treatment option for this kind of lesion with no recurrence. This article would highlight the use of diode laser in excision of localized gingival overgrowth turned out to be pyogenic granuloma with no bleeding, no post-operative complications with no recurrence.

Key words:

Pyogenic Granuloma, Gingival overgrowth, Laser.

*Corresponding Author: Dr. Sohini Banerjee

Copyright©2022, Sohini Banerjee and Debkamal Kar. This is an open access article distributed under the Creative Commons Attribution License, which permits unrestricted use, distribution, and reproduction in any medium, provided the original work is properly cited.

Citation: Dr. Sohini Banerjee and Dr. Debkamal Kar. 2022. "Laser assisted excision of pyogenic granuloma-a report of two cases.". International Journal of Current Research, 14, (07), 21950-21953.

INTRODUCTION

Pyogenic granuloma is a non-neoplastic, exuberant, reactive lesion seen in response to local irritation or trauma caused by dental calculus, bacterial plaque, caries and restorations, with a strong predilection for the gingiva⁽¹⁻³⁾. It is among the frequently encountered oral lesions, occurring at a challenging oral site, the gingiva. The most frequent intra-oral site for pyogenic granuloma is marginal gingiva, but lesions also occur on palate, buccal mucosa, tongue, and lips. Clinically, an oral PG appears as a tumor-like, painless, exophytic mass with erythematous papules that tend to bleed easily, and sizes ranging from a few millimeters to a few centimeters have been reported⁽³⁻⁵⁾. The colour of the lesion may vary according to the level of vascularity. Pyogenic granuloma can develop as a result of chronic, local, low-grade trauma or irritation and due to hormonal factors. Conventional surgical excision can be used but some complications like intra-operative bleeding and postoperative infection may occur, which can affect the dynamics of healing process. Local irritants and other traumatic factors must be diminished in order to avoid recurrence⁽⁴⁻⁶⁾. Many treatment modalities are now-a-days available for excision of oral pyogenic granuloma. Laser technology is being widely used in dentistry. Their ability to perform deep and precise incisions, better haemostasis and less invasive procedures with less discomfort to patients have made

them a preferred treatment option for several soft tissue lesions. The advantages of laser surgery compared with conventional surgical methods includes the maintenance of sterile conditions, good estimation of cutting depth, reduction in the number of operative instruments, often no need for suturing or bandages, pain reduction both intra- and postoperatively, promotion of wound healing, less scars, staff and time⁽⁶⁾. This article would highlight the application of diode laser in excision of gingival overgrowth.

CASE REPORT 1:

A male patient aged 25 years reported with chief complaint of gum swelling in lower gum region for last three months. The swelling slowly increased in size. The medical history was found to be non-contributory in nature. On clinical examination, a solitary, soft, sessile, reddish-pink over-growth was found on the buccal aspect of 41,31 region involving the marginal and interdental gingival (Fig.1). The growth was non-tender on palpation and bleeds on provocation. The probing pocket depth was found to be within 3-5mm on the affected area. The oral hygiene was found to be poor with minimal or no bone loss on the affected area. The patient had undergone scaling and root planning followed by surgical excision of gingival-overgrowth with the help of soft tissue diode laser (Fig. 2 & 3) due to excessive bleeding tendency observed during clinical examination.

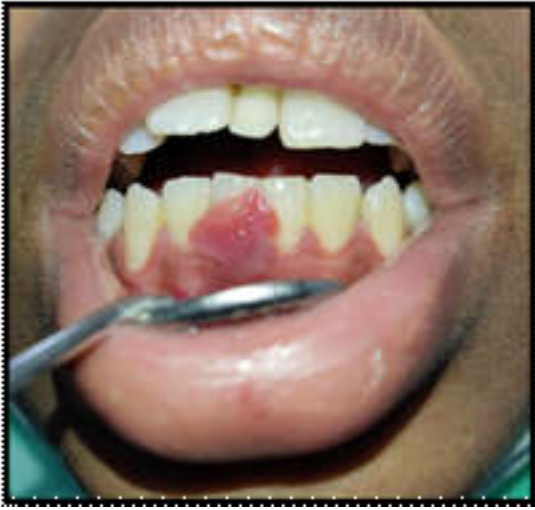

Fig. 1. Pre-operative photograph of the lesion

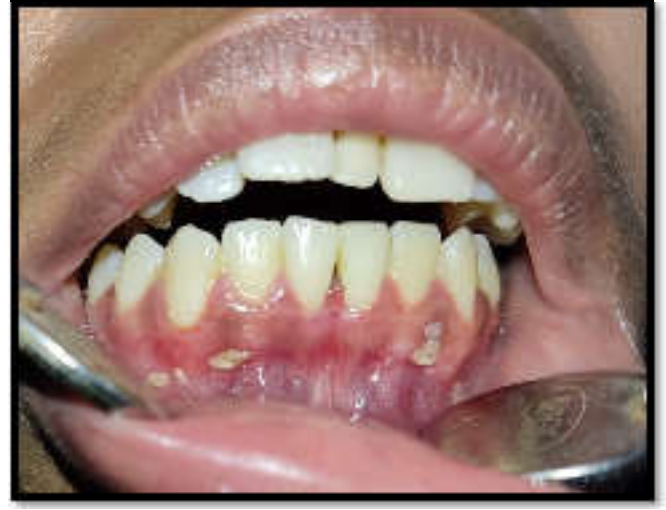

Fig.4. Three months Post-op view

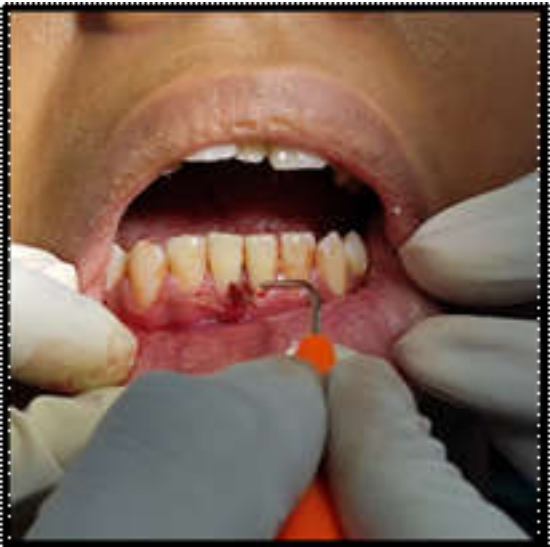

Fig. 2. Laser assisted excision of gingival overgrowth

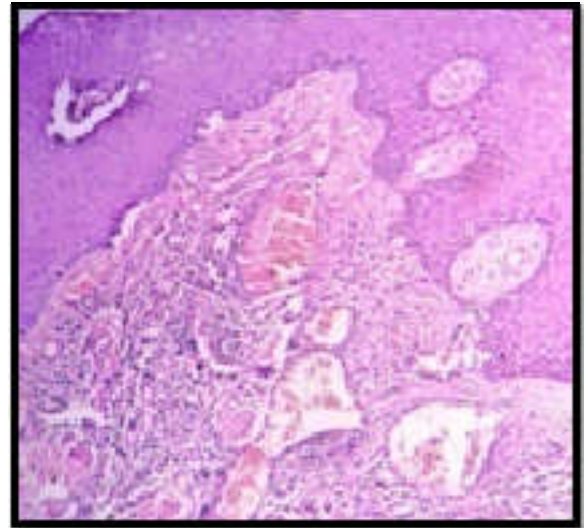


Fig. 5. Histopathological photograph suggested to be pyogenic granuloma

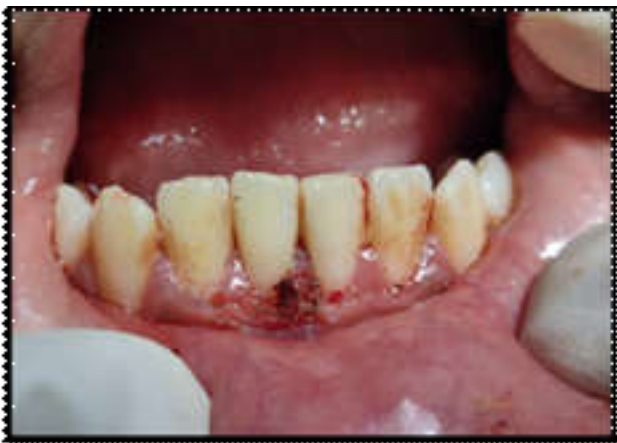

Fig. 3. Immediate post-op view of the lesion

CASE REPORT 2

A male patient aged 45 years reported with chief complaint of swelling in the left upper jaw region for last three months. The swelling gradually increased in size for last six months. The patient was found to be systemically healthy. On clinical examination, a solitary, firm, erythematous, sessile growth of 2cm X 1cm was noted in 25,26,27 region(Fig 6).

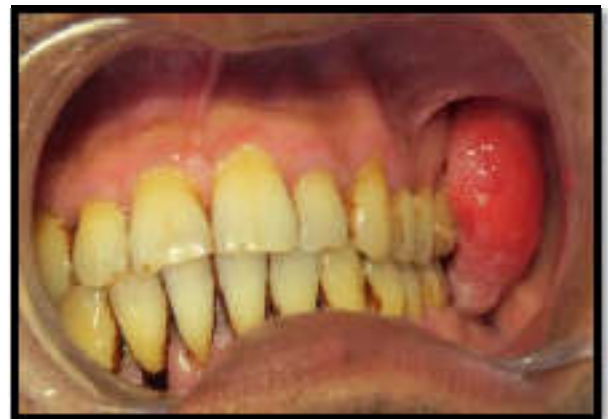

Fig. 6. Pre-operative photograph of the lesion

The patient was followed post-operatively up to three months (Fig.4) with no history of recurrence. The histopathological evaluation of the lesion revealed it to be a pyogenic granuloma with highly vascular lesion, proliferation of capillaries, infiltration of lymphocytes, plasma cells and neutrophils along with areas of fibrous connective tissue (Fig.5). The lesion was covered by ulcerated stratified squamous epithelium without atypia.

Oral hygiene of the patient was found to be poor. Radiographic examination revealed no bone loss in 26,27 region (Fig.7). The patient had undergone Phase I therapy followed by laser assisted excision of the localized gingival overgrowth (Fig.8 & Fig.9).

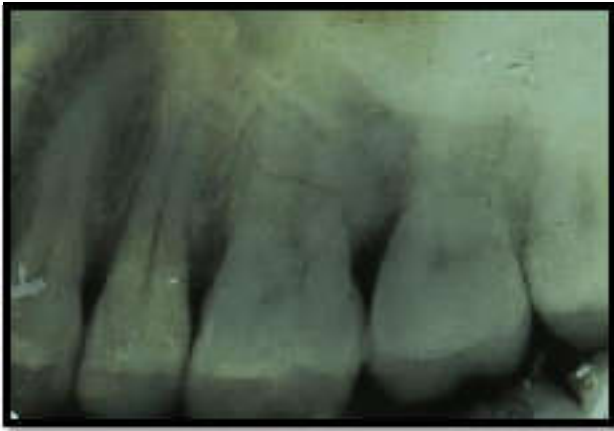

Fig. 7. Pre-operative radiograph of the lesion

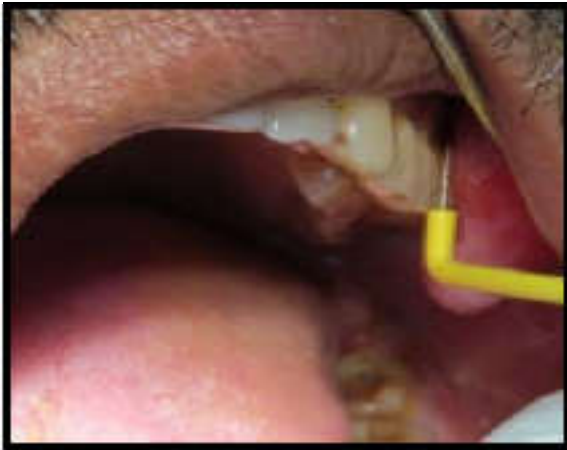

Fig. 8. Per-operative photograph of the procedure

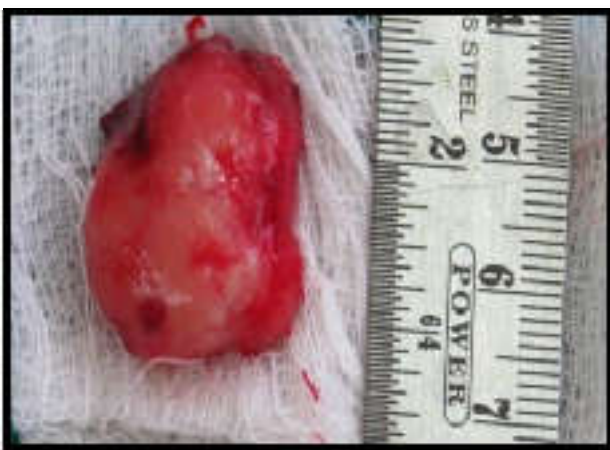

Fig.9.Excised tissue

The excised mass was sent for histopathological evaluation. The patient was followed post operatively with no history of recurrence (Fig.10).

Histopathological evaluation of the lesion revealed it to be pyogenic granuloma with proliferating capillaries, inflammatory infiltrate, along with the areas of fibrous connective tissue (Fig.11).

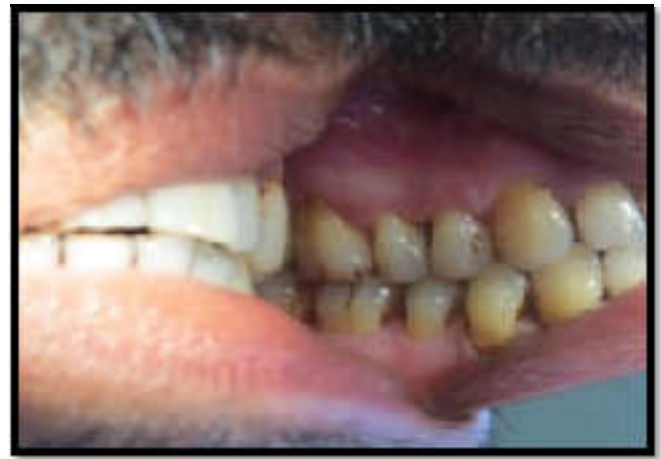

Fig.10. Three months post-operative view

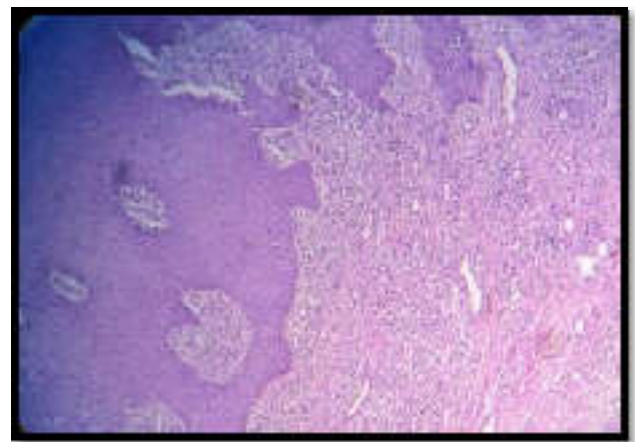


Fig. 11. Histopathological photograph revealed young proliferating capillaries, suggestive of pyogenic granuloma

DISCUSSION

Oral pyogenic granuloma is a common reactive lesion that can appear at any age, but is frequently seen in patients between the age of 11 and 40⁽¹⁻⁴⁾. Females, especially during pregnancy, are more frequently affected than men. Oral PGs have a strong predilection for the gingiva, with up to 70% of all cases occurring in this site alone^(1,6). Clinically, pyogenic granuloma is a smooth or lobulated exophytic lesion with small, erythematous papules on a pedunculated or sessile base. It bleeds easily and grows rapidly, usually asymptomatic and painless. The surface is often covered by fibrin and is ulcerated and friable due to masticatory trauma⁽⁵⁾. Depending on the age of the lesion, the color of the surface ranges from pink to red or purple. Young pyogenic granulomas have higher vascularity and hyperplastic granulation tissue, while older pyogenic granulomas have more collagen. Microbial agents such as streptococci and staphylococci may play a role in the etiopathogenesis of this lesion as they infect minor trauma sites during the healing process and vascular overproduction and tumor-like hyperplasia appears as a response. In the present case, poor oral hygiene (dental calculus) and irregular margins of the metal-ceramic crowns were the major predisposing factors. Differential diagnosis mainly includes vascular tumors like haemangioma, oral fibroma, peripheral giant cell granuloma, peripheral ossifying fibroma, or neoplastic lesions like Kaposi sarcoma, metastatic carcinoma and other malignant tumors.

In both the cases discussed above, localized gingival overgrowths excised effectively with the help of soft tissue diode laser with little or no bleeding during operative procedure and better healing during post-operative phases. Several authors are suggested that soft tissue lasers can be considered as an effective and safe technique for excision of PG with minimal invasion and superior clinical advantages such as less intra-operative bleeding, and reduced pain and time of healing⁽³⁻⁶⁾. The diode laser is manufactured from solid semi-conductor crystals made from aluminum (800 nm) or indium (900 nm), gallium and arsenic. The coherent laser beam at these particular wavelengths penetrates deep into the mucosa and is highly attenuated by the pigmented tissue, and at the same time is poorly absorbed by the dental hard tissues, so surgery can be safely performed. These lasers can also stimulate fibroblastic proliferation at low energy⁽⁴⁻⁶⁾. The diode lasers can be used in oral soft tissue surgery, especially in the context of small prominent lesions because of easy application, better coagulation, no need for suturing, less swelling and pain, and from an esthetic point of view for its potential in the treatment of physiologic gingival pigmentation. It can be considered as a first choice despite periodontal surgery due to; faster action, better re-epithelialization rates, little bleeding and better repair.

CONCLUSION

It is preferable to excise oral pyogenic granuloma with proper but not extended surgical management for the maintenance of gingival tissue, and from this standpoint the diode laser is a good treatment option.

Excessive bleeding, poor wound healing and recurrent infection are well known but laser surgery can obliterate these biological and operative complications and is thus recommended for routine clinical use.

REFERENCES

1. Ravindran DM, Sabarish R, Arul D, Ajit S, Harini DM. 2019. Laser-assisted Excision of Gingival Overgrowth in an Endodontic Perforation: A Case Report. *Cureus*. 2019;11(4):e4378. Published Apr 3. doi:10.7759/cureus.4378
2. Gex-Collet C, Itin P, Scherer K. 2008. Pyogenic granuloma treated with pulsed Nd:YAG (1064 nm) laser- A case series. *Med Laser Appl* 23:115-9.
3. Chaya D, Pankaj G. 2015. Lasers in dentistry: a review. *Int J Adv Health Sci.*, 2:7-13.
4. Fekrazad R, Nokhbatolfighahaei H, Khoei F, Kalhori K. 2014. Pyogenic granuloma: surgical treatment with Er:YAG laser. *J Lasers Med Sci.*, 5:199-205.
5. Reichart P, Philipsen HP. 2000. Color atlas of dental medicine, oral pathology. 1st ed. USA: Thieme. pp.163-164.
6. Andreadis D, Lazaridi I, Anagnostou E, Pouloupoulos A, Panta P, Patil S. 2019. Diode laser assisted excision of a gingival pyogenic granuloma: A case report. *Clin Pract*. 2019;9(3):1179. Published Aug 27. doi: 10.4081/cp.2019.1179
