



ISSN: 0975-833X

Available online at <http://www.ijournalcra.com>

*International Journal of Current Research*  
Vol. 15, Issue, 04, pp.24398-24404, April, 2023  
DOI: <https://doi.org/10.24941/ijcr.45188.04.2023>

INTERNATIONAL JOURNAL  
OF CURRENT RESEARCH

## RESEARCH ARTICLE

# PUTTY INDEX TECHNIQUE: A QUICK METHOD TO RESTORE SPACING AND FRACTURED TOOTH: CASE REPORTS

Dr. Pradnya V. Bansode<sup>1</sup>, Dr. Seema D. Pathak<sup>2</sup>, Dr. M. B. Wavdhane<sup>3</sup> and  
Dr. Apurva Satpute<sup>4</sup>

<sup>1</sup>Head of Department, Professor, Department of Conservative Dentistry and Endodontics, GDC & Hospital, Aurangabad, MUHS, India; <sup>2</sup>Professor, Department of Conservative Dentistry and Endodontics, GDC & Hospital, Aurangabad, MUHS; <sup>3</sup>Associate Professor, Department of Conservative Dentistry and Endodontics, GDC & Hospital, Aurangabad, MUHS, India; <sup>4</sup>MDS student, Department of Conservative Dentistry and Endodontics, GDC & Hospital, Aurangabad, MUHS, India

### ARTICLE INFO

#### Article History:

Received 04<sup>th</sup> January, 2023  
Received in revised form  
10<sup>th</sup> February, 2023  
Accepted 16<sup>th</sup> March, 2023  
Published online 30<sup>th</sup> April, 2023

#### Key words:

Space Closure, Composite resin  
Restoration, Putty Index, Maxillary  
Anteriors, Esthetic Treatment,  
Fractured Tooth Treatment.

#### \*Corresponding Author:

Deshmukh, A. G.

Copyright©2023, Pradnya V. Bansode et al. This is an open access article distributed under the Creative Commons Attribution License, which permits unrestricted use, distribution, and reproduction in any medium, provided the original work is properly cited.

Citation: Dr. Pradnya V. Bansode, Dr. Seema D. Pathak, Dr. Wavdhane, M. B. and Dr. Apurva Satpute. 2023. "Putty Index Technique: A Quick Method To Restore Spacing And Fractured Tooth: Case Reports". *International Journal of Current Research*, 15, (04), 24398-24404.

### ABSTRACT

Maxillary anterior spacing is a common aesthetic complaint of patients visiting to dental clinic. Common causes are microdontia, mesiodens, peg-shaped lateral incisors, agenesis, dental malformations. Various treatment modalities are available for space closure. Excellent aesthetics are possible with indirect restorations but there may be unnecessary tooth structure removal in order to achieve the desired results. When a larger space closure is needed, orthodontics may be indicated to allow for a more aesthetic outcome. When a space is less, no preparation of the tooth structure is necessary and direct composite bonding may yield the desired result. It gives the dentist and patient entire control over the construction of a natural smile. The following case reports show direct and indirect putty index technique for space closure in maxillary anterior teeth.

## INTRODUCTION

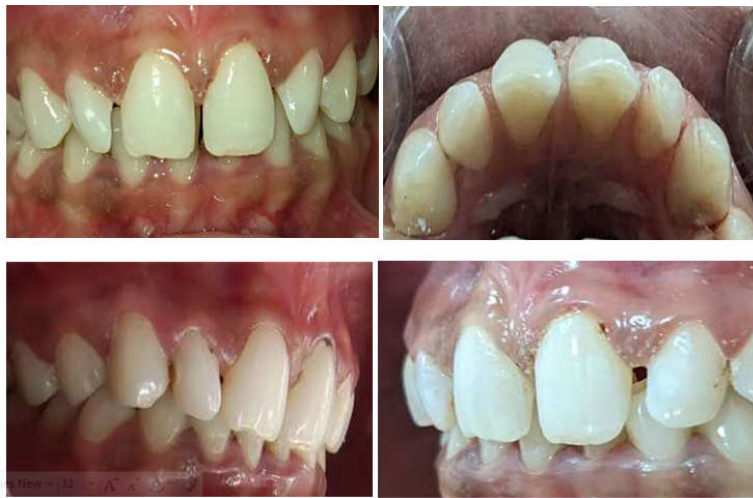Spacing in anterior teeth is a common aesthetic complaint in the dental clinic (1). It is multifactorial in aetiology. Some of the causes are presence of labial frenum, incomplete coalescence of the interdental septum, pseudomicrodontia, presence of a mesiodens, peg-shaped lateral incisors, congenital absence of lateral incisors, habits like finger sucking, tongue thrusting, lip sucking, discrepancy in the dental and skeletal parameters, and also genetics (2). A careful diagnosis allows the clinician to choose the most effective treatment plan. If the tooth-size discrepancy is less, they are mostly treated by composite resin restoration (3). Though various treatment modalities like direct composite veneers, indirect composite veneers, porcelain laminate veneers, all ceramic crowns, metal ceramic crowns are there but the development of composite resins with superior mechanical properties and excellent polishability allows the clinician to mimic the natural dentition and also render a long lasting outcome. Composite resins permit conservative treatment and at the same time offers quicker results (4).

Another advantage of composites is that they are economical compared to ceramic materials and can be repaired easily (5). The use of silicone index is one of the biggest innovative techniques in dentistry for anterior composite build up. A direct or indirect putty index technique with mylar strips perfectly defines the sagittal dimensions, the length, and the incisal edge position of the desired final restoration, the incisal thickness, mesial and distal line angles and the labial curvature of the restoration (6). The same technique is followed for 2 cases for space closure in maxillary anterior teeth.

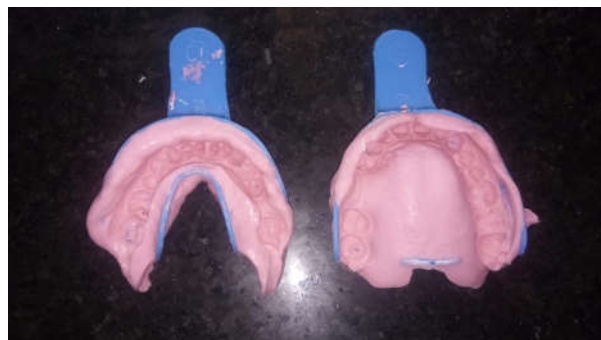**INDIRECT PUTTY INDEX TECHNIQUE****CASE REPORT 1**

A 24 year old female patient reported to the Department of Conservative Dentistry and Endodontics with the chief complaint of spacing in upper anterior teeth. On clinical examination spacing between maxillary anterior teeth was revealed and caries with lateral incisor of right side (Figure 1). The oral hygiene of the patient was satisfactory. No significant hard and soft tissue findings were found. The labial frenum associated with spacing was normal in size and position. Various treatment modalities (conservative restorative and prosthetic procedures including veneers and crowns) were discussed with the patient. A minimally invasive approach with a direct composite resin with indirect putty technique was planned to restore the spacing in teeth.

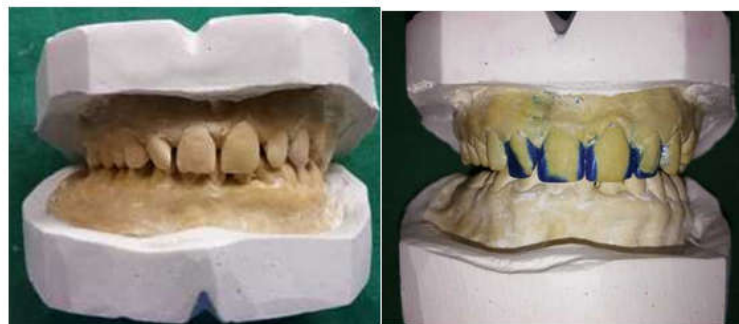**PROCEDURE:** Oral prophylaxis was done and preoperative photographs were taken. Preliminary impression of both the arches were made by using alginate impression material and preliminary cast was prepared (Figure 2,3). Space closure on cast were done by using inlay wax (Figure 3). Final impression of cast was made by using heavy body impression material (putty) (Figure 4). Clinically Isolation was done with cotton rolls and primary and secondary bevels were given on involved teeth. Caries excavation on lateral incisor was done (Figure 5). Shade selection was carried out by using VITA SHADE GUIDE. Etching with 37% phosphoric acid for 15sec followed by thorough rinsing and bonding with 5<sup>th</sup> generation bonding agent was done (Figure 6,7). Then palatal index was placed on palatal surface of anterior teeth and composite resin was placed (Figure 8). Once the palatal index is made, putty index was removed and the remaining teeth surfaces were restored by layering technique. Finishing, polishing of all restored teeth was done with yellow banded bur, rotary discs and polishing with polishing paste and cup (Figure 9).



**Figure 1. Preoperative clinical photographs**



**Figure 2. Preliminary impression of both the arches**



**Figure 3. Final cast with space closure by inlay wax**

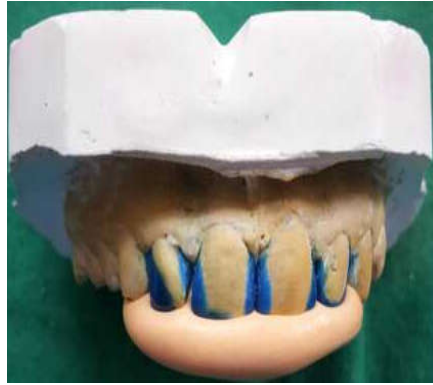

Figure 4. Putty impression on cast

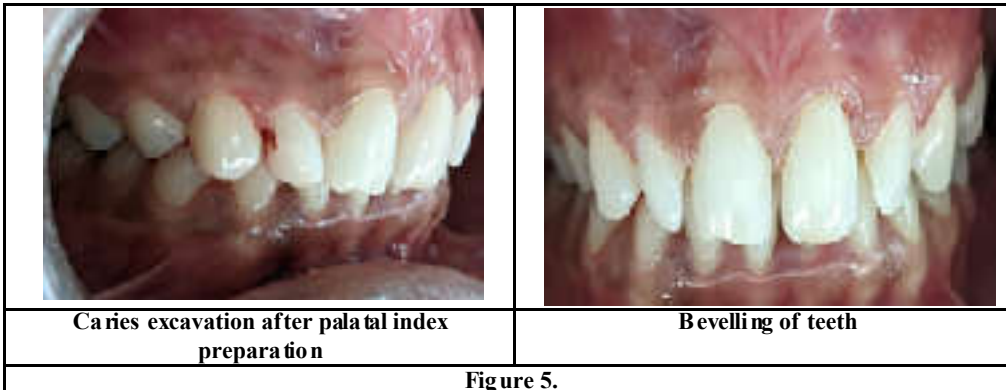


Figure 5.

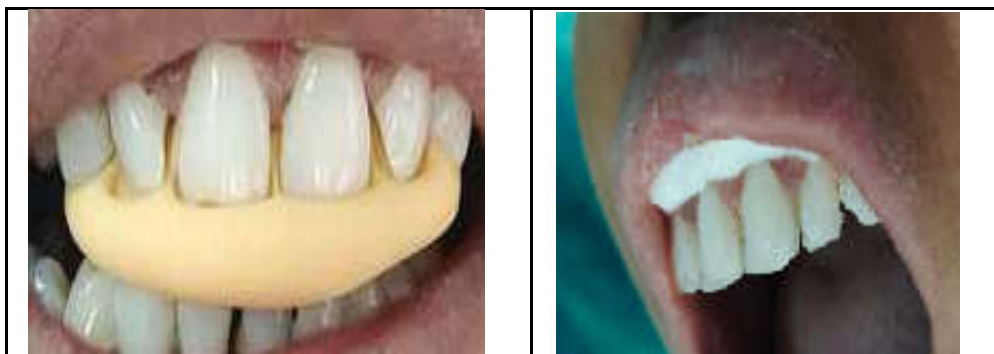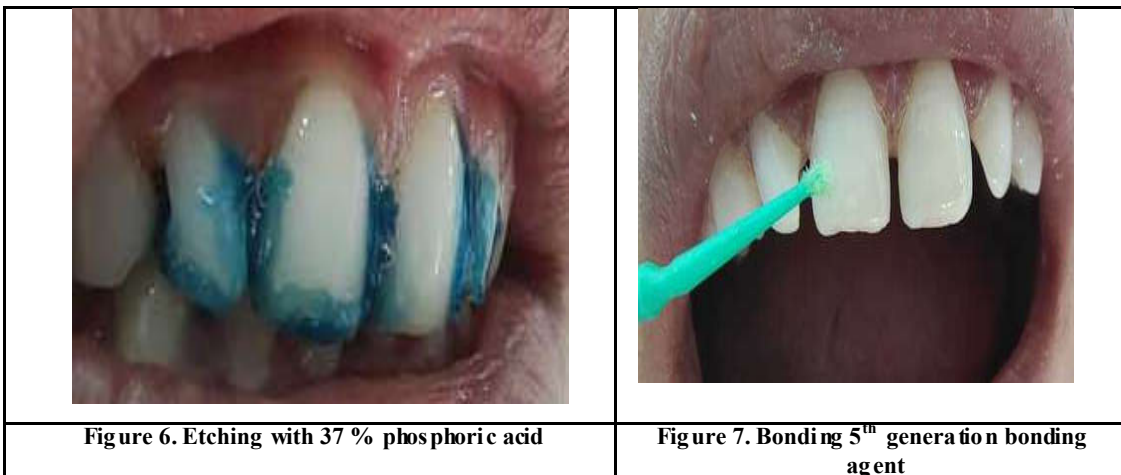


Figure 8. Putty impression in patient's mouth Palatal index was obtained

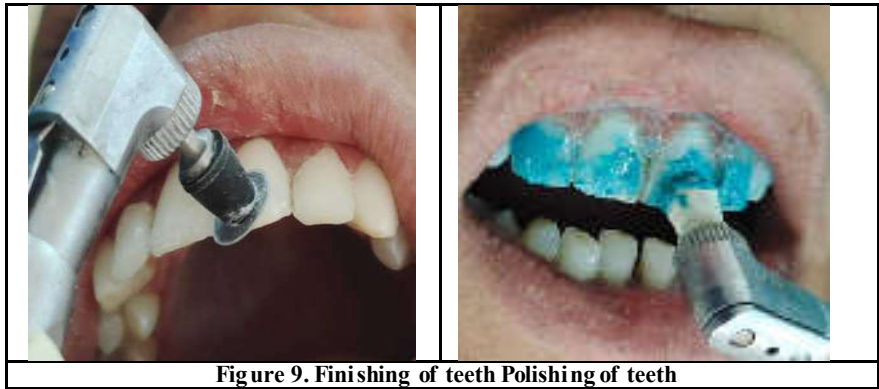

Figure 9. Finishing of teeth Polishing of teeth

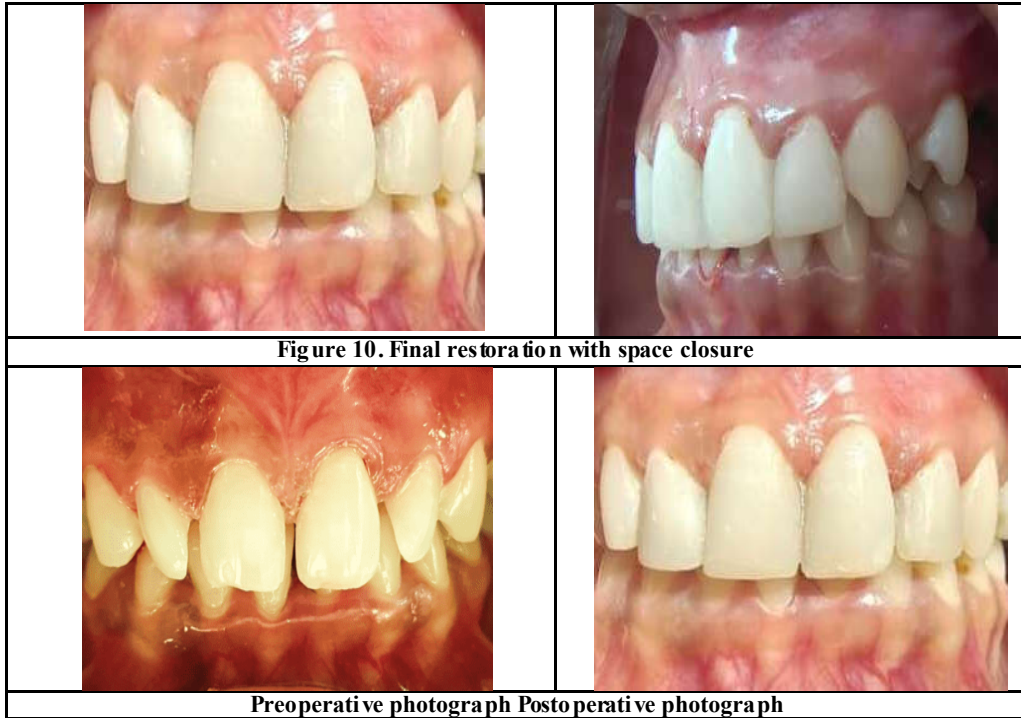


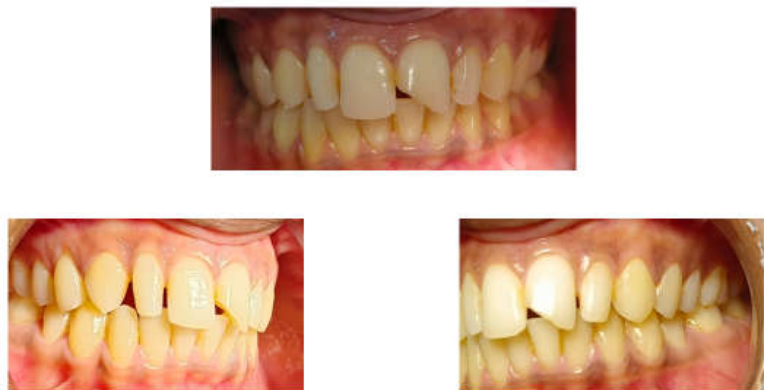Figure 10. Final restoration with space closure

Preoperative photograph Postoperative photograph

**DIRECT PUTTY INDEX TECHNIQUE**











**CASE REPORT 2** – A 28 years old female patient reported to the Department of Conservative Dentistry and Endodontics with the chief complaint of spacing in upper anterior teeth and fractured front tooth. On clinical examination spacing between maxillary anterior teeth was revealed and Ellis Class 2 fracture was noted with maxillary left central incisor (Figure a). Various treatment options were explained but most conservative, economic and less time consuming direct putty technique was planned to restore the spacing in teeth. Above procedure was followed except a direct putty impression ( final impression ) was made (Figure b )in patient’s mouth without making a preliminary cast and putty index was obtained (Figure c). Then the required changes were done directly in putty index by using scalpel blade (Figure d). Etching, bonding protocol were followed (Figure e,f).. Index was placed palatally to achieve desire shape of teeth (Figure g).Finishing, polishing of all restored teeth was done with yellow banded bur, rotary discs and polishing with polishing paste and cup. (Figure h)

**Preoperative clinical photographs**

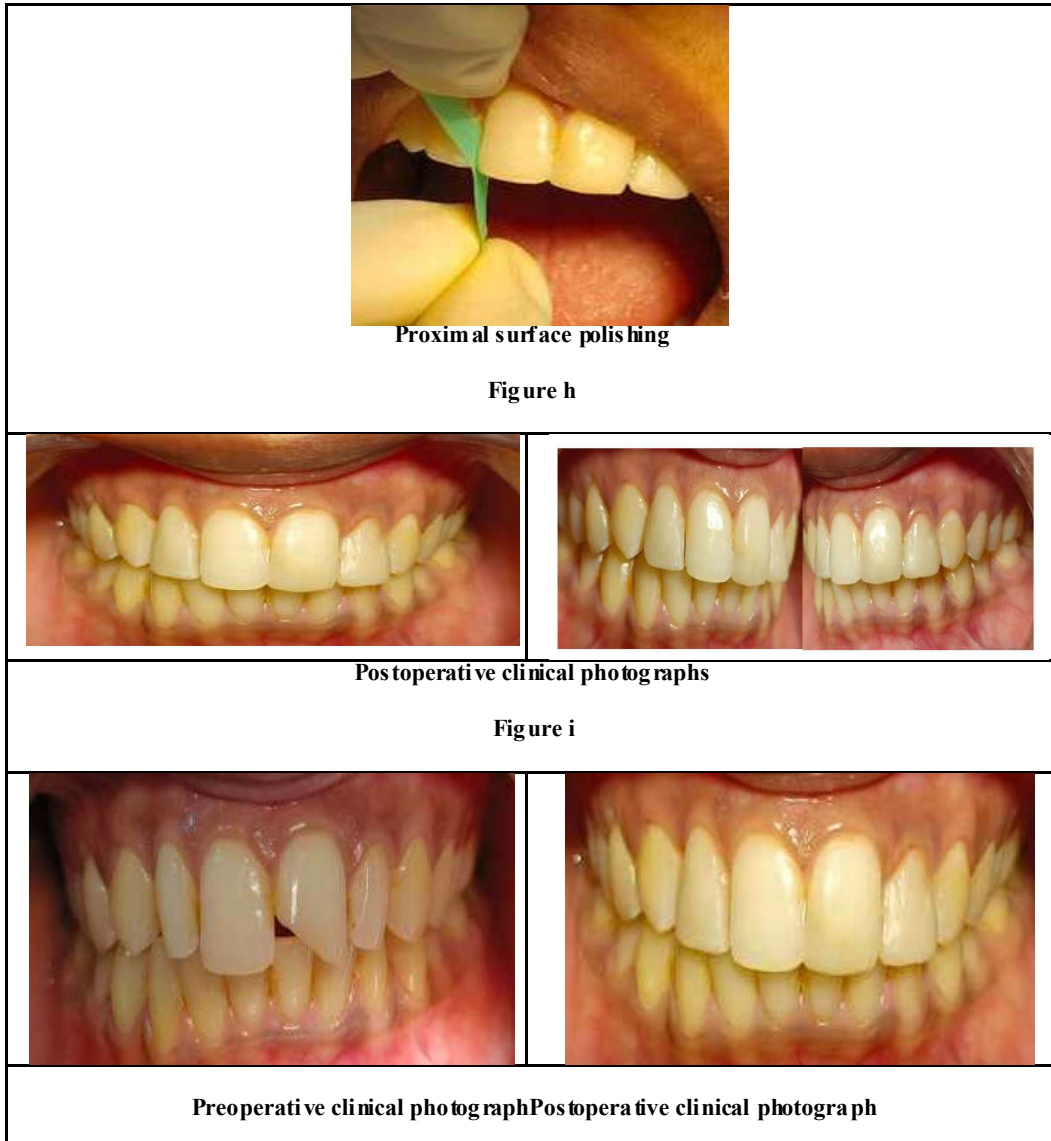


(Figure a)



	
<b>Figure b. Preliminary impression</b>	<b>Figure c. Original palatal index</b>
	
<b>Bevelling of teeth</b>	<b>Modified putty index</b>
<b>Figure d.</b>	
	
<b>Figure e. Etching with 37 % phosphoric acid</b>	<b>Figure f. Bonding 5th generation bonding agent</b>
	
<b>Flowable composite placement</b>	<b>Mylar strip for proximal surfaces</b>
<b>(Figure g)</b>	
	
<b>Finishing with bur</b>	<b>Finishing with disc</b>

Continue ....



Proximal surface polishing

Figure h

Postoperative clinical photographs

Figure i

Preoperative clinical photograph Postoperative clinical photograph

## DISCUSSION

Composite restoration offers a cost-effective treatment alternative where aesthetics is a primary concern. In case of uncomplicated crown fractures, direct composite resin restoration serve as less time consuming chair side treatment modality. With the advanced technology and improvements in the bonding systems there is increased success rate of direct composite restorations. In 1<sup>st</sup> case report , an Indirect putty matrix technique was planned. This putty index technique facilitates aesthetic reconstruction of the teeth structure by acting as guide that enables the dentists to plan the procedure in detail as the shape, size and inclination of the teeth are predetermined, that reduces the need of further adjustment. Besides acting as an index, it also serves as rigid plate that acts like a template to hold the restorative material, determination of incisal edge thickness and cervico - incisal length of teeth allows easy insertion in the portion that needs to be restored(7,8). A bevel was created to expose enamel rods and remove any unsupported tooth structure to ensure good bonding and good adaptation of composite and tooth interface . The layering of the composite resin was done subsequently followed by proper finishing and polishing in order to achieve a highly polished surface and a satisfied patient (Figure 10). In 2<sup>nd</sup> case report Direct putty index technique was done in order to minimize laboratory working time. Final impression was made with putty (Heavy Body) directly in patient's mouth instead of making preliminary cast model after which modifications were done. This method reduces extra laboratory time and can be carried out in the same visit. Both the techniques are cost effective and less time consuming.

## CONCLUSION

The clinical outcome of these case reports demonstrates that palatal putty replicating for composite restoration can be a reliable procedure for direct composite restoration. In these cases, the minimally invasive cosmetic method met the patient's aesthetic objectives and the natural tooth structure was attempted to be duplicated as closely as feasible.

**DECLARATION OF PATIENT CONSENT:** The authors certify that they have obtained all appropriate patient consent forms. In the form the patient(s) has/have given his/her/their consent for his/her/their images and other clinical information to be reported in the journal. The patients

understand that their names and initials will not be published and due efforts will be made to conceal their identity, but anonymity cannot be guaranteed.

**FINANCIAL SUPPORT AND SPONSORSHIP:** Nil.

**CONFLICTS OF INTEREST:** There are no conflicts of interest.

## REFERENCES

- Keene, H. J. "Distribution of diastemas in the dentition of man," *American Journal of Physical Anthropology*, vol. 21, no. 4, pp. 437-441, 1963
- Huang W. J. and C. J. Creath, "The midline diastema: a review of its etiology and treatment," *Pediatric Dentistry*, vol. 17, no. 3, pp. 171-179, 1995.
- Nahsan FP, Mondelli RF, Franco EB, Naufel FS, Ueda JK, Schmitt VL, Baseggio W. Clinical strategies for esthetic excellence in anterior tooth restorations: understanding color and composite resin selection. *J Appl Oral Sci*. 2012 Mar-Apr;20(2):1
- Kovacs BO, Mehta SB, Banerji S, Millar BJ. Aesthetic smile evaluation – A non-invasive solution. *Dent Update* 2011;38:452-4, 456-8.
- Sangavi, Tamizharasan & Subbiya, Arunajetasan & Geethapriya, Nagarajan & (alias) Malathi Suresh, S. Mitthra & Sangavi, Tamizharasan. (2019). Closure of Midline Diastema by Composite Resin Build-up: A Case Report. *Indian Journal of Public Health Research and Development*. 10. 2845-2847. 10.5958/0976-5506.2019.04056.7.
- Dr. Pradnya V. Bansode, Dr. Seema D. Pathak, Dr M. B. Wavdhane, Dr. Aarti Pathak, "Anterior Midline Diastema Closure with Putty Index - A Case Report", *International Journal of Science and Research (IJSR)*, Volume 10 Issue 7, July 2021, pp. 1036-1039
- Hassan A, Shahid O. Esthetic Restorations, The putty matrix Technique. *J Dow Uni Health Sci* 2013;7(3) 122-125
- Santos MPA, Maia LC, The Reference Guide ; A Step by step Technique for Restoration of Fractured Anterior Permanent Teeth, *J Can Dent Assoc* 2005,71 (9):643-646.