



REVIEW ARTICLE

DE WINTER ECG PATTERN: RECOGNIZING AN ACUTE LAD OCCLUSION

^{*1}Dr. Shweta Awasthi, ²Dr. Abhijit Baral and ³Dr. Indranil Das

¹Postgraduate Trainee[DNB Emergency Medicine], Medica Superspeciality Hospital Kolkata[MSHK]

²DNB[Emergency Medicine], Consultant, Dept. Emergency Medicine, MSHK

³MBBS, FEM[RCGP-UK], MEM[GWU-USA], MRCEM-UK, Sr. Consultant and HOD, Dept. Emergency Medicine, MSHK

ARTICLE INFO

Article History:

Received 09th March, 2025

Received in revised form

21st April, 2025

Accepted 19th May, 2025

Published online 30th June, 2025

Key Words:

De Winter Pattern, Acute Coronary Syndrome (ACS), Acute Myocardial Infarction (AMI), STEMI Equivalent, Proximal LAD Occlusion, Left Anterior Descending Artery, Primary Percutaneous Coronary Intervention (PCI), Coronary Angiography, Multivessel Disease, Right Coronary Artery Stenosis, Staged PCI, Electrocardiogram (ECG), Echocardiography, Left Ventricular Dysfunction, Premature Coronary Artery Disease, Young Adult, South Asian Ethnicity, India, Case Report, Diagnosis without Troponin.

*Corresponding author:

Dr. Shweta Awasthi,

ABSTRACT

The de Winter electrocardiogram (ECG) pattern is a critical STEMI equivalent indicating acute proximal Left Anterior Descending (LAD) artery occlusion, occurring in 2% of such cases and often missed by automated interpretation. We present a 41-year-old South Asian male from Kolkata with acute chest pain whose initial ECG, recorded pre-hospital, demonstrated the classic de Winter pattern, prompting pre-treatment. Emergent coronary angiography confirmed total proximal LAD occlusion (Infarct-Related Artery) and critical proximal Right Coronary Artery stenosis (Double Vessel Disease), signifying premature CAD. Successful primary Percutaneous Coronary Intervention (PCI) revascularized the LAD (TIMI III flow). Diagnosis relied on converging clinical, ECG, and imaging findings, as cardiac troponins were not measured. Post-procedure echocardiography showed moderate LV dysfunction (LVEF 40%) with corresponding wall motion abnormalities and acute diastolic dysfunction. The patient recovered uneventfully, discharged on Day 4 post-PCI with planned staged RCA PCI and comprehensive recovery support planning. This case underscores the imperative to recognize the de Winter pattern for rapid reperfusion, highlights management based on multimodal evidence when biomarkers are absent, and exemplifies the challenge of premature, complex CAD in young South Asians, a population with disproportionately high rates (incidence in young Indians ~12-16%).

Copyright©2025, Shweta Awasthi et al. This is an open access article distributed under the Creative Commons Attribution License, which permits unrestricted use, distribution, and reproduction in any medium, provided the original work is properly cited.

Citation: Dr. Shweta Awasthi, Dr. Abhijit Baral and Dr. Indranil Das, 2025. "De winter ecg pattern: recognizing an acute lad occlusion". International Journal of Current Research, 17, (07), 33507-33510.

INTRODUCTION

Acute Coronary Syndrome (ACS), typically precipitated by atherosclerotic plaque instability and thrombosis (9), demands prompt recognition and intervention. Beyond classic ST-segment elevation myocardial infarction (STEMI), several patterns lacking classic ST elevation are recognized as STEMI equivalents, also demanding immediate reperfusion (10). The de Winter pattern, identified in 2008 (3), is a key example. It features >1 mm upsloping ST-segment depression at the J-point joined with tall, peaked, symmetrical T-waves in leads V1-V6, often with minor ST elevation in aVR (3, 4). Found in 2% of acute LAD occlusions (3, 5, 12), it strongly predicts acute occlusion of the proximal LAD, threatening a substantial area of the left ventricle and portending significant LV dysfunction (3, 11). Critically, this pattern may be misinterpreted by automated ECG software and clinicians unfamiliar with it, potentially delaying necessary reperfusion (6). This report details such a case from Kolkata, India, offering valuable educational insights.

CASE PRESENTATION

A 41-year-old South Asian male presented to our emergency department in Kolkata, reporting ~6 hours of severe, central chest pain with diaphoresis. An initial ECG, demonstrated findings that prompted administration of loading doses of DAPT and a statin. Symptoms persisted upon arrival at our center. He denied shortness of breath or syncope. No known drug allergies were reported. While specific traditional cardiovascular risk factors were not documented in the available admission notes, the patient's age (41 years) classifies this event as premature CAD (males <55 years), and his ethnicity places him in a demographic known for increased susceptibility to early-onset disease (17, 24). Initial examination revealed a conscious, alert (GCS 15/15), pale, mildly dehydrated patient. Vital signs: HR 92 bpm, RR 22/min, BP 120/80 mmHg, SpO2 100% RA, Temp 98.6°F, random blood glucose 117 mg/dL. Systemic examination was otherwise normal.

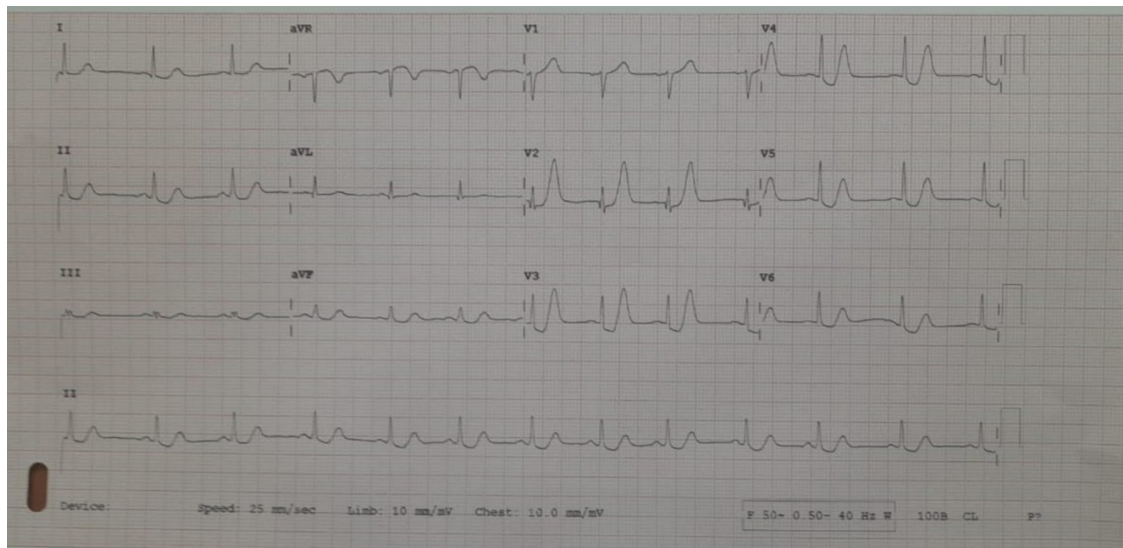


Figure 1: Initial 12-lead ECG (pre-hospital) exhibiting classic de Winter pattern. Note precordial upsloping J-point depression with tall, peaked, symmetrical T-waves and ST elevation in lead aVR

Investigations

- **Initial 12-Lead ECG (External Facility):** Showed sinus rhythm (~75 bpm) displaying the classic de Winter pattern (3): >2-3 mm upsloping ST depression at the J-point merging into tall, peaked, symmetrical T-waves (V2-V5), and ~0.5-1 mm ST elevation in aVR. No precordial ST elevation was present.
- **Laboratory Results:** Admission blood tests showed normal renal function (Creatinine 0.80 mg/dL), hemoglobin (14.6 g/dL), and potassium (4.30 mmol/L). Cardiac troponin assays were not performed during the hospital stay.
- **Echocardiography (Bedside):** Demonstrated severe hypokinesis of the entire LV apex with moderate LV systolic dysfunction (LVEF 40%). It also showed Grade II diastolic dysfunction. Such diastolic abnormalities are common findings even in the acute phase of myocardial infarction, resulting from impaired active relaxation due to ischemia and increased myocardial stiffness caused by acute cellular injury and edema within the infarct zone, rather than established scarring which develops later (1, 2). Mild MR and TR noted. Findings consistent with extensive infarction in the LAD territory (11).
- **Coronary Angiography (Emergent):** Right radial approach. Revealed Double Vessel Disease: total occlusion of the proximal LAD, identified as the Infarct-Related Artery (IRA), and critical (80-90%) proximal RCA stenosis. LCX non-dominant with minor plaque.
- **Follow-up ECG (Day 1 post-PCI):** Showed reperfusion and infarct evolution: sinus rhythm (64 bpm), Q waves V1-V2, isoelectric ST segments, normalized T waves, low precordial voltages.

Treatment and Management: The initial ECG pattern prompted immediate activation for emergent reperfusion via primary PCI, consistent with STEMI equivalent management protocols (1, 2, 22).

- **Primary PCI:** Successful PCI of the proximal LAD (IRA) with two DES (Supraflex Cruz: 3.5x20 mm proximal, 2.75x32 mm mid-LAD) achieved TIMI III flow.
- **Hemodynamic Support:** Transient low-dose norepinephrine was administered post-PCI.
- **Pharmacotherapy:** Discharge regimen included DAPT (Aspirin 75mg, Ticagrelor 90mg BID), Rosuvastatin 40mg daily, Pantoprazole 40mg daily, Nicorandil 5mg BID, Torsemide 5mg daily, Nitroglycerin SR 2.6mg BID, and Alprazolam PRN. Optimal medical therapy post-MI typically includes beta-blockers and ACE inhibitors/ARBs; these would usually be considered for initiation/titration after discharge

- based on patient tolerance and indications (1, 2, 22).
- **Staged PCI:** Staged PCI to the significant proximal RCA stenosis was recommended (1).

Outcome and Follow-up: The patient recovered well and remained asymptomatic. His post-procedure course was uncomplicated by major adverse cardiovascular events such as stent thrombosis, stroke, significant arrhythmia, or major bleeding. He was hemodynamically stable off vasopressors and discharged home on Day 4 post-PCI on prescribed medical therapy. Outpatient follow-up at 10 days was advised for ongoing clinical assessment, reinforcement of secondary prevention strategies, planning of the staged RCA PCI, and assessment for any emerging physical, cognitive, or psychosocial needs as part of the recovery process emphasized in current guidelines (22).

DISCUSSION

This case underscores the critical need for clinicians to recognize the de Winter pattern as a signifier of acute proximal LAD occlusion requiring immediate reperfusion (3, 5). Its ECG features distinguish it from mimics like hyperkalemia or Wellens' syndrome (13, 14). The pattern's genesis likely involves acute transmural ischemia altering repolarization pathways differently than classic STEMI (4, 7, 15). Accurate visual ECG interpretation remains paramount, as automated systems frequently miss this pattern (6). Global efforts to improve STEMI equivalent recognition include guideline updates and system-based protocols (1, 2, 6, 10, 16, 22). The patient's presentation at 41 years constitutes premature CAD. South Asians exhibit a higher burden of premature CAD, with incidence rates in young Indians reported around 12-16% (17, 24), linked to complex genetic and metabolic factors requiring aggressive secondary prevention (17). Although the de Winter pattern specifically localizes the acute event to the proximal LAD, this case also illustrates that patients presenting with STEMI equivalents can have significant underlying multivessel disease, reinforcing the importance of complete coronary assessment. The finding of critical RCA disease led to a recommendation for staged PCI. This strategy aligns with guideline recommendations (1, 7), often informed by trials evaluating multivessel PCI strategies, which generally favor staging in stable patients to reduce acute procedural risks (e.g., contrast load, procedure time) while aiming for complete revascularization. Diagnosing MI without cardiac biomarkers, as occurred here, relied on integrating compelling evidence: the clinical scenario, pathognomonic ECG with evolution, concordant echocardiographic findings, and angiographic confirmation (8, 19, 20). This approach, while not ideal, is sometimes necessary in emergent pathways prioritizing speed or in resource-variable settings, as can be reflected in data from registries like CREATE in India (18). The successful outcome likely benefited from

effective systems of care, from pre-hospital recognition to timely reperfusion (22).

Limitations: This case report's primary limitation is the absence of serial cardiac troponin measurements, though the diagnosis was robust based on other data. Detailed baseline cardiovascular risk factor information was also unavailable from the provided records. This report reflects a single case from one institution.

Learning Points

- **De Winter Pattern:** Is a STEMI equivalent (proximal LAD occlusion); recognize upsloping ST depression >1mm + tall peaked symmetrical T waves +/- aVR elevation (3, 5). Occurs in ~2% of LAD occlusions (3, 5, 12). Requires immediate reperfusion.
- **ECG Interpretation:** Prioritize visual analysis; differentiate de Winter from mimics (6, 13, 14).
- **Reperfusion:** Primary PCI is preferred if timely (<120 min suggested) (1, 2, 16).
- **Premature CAD:** High index of suspicion in young patients (<55 M), especially high-risk ethnicities (e.g., South Asians, incidence ~12-16% in young Indians) (17, 24).
- **Proximal LAD Occlusion Consequences:** Anticipate extensive anterior MI, LV dysfunction (systolic/diastolic) (1, 2, 11).
- **Multivessel Disease Strategy:** Staged PCI for significant non-culprit lesions is standard in stable patients post-primary PCI (1, 7).
- **Diagnosis Without Troponins:** Possible with compelling convergent clinical/ECG/imaging/angiographic evidence (8, 19, 20).
- **Post-MI Care:** Comprehensive approach: OMT (consider Beta-blockers/ACEi/ARBs), risk factor targets (e.g., BP <130/80, LDL-C <55-70 mg/dL), address 'Recovery' phase needs (1, 2, 22).

CONCLUSION

This case of a young South Asian man presenting with the de Winter ECG pattern highlights the imperative for rapid recognition of STEMI equivalents and timely primary PCI. It illustrates successful management of concomitant multivessel disease using a staged approach and underscores the possibility of confident MI diagnosis based on integrated clinical evidence, even without biomarker confirmation. Comprehensive post-discharge care focusing on secondary prevention and holistic recovery is essential, particularly given the context of premature coronary artery disease.

REFERENCES

1. Ibanez B, James S, Agewall S, Antunes MJ, Bucciarelli-Ducci C, Bueno H, *et al.* 2017 ESC Guidelines for the management of acute myocardial infarction in patients presenting with ST-segment elevation: The Task Force for the management of acute myocardial infarction in patients presenting with ST-segment elevation of the European Society of Cardiology (ESC). *Eur Heart J.* 2018 Jan 7;39(2):119-177. doi: 10.1093/eurheartj/ehx393.
2. O'Gara PT, Kushner FG, Ascheim DD, Casey DE Jr, Chung MK, de Lemos JA, *et al.* 2013 ACCF/AHA guideline for the management of ST-elevation myocardial infarction: a report of the American College of Cardiology Foundation/American Heart Association Task Force on Practice Guidelines. *Circulation.* 2013 Jan 29;127(4):e362-425. doi: 10.1161/CIR.0b013e3182742cf6.
3. de Winter RJ, Verouden NJ, Wellens HJ, Wilde AA; Interventional Cardiologists of the Academic Medical Center. A new ECG sign of proximal LAD occlusion. *N Engl J Med.* 2008 Nov 6;359(19):2071-3. doi: 10.1056/NEJMc0804737.
4. Verouden NJ, Koch KT, Peters RJ, Henriques JP, Baan J, van der Schaaf RJ, Vis MM, Tijssen JG, Piek JJ, Wellens HJ, Wilde AA. Persistent precordial "hyperacute" T-waves signify proximal left anterior descending artery occlusion. *Heart.* 2009 Oct;95(20):1701-6. doi: 10.1136/hrt.2008.15persistent. Epub 2009 Jun 10.
5. Morris NP, Body R. The De Winter ECG pattern: morphology and accuracy for diagnosing acute coronary occlusion: a systematic review. *Eur J Emerg Med.* 2017 Aug;24(4):236-242. doi: 10.1097/MEJ.0000000000000449.
6. Rokos IC, French WJ, Mattu A, Nichol G, Farkouh ME, Reiffel J, Stone GW. Appropriate cardiac cath lab activation: optimizing electrocardiogram interpretation and clinical decision-making for acute ST-elevation myocardial infarction. *Am Heart J.* 2010 Dec;160(6):995-1003.e8. doi: 10.1016/j.ahj.2010.08.011.
7. Lawton JS, Tamis-Holland JE, Bangalore S, Bates ER, Beckie TM, Bischoff JM, *et al.* 2021 ACC/AHA/SCAI Guideline for Coronary Artery Revascularization: A Report of the American College of Cardiology/American Heart Association Joint Committee on Clinical Practice Guidelines. *Circulation.* 2022 Jan 18;145(3):e18-e114. doi: 10.1161/CIR.0000000000001038.
8. Thygesen K, Alpert JS, Jaffe AS, Chaitman BR, Bax JJ, Morrow DA, White HD; Executive Group on behalf of the Joint European Society of Cardiology (ESC)/American College of Cardiology (ACC)/American Heart Association (AHA)/World Heart Federation (WHF) Task Force for the Universal Definition of Myocardial Infarction. Fourth Universal Definition of Myocardial Infarction (2018). *Circulation.* 2018 Aug 28;138(9):e618-e651. doi: 10.1161/CIR.0000000000000617.
9. Libby P. Mechanisms of acute coronary syndromes and their implications for therapy. *N Engl J Med.* 2013 May 23;368(21):2004-13. doi: 10.1056/NEJMr1216063.
10. Birnbaum Y, Bayes de Luna A. Specific High-Risk Electrocardiographic Patterns in Acute Coronary Syndromes. *Circulation.* 2020 Jul 21;142(3):284-299. doi: 10.1161/CIRCULATIONAHA.120.046277.
11. Fuster V, Badimon L, Badimon JJ, Chesebro JH. The pathogenesis of coronary artery disease and the acute coronary syndromes (1). *N Engl J Med.* 1992 Jan 23;326(4):242-50. doi: 10.1056/NEJM199201233260406.
12. de Winter RW, Adams R, Amoroso G, Appelman Y, Ten Brinke L, Huybrechts R, *et al.* Prevalence and clinical implications of the 'de Winter' ECG pattern for STEMI recognition. *Neth Heart J.* 2019 Apr;27(4):222-228. doi: 10.1007/s12471-019-1232-x.
13. Rhinehardt J, Brady WJ, Perron AD, Mattu A. Electrocardiographic manifestations of Wellens' syndrome. *Am J Emerg Med.* 2002 Nov;20(7):638-43. doi: 10.1053/ajem.2002.34800.
14. Sommers MP, Brady WJ, Perron AD, Mattu A. The prominent T wave: electrocardiographic differential diagnosis. *Am J Emerg Med.* 2002 May;20(3):243-51. doi: 10.1053/ajem.2002.32612.
15. Di Toro A, Parisi G, Caruso V, Oreto G. De Winter pattern: an electrophysiological hypothesis derived from a clinical case. *J Cardiovasc Med (Hagerstown).* 2016 Sep;17(9):688-91. doi: 10.2459/JCM.0000000000000235.

16. Rathod KS, Jones DA, Jain AK, Lim P, MacCarthy PA, Rakhit RD, *et al.* Outcomes of Patients With ST-Elevation Myocardial Infarction Diagnosed by Prehospital Electrocardiogram: Insights From the London Heart Attack Group. *J Am Heart Assoc.* 2017 Nov 8;6(11):e006337. doi: 10.1161/JAHA.117.006337.
17. Singh A, Collins BL, Gupta A, Fatima A, Qamar A, Biery D, *et al.* Cardiovascular Risk Factors and Coronary Artery Disease in South Asians. *Circulation.* 2018;137(Suppl_1):AP084. (Abstract reference)
18. Xavier D, Pais P, Devereaux PJ, Xie C, Prabhakaran D, Reddy KS, *et al*; CREATE registry investigators. Treatment and outcomes of acute coronary syndromes in India (CREATE): a prospective analysis of registry data. *Lancet.* 2008 Apr 26;371(9622):1435-42. doi: 10.1016/S0140-6736(08)60623-6.
19. McCabe JM, Armstrong EJ, Kulkarni A, Hoffmayer KS, Bhawe PD, Garg S, *et al.* Prevalence and factors associated with false-positive cardiac catheterization laboratory activation in ST-segment elevation myocardial infarction. *J Am Coll Cardiol.* 2012 Feb 7;59(6):619-25. doi: 10.1016/j.jacc.2011.10.872.
20. Qayyum H, Khalid MF, Rahman ZU, Pervaiz MH, Ram P. Importance of Recognizing de Winter's Sign: A STEMI Equivalent. *Cureus.* 2020 Oct 2;12(10):e10766. doi: 10.7759/cureus.10766.
21. Lu B, Fu D, Zhou X, Gui M, Yao L, Li J. A middle-aged male patient with de Winter syndrome: a case report. *BMC Cardiovasc Disord.* 2020 Jul 18;20(1):342. doi: 10.1186/s12872-020-01619-6.
22. American Heart Association. Highlights of the 2020 American Heart Association Guidelines for CPR and ECC. Dallas, TX: American Heart Association; 2020.
23. Sun Z. Tips for writing a case report for the novice author. *J Med Radiat Sci.* 2013 Sep;60(3):108-13. doi: 10.1002/jmrs.18.
24. Vardhan H B P, Shankar N, Priya G G, Raj S S K. Premature Coronary Artery Disease in Indians and its Associated Risk Factors. *Heart India.* 2017;5(1):14-18. doi: 10.4103/2321-449x.203529
