



## CASE REPORT

# A RARE PRESENTATION OF TRIGEMINAL SCHWANNOMA WITH EXTENSIVE MULTIPLE CRANIAL NERVE PALSIES: A CASE REPORT

Dr. Mallinath S.M<sup>1</sup>, Dr. R.L. Meena<sup>2</sup>, Dr. Shailendra Gupta<sup>3</sup>, Dr. Rajveer Bunker<sup>4</sup>, Dr. Nitesh Gurjar<sup>5</sup> and Dr. Bhaskar Sai Vardhan Pentakota<sup>6</sup>

<sup>1,5,6</sup>Junior Resident, Department of Medicine, RNT Medical College Udaipur

<sup>2</sup>Senior Professor and Unit head, Department of Medicine, RNT Medical College Udaipur

<sup>3,4</sup>Assistant Professor, Department of Medicine, RNT Medical College Udaipur

## ARTICLE INFO

### Article History:

Received 17<sup>th</sup> February, 2025

Received in revised form

09<sup>th</sup> March, 2025

Accepted 15<sup>th</sup> April, 2025

Published online 28<sup>th</sup> May, 2025

### Keywords:

Trigeminal Schwannoma, Multiple Cranial Nerve Palsy, Ptosis, Headache, Earache.

### \*Corresponding author:

Dr. Mallinath S.M

Copyright©2025, Dr. Mallinath et al. 2025. This is an open access article distributed under the Creative Commons Attribution License, which permits unrestricted use, distribution, and reproduction in any medium, provided the original work is properly cited.

Citation: Dr. Mallinath S.M, Dr. R.L. Meena, Dr. Shailendra Gupta, Dr. Rajveer Bunker, Dr. Nitesh Gurjar and Dr. Bhaskar Sai Vardhan Pentakota, 2025. "A rare Presentation of Trigeminal Schwannoma with extensive multiple cranial nerve palsies: A Case Report". International Journal of Current Research, 17, (05), 32713-32716.

## ABSTRACT

**Background:** Trigeminal schwannoma is benign tumor arising from the Schwann cells of the trigeminal nerve<sup>1</sup>. While their clinical presentation typically involves trigeminal nerve dysfunction<sup>2</sup>, extensive involvement leading to multiple cranial nerve palsies is a less common occurrence, particularly as the initial presenting feature<sup>3</sup>. We report a rare case of a 47-year-old female presented with history of right-sided ptosis, headache, and earache since 4-months. Imaging studies revealed a large trigeminal schwannoma (40x34x22 mm) extending into the posterior cranial fossa and cavernous sinus, resulting in compression of multiple cranial nerves. This case highlights the atypical and potentially misleading initial symptoms of a large trigeminal schwannoma and emphasizes the importance of considering intracranial lesions in patients with seemingly isolated cranial nerve deficits. We discuss the clinical presentation and diagnostic findings in such rare and complex cases, along with a review of relevant literature.

## INTRODUCTION

Trigeminal schwannomas are benign, slow-growing tumors originating from the Schwann cells of the trigeminal nerve (cranial nerve V). They account for approximately 0.2-0.8% of all intracranial tumors and 8% of all cranial nerve schwannomas<sup>1, 3</sup>. The clinical presentation typically correlates with the location and size of the tumor, most commonly involving trigeminal nerve dysfunction, such as facial pain, sensory loss, and masticatory weakness<sup>2, 4</sup>. However, in cases of large tumors with extensive intracranial extension, compression of adjacent cranial nerves can occur, leading to multiple cranial nerve palsies<sup>5</sup>. While involvement of cranial nerves III, IV, and VI within the cavernous sinus is relatively more frequent in large trigeminal schwannomas, initial presentation with significant multiple cranial nerve deficits, particularly including the oculomotor nerve (causing ptosis) alongside headache and earache, can be atypical and pose diagnostic challenges<sup>6</sup>.

We present a rare case of a 47-year-old female presented with a four-months history of right-sided ptosis, headache, hypoesthesia of right side of face and earache. Subsequent imaging studies revealed a large trigeminal schwannoma with significant extension, compressing multiple cranial nerves. This report aims to highlight this unusual presentation and discuss the diagnostic considerations in such complex cases.

## CASE PRESENTATION

A 47-year-old female presented to medical OPD with a four-month history of progressive drooping of right upper eyelid (ptosis fig-1). This was accompanied by a persistent, dull, right-sided headache, localized primarily in the temporal and peri-orbital region. She also reported a constant, moderate-intensity right-sided earache, which was not associated with hearing loss, tinnitus, or discharge. There was no history of weakness of facial muscles, diplopia, seizures or any other neurological deficits. Her past medical history was unremarkable, and she had no known systemic illness.

On neurological examination

- Cranial Nerve III (Oculomotor):** Right-sided complete ptosis with restricted upward, downward, and medial gaze.
- Cranial Nerve IV (Trochlear):** Unable to turn the eye in and out.
- Cranial Nerve V (Trigeminal):** Hypoesthesia in the region supplied by V1 and V2 segment on the right side with diminished corneal reflex.
- Cranial Nerve VI (Abducens):** Inability to abduct the right eye.

The remainder of the cranial nerve examination, including motor function of the trigeminal nerve, facial nerve function, hearing, balance, and bulbar functions (IX, X, XI, XII), was unremarkable. Her

mental functions, General physical and other systemic examination was unremarkable.

**Diagnostic Workup: CE MRI OF BRAIN** -Axial T1-weighted post-gadolinium MRI scan (Fig –1, 2,3& 4)

There is evidence of extra-axial altered signal intensity permeative mass measuring approx (40x34x22) mm epicentred in right parasellar and right temporal fossa region, appearing isointense on T1W, heterogeneously hypointense on T2W, without any diffusion restriction on DWI images & showing avid heterogeneous enhancement. Anteriorly, the mass is seen infiltrating right lateral wall of cavernous sinus with non-separate visualization of right III, IV, VI and V1, V2 division of V cranial nerves and abutment of cavernosal part of right internal carotid artery.

white matter edema. Right internal auditory canal appears mildly effaced due to mass effect with T2W hyperintense signals in right mastoid air cells suggestive of mastoiditis. These neuro-imaging findings suggestive of right sided Nerve sheath tumour likely Trigeminal Schwannoma. Based on the imaging findings and the clinical presentation, a diagnosis of a large trigeminal schwannoma with multiple cranial nerve involvement (primarily III, IV, VI) was established. Other routine blood investigations, ultrasound abdomen and pelvis, Chest x-ray were found to be normal.

**Management:** Surgical procedure was performed with right fronto-temporal craniotomy with zygomatic trans-petrosal approach by neurosurgical team and tumour was excised successfully.

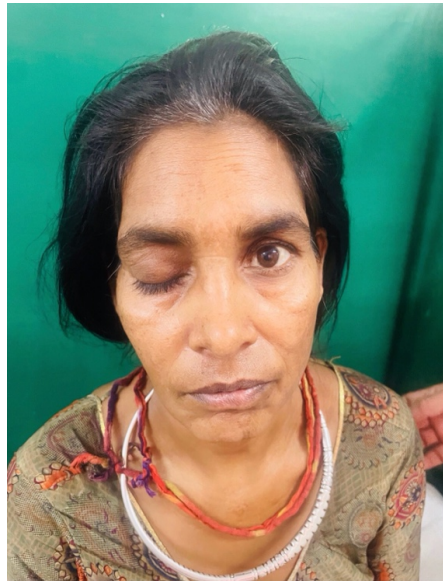

Fig. 1. Clinical photograph showing right-sided ptosis

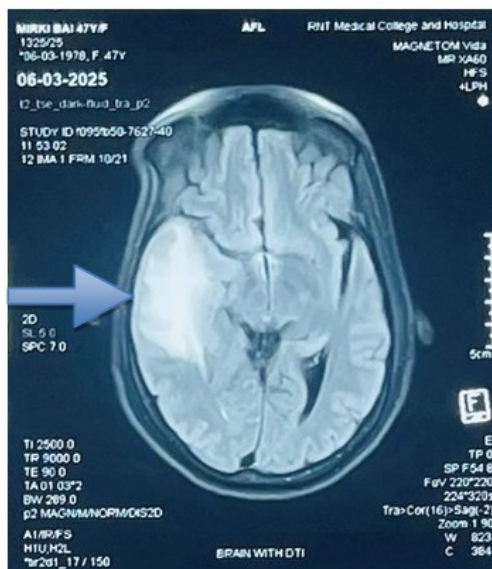

Fig. 2. (T1W image showing mass in right parasellar and right temporal fossa region)

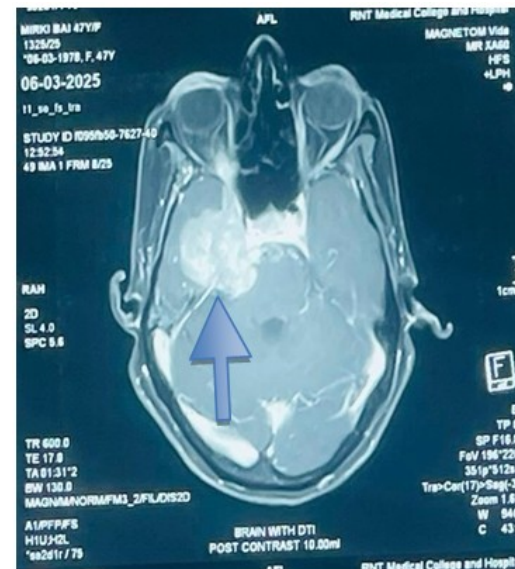


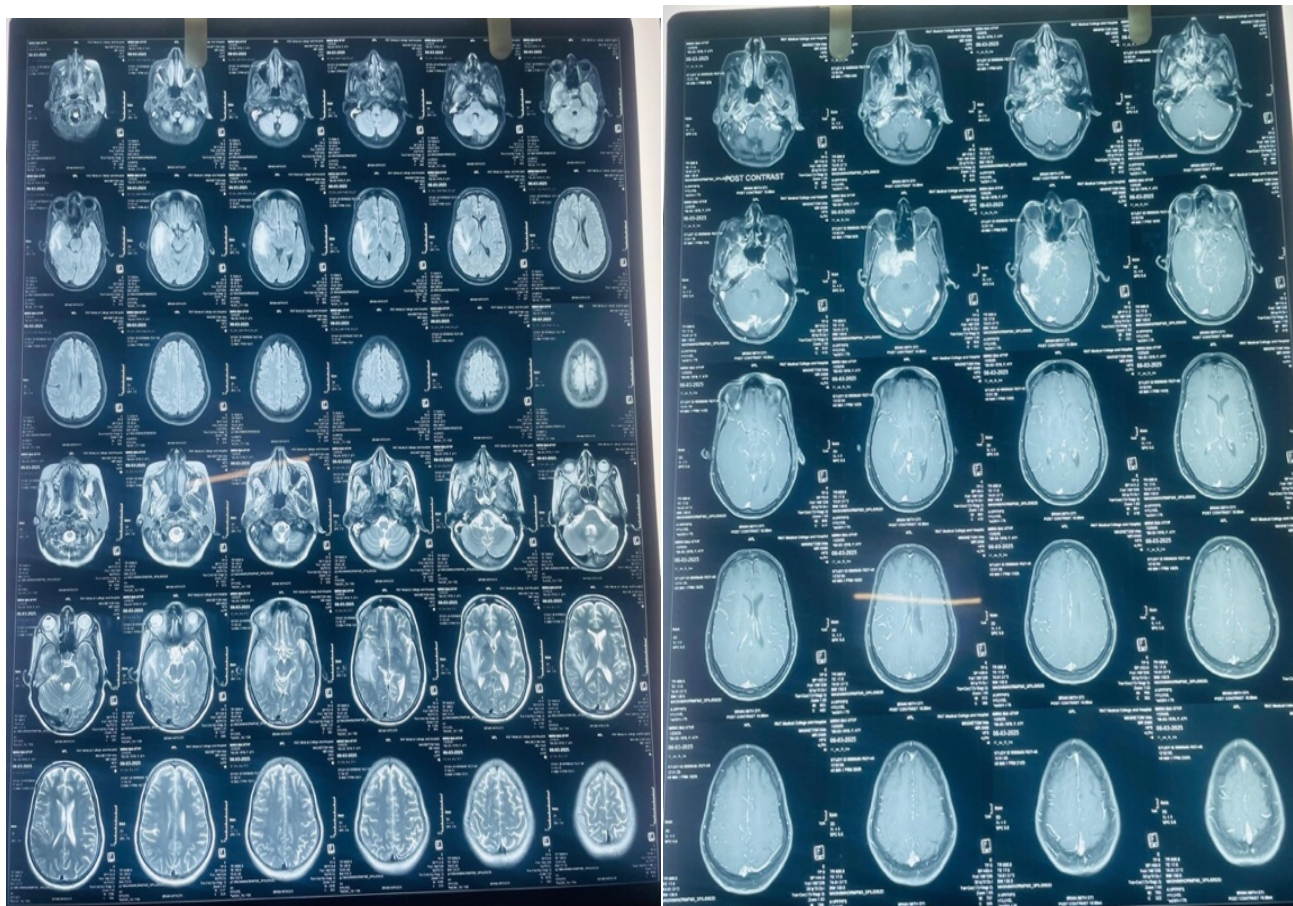Fig. 3. T1W image showing mass infiltrating right lateral wall of cavernous sinus & extending upto orbital apex

The mass is seen extending upto orbital apex with encasement of intraconal optic nerve sheath. Postero-medially, there is expansion and involvement of right meckel's cave. The mass is seen invading into right crural & ambient cistern with mass effect on adjacent right cerebral peduncle of midbrain, right half of pons and right middle cerebellar peduncle. Right cerebellopontine angle appears mildly obliterated by mass. Right tentorium & middle cranial fossa dura adjacent to the lesion appears thickened & enhancing. Laterally, there is mass effect on right temporal lobe causing T2W/FLAIR hypertense

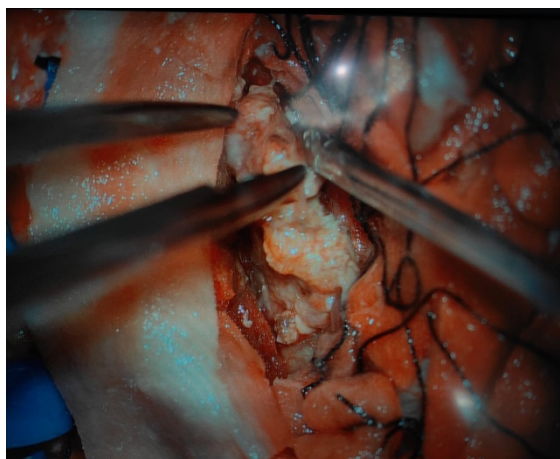
## DISCUSSION

This case illustrates a rare presentation of a large trigeminal schwannoma with initial symptoms primarily involving the oculomotor nerve (ptosis), accompanied by headache and earache, rather than the more typical trigeminal nerve dysfunction. The size and extensive intracranial extension of the tumor, involving both the posterior fossa and cavernous sinus, likely contributed to the





**Fig. 4 & 5 (MRI brain T1W image showing Trigeminal schwannoma)**



**Fig. 6. Intra operative picture showing Trigeminal schwannoma**

compression of multiple cranial nerves, leading to this atypical presentation. Trigeminal schwannomas are classified based on their primary location into three main types: Type A (middle cranial fossa), Type B (posterior cranial fossa), and Type C (dumbbell-shaped, extending into both fossae)<sup>3</sup>. Our case represents a large Type C schwannoma with significant extension into the cavernous sinus, which explains the involvement of the oculomotor nerve. The initial presentation with ptosis as the predominant symptom is unusual. Ptosis is more commonly associated with lesions affecting the oculomotor nerve within the cavernous sinus or superior orbital fissure<sup>4</sup>. While large trigeminal schwannomas can extend into these regions and compress the oculomotor nerve, it is less common for ptosis to be the primary presenting complaint before other trigeminal symptoms become prominent. The right-sided headache in this patient could be attributed to the mass effect of the large tumor<sup>5</sup> and the associated intracranial pressure changes.

The earache, in the absence of any audiovestibular symptoms or direct involvement of the vestibulo-cochlear nerve on imaging, is less straightforward. It could potentially be related to referred pain from the trigeminal nerve involvement<sup>6</sup> (particularly the mandibular branch, which has connections to the ear) or indirect pressure effects on nearby structures. The diagnostic modality of choice for trigeminal schwannomas is MRI with gadolinium enhancement, which provides excellent anatomical detail of the tumor and its relationship with surrounding neurovascular structures. In our case, MRI clearly shows the large tumor and its extension, paving way for the further management. This case highlights the importance of maintaining a broad differential diagnosis in patients presenting with cranial nerve deficits, even if the initial symptoms appear isolated. A high index of suspicion for intracranial lesions, including trigeminal schwannomas should be considered, especially in cases of progressive or atypical

presentations<sup>7,8</sup>. Prompt neuroimaging study is essential for accurate diagnosis<sup>7</sup>.

## CONCLUSION

We are presenting a rare case of large trigeminal schwannoma presenting with initial symptoms of right-sided ptosis, headache, and earache, preceding significant trigeminal nerve dysfunction. This unusual presentation underscores the potential for large intracranial tumors to manifest with atypical cranial nerve palsies. This case emphasizes the crucial role of comprehensive neurological evaluation and prompt neuroimaging in the diagnosis of such complex cases.

**Patient Consent:** Written informed consent was obtained from the patient for the publication of this case report.

**Conflict of Interest:** The authors declare no conflicts of interest.

**Funding Statement:** No funding was received for this study.

## REFERENCES

1. McCormick PC, Bello JA, Post KD. Trigeminal schwannomas. *J Neurosurg.* 1988; 69(6):837-44.
2. Yasargil MG, Sindou M, Wieser HG. Management of trigeminal schwannomas. *Acta Neurochir Suppl (Wien).* 1987;41:93-100. [3] Samii M, Tatagiba M, Matthies C. Trigeminal schwannomas. *Surg Neurol.* 1996; 46(6):571-82; discussion 582-3.
3. Oghabian, M. A., & Aminmansour, B. 2015. Trigeminal Schwannoma with Intracranial and Extracranial Extension: A Case Report. *Iranian journal of otorhinolaryngology*, 27(1), 79.
4. Kandemir, S., Seçkin, H. İ., Yılmaz, B., & Oncel, A. 2015. Giant trigeminal schwannoma presenting with atypical facial pain: a case report and review of the literature. *Turkish Neurosurgery*, 25(2), 328-332.
5. Lee, S. T., Chen, P. J., & Ho, Y. J. 2002. Trigeminal schwannoma presenting as primary trigeminal neuralgia. *Journal of clinical neuroscience*, 9(4), 450-452.
6. Maiuri, F., Gangemi, M., Iaconetta, G., Signorelli, F., & Giamundo, A. 1998. Trigeminal neurinomas presenting with trigeminal neuralgia: a series of 11 cases. *Acta Neurochirurgica*, 140, 875-879.
7. Grewal, S. S., Singh, M., & Sharma, R. R. 2011. Dumbbell-shaped trigeminal schwannoma presenting with trigeminal neuralgia: a rare case report and review of literature. *The Journal of Craniofacial Surgery*, 22(1), 329-332.
8. Jefferson, G. 1955. The trigeminal nerve in intracranial tumours. *Proceedings of the Royal Society of Medicine*, 48(6), 457.

\*\*\*\*\*