



ISSN: 0975-833X

CASE STUDY

SOME PROBLEMS AND DECISIONS IN ENDODONTIC PRACTICE

***Gusiyska, A.**

Department of Conservative Dentistry, Faculty of Dental Medicine, Medical University-Sofia, Bulgaria

ARTICLE INFO

Article History:

Received 21st March, 2015

Received in revised form

30th April, 2015

Accepted 12th May, 2015

Published online 30th June, 2015

ABSTRACT

The root canal treatment is one of the most common dental procedures, the aim of which is to save natural teeth and prevent the need for dental implants or bridges. With contemporary advances in endodontic techniques, increasingly complicated cases are undertaken of general dental practitioners—with variable results. Unfortunately, as a consequence the majority of procedures carried out by endodontic specialists today are retreatments. The aim of this review article is to focus on some problems of endodontic treatment and their management.

Key words:

Apical zone, Complicated cases, Endodontic problems. Retreatment. Root canal treatment.

Copyright © 2015 Gusiyska. This is an open access article distributed under the Creative Commons Attribution License, which permits unrestricted use, distribution, and reproduction in any medium, provided the original work is properly cited.

Citation: Gusiyska, A. 2015. "Some problems and decisions in endodontic practice", *International Journal of Current Research*, 7, (6), 17374-17378.

INTRODUCTION

The reporting of success in endodontic literature can be confusing because of the definition of "success/failure". One useful measure of success is the survival of a tooth after root canal treatment. Present day endodontics can achieve a 95-98% success rate in the primary session of a root canal treatment and 74-95% success rate in retreatment cases. Within the scope of endodontic treatment it is important to understand that first and foremost, is bacterial infection. Endodontic diagnosis is one of the fundamental concepts in endodontology. An accurate diagnosis is the basis of treatment. Implants have changed the rules in clinical endodontics by demanding a more precise endodontic therapy with a higher success rate. Apical periodontitis is primarily a sequel to microbial infection of the root-canal space in teeth. The clinical management of apical periodontitis involves infection control by root canal treatment, which is the only viable alternative to tooth loss. Epidemiological studies have shown that the prevalence of apical periodontitis in root-filled teeth ranged from 40% to 51%. However, the magnitude of this problem has not been fully appreciated. The process of case selection and treatment planning begins after a clinician has diagnosed an endodontic problem. The clinician must determine if the patient's oral

health needs are best met by providing endodontic treatment and maintaining the tooth or by advising extraction. This question is more complex than ever before because of the wide array of treatment modalities.

An ideal treatment plan should address the chief complaints of the patient; provide the longest-lasting, most cost-effective treatment; and meet or exceed patients' expectations whenever possible. A study of more than 1 400 000 root canal-treated teeth demonstrated that 97 percent of root canal-treated teeth were retained within an eight-year follow-up period (23). Thus, clinical outcomes of patients receiving care from practicing dentists across the entire United States provide dramatic evidence that endodontic treatment saves natural teeth with an extremely high level of success. Teeth that had no permanent restoration placed after root canal treatment were about two to four times more likely to be extracted than teeth that had permanent restorations. Thus, saving the natural tooth requires both good endodontic treatment and follow-up restorative treatment. Indeed, it is not merely the presence of a restoration, but instead, it is the quality of the permanent restoration that serves as an important predictor of long-term success of root canal treatment ([http://www.aae.org/uploadedfiles/publications_and_research/endodontics_colleagues; Mindiola et al., 2006; Ray and Trope, 1995; Tronstad et al., 2000](http://www.aae.org/uploadedfiles/publications_and_research/endodontics_colleagues_Mindiola_et_al.,_2006; Ray_and_Trope,_1995; Tronstad_et_al.,_2000)).

The quality of the endodontic treatment is important, with greater success rates and patient satisfaction observed when endodontists perform either nonsurgical (Alley et al., 2004;

***Corresponding author: Gusiyska, A.**

Department of Conservative Dentistry, Faculty of Dental Medicine, Medical University-Sofia, Bulgaria.

Dugas *et al.*, 2002) or surgical (Lazarski *et al.*, 2001) endodontic procedures (http://www.aae.org/uploadedfiles/publications_and_research/endodontics_colleagues). Thus, high-quality endodontic and restorative procedures play an important role in obtaining the high level of success that our patients expect and deserve (Doyle *et al.*, 2006). The treatment plan should be based not only on the expected overall benefit to oral health, but should include improvements in quality of life. The quality of life is an important factor when considering alternative clinical procedures such as single-tooth implant placement, where both esthetic problems and multiple repair appointments (Chapnick, 1989; Doyle *et al.*, 2006; Kaffe *et al.*, 1984) can impact this important patient issue (http://www.aae.org/uploadedfiles/publications_and_research/endodontics_colleagues).

2. General Problems and decisions

2.1. Diagnosis and prognosis

The goal of endodontic therapy is the prevention and elimination of pathosis of endodontic origin. Consensus report of the European Society of Endodontology on quality guidelines, generally accepted that correct diagnosis, proper debridement and preparation of the pulp cavity, and subsequent complete obturation of the prepared cavity are the triad essential for successful root canal therapy. Unfortunately initial bone lesions couldn't be detected on 2-dimentional radiographic images, so in contemporary dentistry cone-beam computer tomography is a useful 3-dimentional examination of periapical zone (Figure 1).

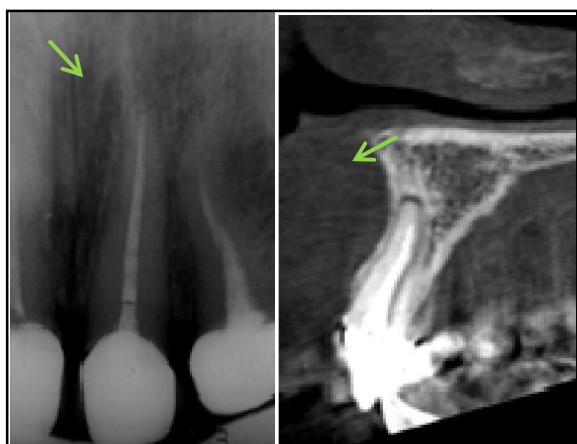

Figure 1. X-ray and CBCT of the tooth 21

2.2. Isolation of operative field

For the first time in endodontic practice Stanford Christie Barnum offers the use of rubber dam almost 150 years ago (Winkler, 1991). Rubber dam provided an excellent isolation from oral cavity environment and this isolation is decisive factor for preventive recontamination and long-term survival of the tooth (Figure 2).

2.3. Location of orifices

Location of all canals at difficult clinical cases is closely connected with appropriate coronal access.

Magnification

The use of magnification /from 4.5x up to 25x/ and fiberoptic transillumination, through the CEJ, is one of the decisions for careful examination of color changes and pulp chamber shapes and to help the clinician safety locate calcified canals, furcation canals /in 13%/, cracks and more detailed observation of the pulp floor and walls (Figure 3,4) (Baldassari-Cruz *et al.*, 2002).

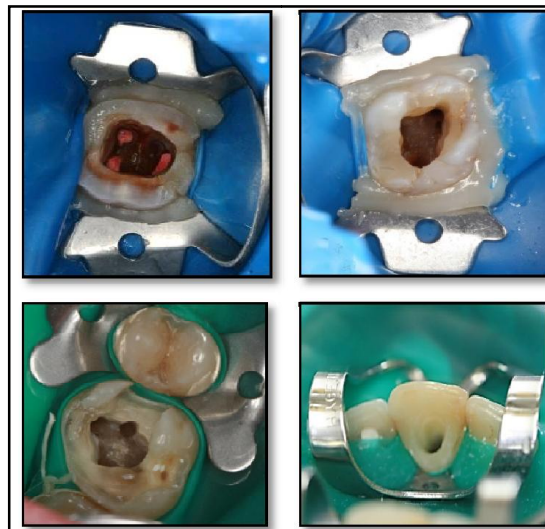

Figure 2. Isolated of operative field with rubber dam

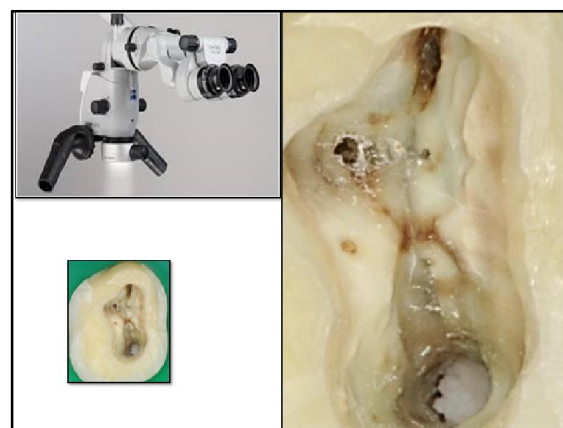


Figure 3. Magnification of pulp floor of tooth 26

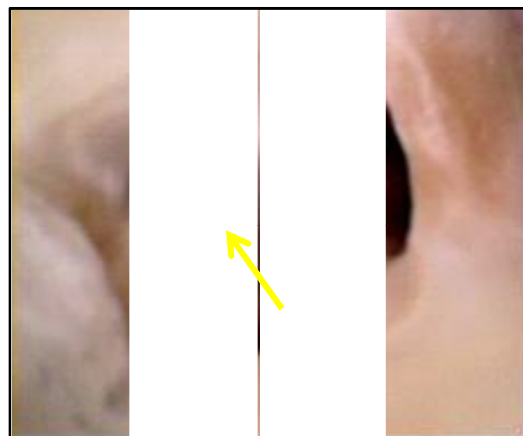


Figure 4. Furcation canal of tooth 46

Challenging in location of MB-2 orifices in maxillary molars

Negotiation of the MB-2 canal in maxillary first and second molars often is difficult (Buhrley *et al.*, 2002). A ledge of dentin covers its orifice, the orifice has a mesiobuccal inclination on the pulp floor, and the canal's pathway often takes one or two abrupt curves in the coronal part of the root. Most of these obstructions can be eliminated by ultrasonic tips. This must be done at 0.5 to 3mm in depth. The incidence of a MB2 canal in first molar retreatments was 67% compared to a 59% incidence in initial treatments. Whereas in second molars, the retreatment incidence was 44% compared with 35% in initial treatments. The significant difference in the incidence of a MB2 canal between initial treatments and retreatments suggests that failure to find and treat existing MB2 canals will decrease the long-term prognosis (Figure 5) (Sempira and Hartwell, 2000; Wolcott *et al.*, 2002).

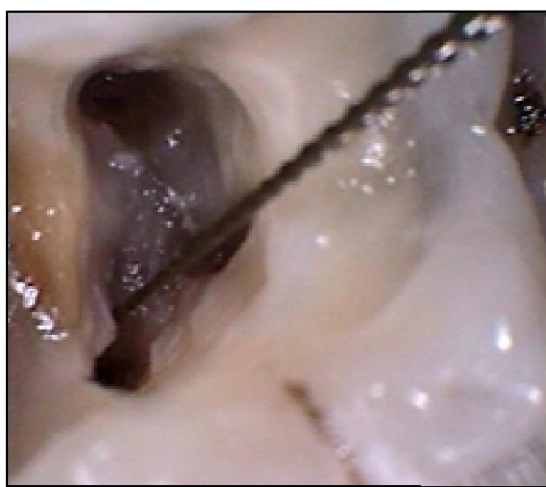

Figure 5. Location of MB₂. The K-file is into the MB₂ orifices

Root canal anatomy of maxillary molars is highly complex and unpredictable. The first maxillary molars have the largest volume and have generated more research than any other tooth. The knowledge of the normal anatomy and frequent variations can greatly enhance the success rate of endodontic treatment. The complexity of the root canal system of maxillary molars presents a constant challenge, as the dentist must have a thorough knowledge of the root canal morphology to provide successful endodontic treatment (Gusiyska, 2009).

2.4. Optimized canal preparation and appropriate coronal access

The traditional cleaning and shaping strategy (the step-back technique) focused on the initial preparation of the apical third of the root canal system, followed by various flaring techniques to facilitate maximum obturation to the apical zone (Figure 6). Coronal binding is caused by overhangs at the orifice level and also occurs when the canal is less tapered than an instrument, thus binding somewhere coronally. Passing a precurved negotiating file through a coronally tight canal will straighten the instrument. Nonflared canals do not allow efficient irrigation, which further predisposes to apical blockage.

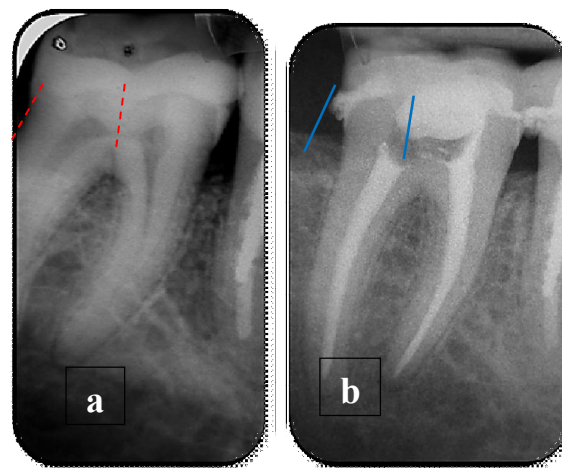


Figure 6. a, b. Optimized canal preparation with appropriate taper and appropriate coronal access.

Straight access is an important key to successful endodontic treatment. For optimized canal preparation we use crown-down technique. Nickel titanium endodontic files were five times more likely to achieve success than stainless steel files because they maintain the original canal shape during instrumentation (Buchanan, 2000).

2.5. Eliminating infection

Since larger preparations remove more bacterial cells, a high rate of treatment success is expected. Remaining pathogens may jeopardize the outcome of the root canal treatment. The intraradicular occurrence of bacteria was basically similar in both asymptomatic and symptomatic treated teeth, but larger numbers were evident in symptomatic teeth. Although not very common, extraradicular occurrence of bacteria was more frequent into the symptomatic teeth (Ricucci *et al.*, 2009). Irrigation with solution of NaOCl /2.5-5.25%/and EDTA /17%/in combination through ultrasonic, was found to be significantly more effective than saline in rendering canals free of bacteria and in opening of lateral canals in apical zone (Figure 7,8)

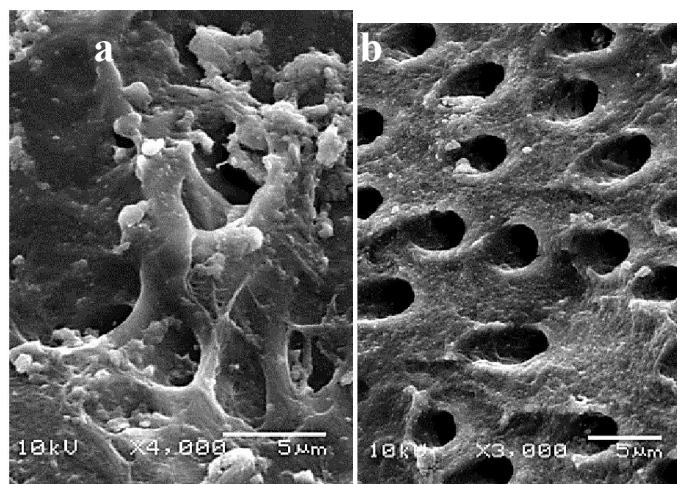


Figure 7. a/Smear layer of radicular dentin with microorganisms; b/Root canal wall with open dentin tubules after removal of smear layer

2.6. Contemporary concept of root canal filling – problems of management of apical control zone

A discussion about management of apical control zone pulp-periodontal disease would be incomplete without discussing the periapical reactions as a direct result of pulp infection.

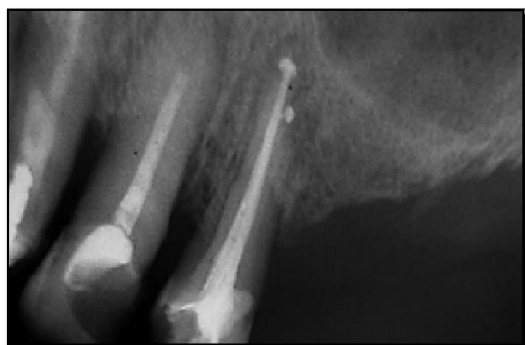

Figure 8. Obturated lateral canal on the tooth 24

The lack of apical control zone in result of chronic apical periodontitis is a challenge to have a long-term prognosis for these teeth. It is very sophisticated to seal the root canal system just to the apical foramen in cases with apical lesions. For this reason we proposed the biomimetical obturation of the lesion and the apical zone with bioceramic of calcium phosphate. Application of bioceramic of calcium phosphate into the zone of periapical lesion should be of favorable scaffold for bone regenerative processes and this will create a biomimetic apical control zone (Figure 9).

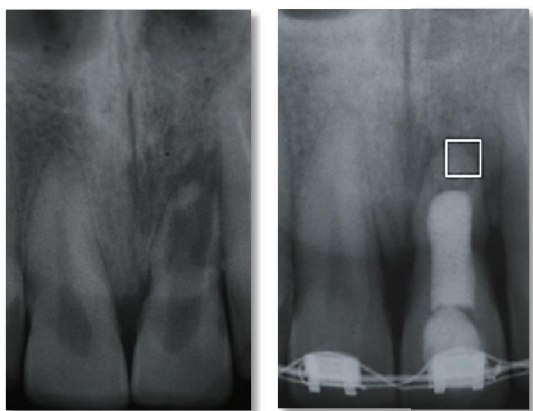


Figure 9. Application of bioceramic of calcium phosphate into zone and biomimetic approach to apical control zone (pre- and postoperative radiograph)

It is well known that calcium phosphate ceramics have received much attention as potential bone implant material. It was also shown that bioceramics of calcium phosphate have antimicrobial properties. All these problems we discussed as a complex process of bone metabolism that involves the resorption by osteoclasts and the subsequent formation of a woven bone. These activities are essential for bone remodeling, regeneration and repair for tissue engineering applications, 3D bone biomaterials must be capable of supporting the functional properties of osteogenic cells.

It is very important to know that once damaged the periodontal ligament has a low probability of regeneration and this is a challenge for root canal therapy. Repair of periodontal ligament appears to involve progenitor cells. Moreover, progenitor cells in endosteal spaces potentially migrate from the bone to periodontal ligament to form tissues of the periodontium. These mechanisms are unknown but that is a problem for the future.

2.7. Separated endodontic instruments

Success in endodontic therapy depends upon the appropriate removal of vital or nonvital pulpal tissue (Ruddle, 2002). It is a common misconception that a broken file is the specific cause of conventional endodontic treatment failure. However, the basis of endodontic treatment failure after a file breaks is the inability to remove the remaining vital or nonvital pulp tissue due to the impediment that the separated file poses, which can lead to inflammation or infection (Lin *et al.*, 2005).

The use of ultrasonic devices has been shown to be very successful for the removal of various canal obstructions (Nagai *et al.*, 1986). The use of ultrasonics is advantageous over conventional methods for removal of separated instruments as it is able to set separated instruments free from canals while making the immolate of dentin significantly less (Figure 10) (Gettleman *et al.*, 1991). The recommendations are to use endosonic tips with the smallest diameter possible in the curve of the root canals (Shiyakov and Vasileva, 2014).

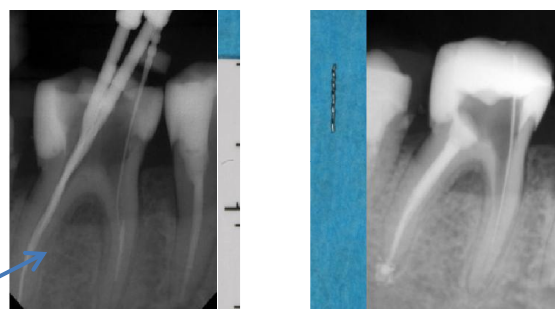


Figure 10. Removal of separated instrument

2.8. Vertical root fracture

Use of excess force during gutta-percha compaction too may cause vertical fracture.

It may happen during pin placement for core buildup following endodontic treatment, when excess force is applied and when a tapered pin or a post is placed. Clinical detection of fractures can be very difficult in the initial stages of development under beneath extensive restorations or in teeth after prosthetic treatment. Clinical signs and symptoms are often elusive in nature and may be difficult to detect or reproduce during patient examination (Peciuliene and Rimkuvienė, 2004). Radiographic signs of wide periodontal space, fracture line at horizontal slice from CBCT and intraoral fistula are clear evidence of a fracture available. The choice of extraction may often be the wisest course of treatment, provided that all other possibilities have been considered (Figure 11 a, b).

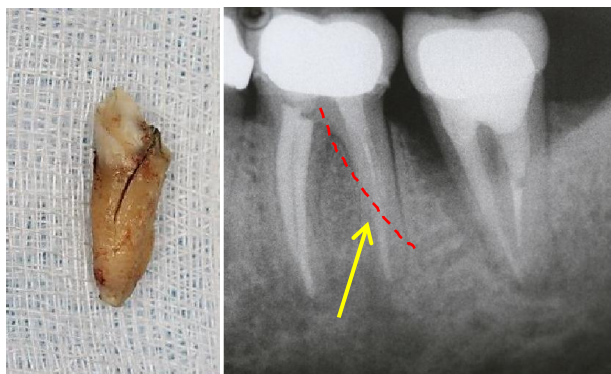


Figure 11. a/fracture line; b/radiographic sign of fracture of mesial root of mandibular molar

3. Conclusion

Accurate diagnosis, knowledge of the root canal morphology and the principles of modern preparation techniques are all essential so that appropriate chemical cleaning and disinfection of the entire root canal system is achieved. Modern dental practice is related to the continuous improvement of clinical techniques and materials. But the problems related to the treatment process have not yet been completely eliminated.

REFERENCES

- Alley BS, Kitchens GG, Alley LW, Eleazer PD. A comparison of survival of teeth following endodontic treatment performed by general dentists or by specialists. *Oral Surg Oral Med Oral Pathol Oral Radiol Endod.*, 2004;98(1):115-8.
- Baldassari-Cruz L, Lilly J, Rivera E. The influence of dental operating microscope in locating the mesiolingual canal orifice. *Oral Surg Oral Med Oral Pathol Oral Radiol Endod.*, 2002; 93(2):190-194.
- Buchanan LS. The standardized-taper root canal preparation – Part I. Concepts for variably tapered shaping instruments. *Int Endod J.*, 2000;33(6):516-529.
- Buhrley LJ, Barrows MJ, BeGole EA, Wenckus CS. Effect of magnification on locating the MB2 canal in maxillary molars. *J Endod.*, 2002 Apr;28(4):324-7.
- Burns RC, Buchanan LS: Ch.7, Tooth Morphology and Access Openings. In Cohen S, Burns RC, editors: *Pathways in the Pulp*, 6th ed., Mosby Yearbook Co, 1994
- Chapnick L. External root resorption: an experimental radiographic evaluation. *Oral Surg Oral Med Oral Pathol.*, 1989; 67: 578-82.
- Doyle S, Hoidges J, Pesun I, Law A, Bowles W. Retrospective cross sectional comparison of initial non-surgical endodontic treatment and single-tooth implants. *J Endod.*, 2006;31.
- Dugas NN, Lawrence HP, Teplitsky P, Friedman S. Quality of life and satisfaction outcomes of endodontic treatment. *J Endod.*, 2002;28(12):819-27.
- Dylgerova E. – Calcium phosphates and mineralized oral structures (demineralization, remineralization and reconstruction). D Sci Thesis, Sofia (1993).
- Gettleman BH, Spriggs KA, ElDeeb ME, *et al.* Removal of canal obstructions with the Endo Extractor. *J Endod.*, 1991;17:608-611.
- Gusiyska A. Endodontic treatment of a second maxillary molar with five root canals – a case report. *Journal of IMAB*, 2009;15(2):119-121.
- Gusiyska A. Remodeling of periapical lesions scaffolding by biphasic calcium phosphate ceramics - a pilot study. *J IMAB*, 2009, 2:113-118.
- http://www.aae.org/uploadedfiles/publications_and_research/endodontics_colleagues
- Kaffe I, Tamse A, Littner MM, Schwatz I. A radiographic survey of apical root resorption in pulpless permanent teeth. *Oral Surg Oral Med Oral Pathol.*, 1984; 58:109-12.
- Lazarski MP, Walker WA, 3rd, Flores CM, Schindler WG, Hargreaves KM. Epidemiological evaluation of the outcomes of nonsurgical root canal treatment in a large cohort of insured dental patients. *J Endod.*, 2001;27(12):791-6.
- Lin LM, Rosenberg PA, Lin J. Do procedural errors cause endodontic treatment failure? *J Am Dent Assoc.*, 2005;136:187-193.
- Mindiola MJ, Mickel AK, Sami C, Jones JJ, Lalumandier JA, Nelson SS. Endodontic treatment in an American Indian population: a 10-year retrospective study. *J Endod.*, 2006;32(9):828-32.
- Nagai O, Tani N, Kayaba Y, *et al.* Ultrasonic removal of broken instruments in root canals. *Int Endod J.*, 1986;19:298-304.
- Peculiene V, Rimkuviene J. Vertical Root Fractures in Endodontically Treated Teeth: A Clinical Survey. *Stomatologija, Baltic Dental and Maxillofacial Journal*, 2004;6:77-80.
- Ray HA, Trope M. Periapical status of endodontically treated teeth in relation to the technical quality of the root filling and the coronal restoration. *Int Endod J.*, 1995;28(1):12-8.
- Ricucci D, *et al.* Histologic investigation of root canal-treated teeth with apical periodontitis: a retrospective study from twenty-four patients. *J Endod.*, 2009; 35(4):493-502.
- Ruddle C. Nonsurgical endodontic retreatment. In: Cohen S, Burns RC, eds. *Pathways of the Pulp*. 8th ed. St Louis, Mo: Mosby; 2002:907.
- Salehrabi R, Rotstein I. Endodontic treatment outcomes in a large patient population in the USA: an epidemiological study. *J Endod.*, 2004;30(12):846-50.
- Sempira HN, Hartwell GR. Frequency of second mesiobuccal canals in maxillary molars as determined by use of an operating microscope: a clinical study. *J Endod.*, 2000 Nov;26(11):673-4.
- Shiyakov K, Vasileva R. Effectiveness in the curve of eight types of endodontic tips for broken instruments removal. *J of IMAB*, 2014 Oct-Dec;20(3):595-600.
- Tronstad L, Asbjørnsen K, Doving L, Pedersen I, Eriksen HM. Influence of coronal restorations on the periapical health of endodontically treated teeth. *Endod Dent Traumatol.*, 2000;16(5):218-21.
- Winkler R. Stanford Christie Barnum – inventor of the rubber dam. *Quintessence* 1991; 42: 483-486.
- Wolcott J, Ishley D, Kennedy W, Johnson S, Minnich S. Clinical investigation of second mesiobuccal canals in endodontically treated and retreated maxillary molars. *J Endod.*, 2002 Jun;28(6):477-9.
