



ISSN: 0975-833X

RESEARCH ARTICLE

MULTIDETECTOR COMPUTED TOMOGRAPHY IN VARIOUS PATHOLOGY OF  
PARANASAL SINUSES - CASE SERIES

\*Dr. Praveen Mahalingappa Mundaganur

Department of Radiology BLDE Hospital and Research Institute Bijapur - Karnataka 586103

ARTICLE INFO

Article History:

Received 15<sup>th</sup> September, 2015  
Received in revised form  
10<sup>th</sup> October, 2015  
Accepted 17<sup>th</sup> November, 2015  
Published online 30<sup>th</sup> December, 2015

Key words:

Extension  
Surrounding  
Structures  
Appreciated  
Determination.

Copyright © 2015 Praveen Mahalingappa Mundaganur. This is an open access article distributed under the Creative Commons Attribution License, which permits unrestricted use, distribution, and reproduction in any medium, provided the original work is properly cited.

Citation: Praveen Mahalingappa Mundaganur, 2015. "Multidetector computed tomography in various pathology of paranasal sinuses - case series", International Journal of Current Research, 7, (11), 24194-24202.

ABSTRACT

After the introduction of CT into clinical practice in 1972, the soft tissue extension from paranasal sinuses lesions could be visualized. The anatomical relationship of paranasal sinuses with surrounding structures could be directly appreciated. CT has capability of showing soft tissue detail relative to the osseous walls and air spaces of the paranasal sinuses. Such information is indispensable for determination of operability and planning of radiotherapy as well as for assessment after therapy. The latest generation of scanners such as MDCT, which have high resolution, thin sectioning and specific techniques for bone evaluation have established MDCT as overall best method for evaluation of patients who are suspected of having an aggressive lesion of the paranasal sinuses.

INTRODUCTION

Before the advent of CT scan, plain radiography aided by tomography had achieved high quality images of bony encasement of Para nasal sinuses. Conventional techniques could demonstrate tumor within the Para nasal sinuses as well as gross bone destruction, but soft tissue tumor extension was frequently not discovered leading to inappropriate attempt to radical surgery as involvement of infra temporal fossa, posterior ethmoidal air cells, orbital apex, cribriform plate, nasopharynx, sphenoid sinus or base of skull is virtually impossible to irradiate surgically. After the introduction of CT into clinical practice in 1972, the soft tissue extension from paranasal sinuses lesions could be visualized. The anatomical relationship of paranasal sinuses with surrounding structures could be directly appreciated. CT has capability of showing soft tissue detail relative to the osseous walls and air spaces of the paranasal sinuses. Such information is indispensable for determination of operability and planning of radiotherapy as well as for assessment after therapy. The latest generation of scanners such as MDCT, which have high resolution, thin sectioning and specific techniques for bone evaluation have

established MDCT as overall best method for evaluation of patients who are suspected of having an aggressive lesion of the paranasal sinuses.

Objectives

This study principally aimed to highlight the role of MDCT (6 slice) Scanning in lesions affecting paranasal sinuses.

The specific aims of the study were:

- To establish the role of MDCT in imaging of paranasal sinuses.
- To diagnose the involvement of paranasal sinuses by various lesions.
- To assess the extent of involvement of surrounding anatomical areas by various paranasal sinus lesions.
- To evaluate the characteristics of each lesion on MDCT.
- To study lesions which were inaccessible by conventional radiography.
- To differentiate fungal sinusitis from malignant involvement of paranasal sinuses and thus help in appropriate management of the patient.
- To evaluate critical areas of surgical importance that helps in F.E.S.S

\*Corresponding author: Dr. Praveen Mahalingappa Mundaganur,  
Department of Radiology BLDE Hospital and Research Institute  
Bijapur - Karnataka 586103.

## MATERIALS AND METHODS

### Study plan

- A Prospective study of the role of MDCT in detecting and characterizing PNS lesions was conducted in the period, June 2014 to may 2015.
- 60 patients were selected for this study, who presented with clinical symptoms and signs pertaining to PNS
- Confirmation of the diagnosis was done by following up patient with surgery and histopathology.

### Scanning and methods used

### Preparation of patient

- The patient should be empty stomach to avoid vomitus during contrast study.
- Pre-treatment with a sympathomimetic nasal spray 15 minutes prior to scanning in order to reduce nasal congestion (mucosal edema) and thus improve the display of the fine bony architecture and any irreversible mucosal disease.

All scans were performed on a MDCT (6 slice) Scanner brilliance (Philip's) machine.

- Axial sections were taken in all patients beginning from alveolar ridge and extending to the top of frontal sinus with automatic reconstruction of coronal and sagittal images.
- A section thickness of 5 mm was obtained with reconstruction of images of 1mm thickness.
- Images are obtained by taking sections in plane parallel to orbital meatal base line.
- Nonionic contrast medium containing 350 mg iodine/ml was used wherever necessary.

### Criteria

- Patients, whose clinical presentation suggested PNS pathology, MDCT examination was done as investigational work up.
- All patients who could be rescanned with CT for follow up or followed for histopathological/treatment confirmation.
- Patients who could not be followed up to the final diagnosis were excluded.

## RESULTS AND DISCUSSION

This prospective study of 60 cases of various lesions involving the para nasal sinuses was conducted at the department of radiology, BLDEU'S BM patil medical college bijapur.

Following observations were made according to age, sex, site, type of lesion, CT appearance, and were analysed as follows.

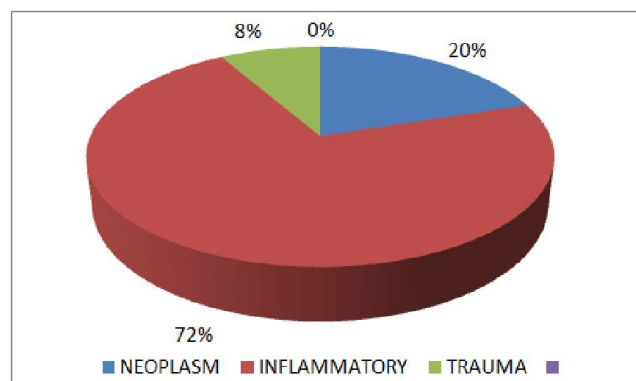
- Out of the 60 cases studied, 12 patients were of the neoplasm category. It included 3 cases of fibrous dysplasia, 1 case of ethmoid sinus osteoma, 2 cases of ossifying fibromas, 2 cases of malignancy and 2 cases of

Nasopharyngeal angiofibromas, 1 case of metastasis and 1 case of leukemic infiltration.

- 43 cases of inflammatory lesions and 5 cases of trauma were included.

**Table 1. Incidence of affection of paranasal sinuses by various lesions**

Nature of Lesions	No. of patients
Neoplasm	12
Inflammatory	43
Trauma	5
Total	60



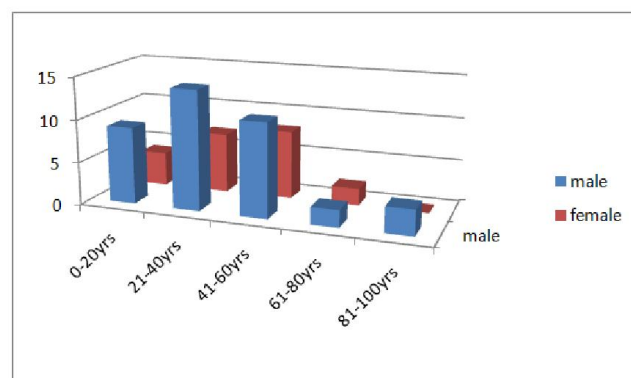
**Table 2. Sex Incidence**

Total No. of Patients	Male	Female
60	39	21

- Paranasal sinuses were more commonly affected in males than females.

**Table 3. Age Group and Sex Distribution**

Age group of patients	Male	Female	Total
0 – 20 years	9	4	13
21 – 40 years	14	7	21
41 – 60 years	11	8	19
61 – 80 years	2	2	4
81 – 100 years	3	0	3
Total	39	21	60



- Number of male patients outnumbered female patients in all age groups.
- The incidence of involvement of paranasal sinuses was maximum in 21- 40 years age group.

**Table 4. Incidence of various causes of paranasal sinus Involvement in various age groups**

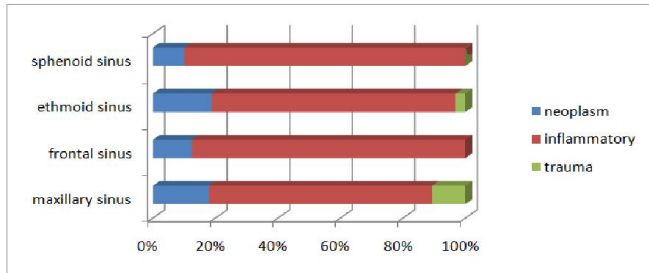
Age group of patients	Trauma		Inflammatory		Neoplasm		Total
	M	F	M	F	M	F	
0-20 years	1	0	6	1	2	2	12
21-40 years	1	1	9	7	4	0	22
41-60 years	0	1	11	5	3	0	20
61-80 years	0	0	2	1	0	0	3
81-100 years	1	0	1	0	1	0	3
Total	3	2	29	14	10	2	60

It was concluded that incidence of neoplasm was slightly higher in age groups of 21-40 years than 41-60 years.

- Patients with inflammatory conditions were commoner in age group of 21-60 years.
- Incidence of trauma was more frequently reported in age group of 21-40 years.

**Table 5. Incidence of paranasal sinus involvement by various causes**

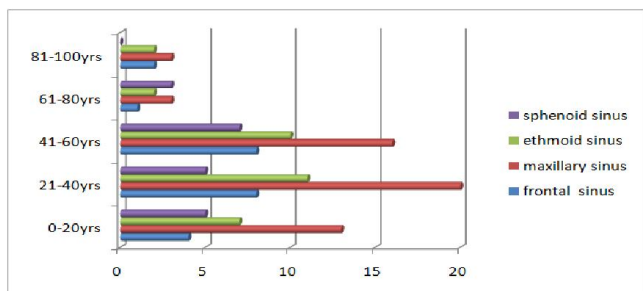
	Maxillary sinus	Frontal Sinus	Ethmoidal sinus	Sphenoid Sinus
Neoplasm	10	3	6	2
Inflammatory	40	21	25	18
Trauma	6	0	1	0



- Incidence of neoplasm was commonest in maxillary sinuses followed by ethmoid sinuses, frontal sinuses and sphenoid sinuses respectively.
- Incidence of inflammatory conditions was also commonest in maxillary sinuses followed by ethmoid sinuses.
- Incidence of trauma was also commonest in maxillary sinuses followed by ethmoid sinuses. So overall maxillary sinus was most commonly affected by diseases.

**Table 6. Incidence of type of paranasal sinuses in various age groups involved**

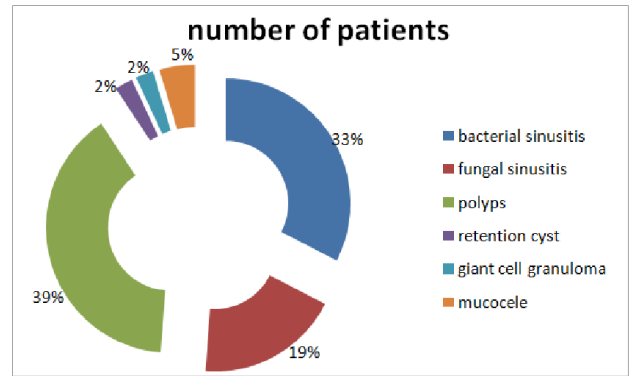
Age Group of patients	Frontal Sinuses	Maxillary Sinuses	Ethmoidal sinus	Sphenoid Sinus
0-20 years	4	13	7	5
21-40 years	8	20	11	5
41-60 years	8	16	10	7
61-80 years	1	3	2	3
81-100 years	2	3	2	0



- In all age groups, maxillary sinuses were most commonly involved followed by ethmoid and frontal sinuses.

**Table 7. Incidence of various inflammatory conditions**

Type of inflammatory conditions	No. of Patients
Bacterial Sinusitis	14
Fungal Sinusitis	8
Polyps	17
Retention cyst	1
Giant Cell Granuloma	1
Mucocele	2



- Incidence of polyps (41%) was highest followed by bacterial sinusitis (32%), fungal sinusitis (18%), mucocele and retention cyst respectively. A single case of biopsy proved giant cell granuloma involving maxillary, frontal and ethmoidal sinus was studied. Among all bacterial sinusitis pansinusitis was found in 5 patients involving all the sinuses.
- Out of 43 inflammatory conditions 18 cases were polyps (41%). Of these 18 cases 10 patients had h/o allergy ie 55% of cases associated with allergy.
- Staikuniene, Vaitkus *et al.* studied 121 patients, of these nasal polyps were detected in 84 patients (69.4%), asthma diagnosed in 48 patients (39.6%), associated with nasal polyps (91.7%) and allergic rhinitis in 45.5% of patients (Staikuniene and Vaitkus S Medicina, 2008)
- MDCT is the technique of choice in the preoperative evaluation of the nose and paranasal sinuses and is the gold standard for delineation of inflammatory sinus disease resulting from obstruction (Duvoisin *et al.*, 1991)
- In our study out of 21 cases sinusitis diagnosed by MDCT, 19 were true positive and 2 were false negative. So overall sensitivity of MDCT in diagnosis of sinusitis is 90% and positive predictive value of 90.4%
- Bhattacharya N. and Fried M.P. conducted a study of 2 groups of patients (171 and 130) compared with histopathological reports. According to this study CT exhibited sensitivity of 94%. Increasing the cut-off value to 4 changed the sensitivity to 85%. (Bhattacharya and Fried, 2003)
- Hagtvedt, Alokken *et al.* conducted study of acute sinusitis by C.T. scan showed that The overall sensitivity of low-dose CT was 95%. (Tidsskr Nor Laegeforen, 2003)

**Table 8. Incidence of various ct characteristics in cases with Inflammatory conditions affecting para nasal sinuses**

CT findings	No. of Patients
Heterogenous enhancement	6
Local spread (Orbital / cheek extension)	5
Extension to nasal cavity	14
Bony changes (erosion or sclerosis)	6

- 6 cases of probable fungal sinusitis showed heterogenous contrast enhancement with 6 out of 8 cases of fungal sinusitis showed bony changes.
- 5 cases had local spread, involving either orbit or cheek. Among the inflammatory conditions, fungal sinusitis most frequently showed the local spread.
- Nasal cavity involvement among all inflammatory condition, more commonly seen with polyposis seen in 11 patients, 3 cases with fungal sinusitis.

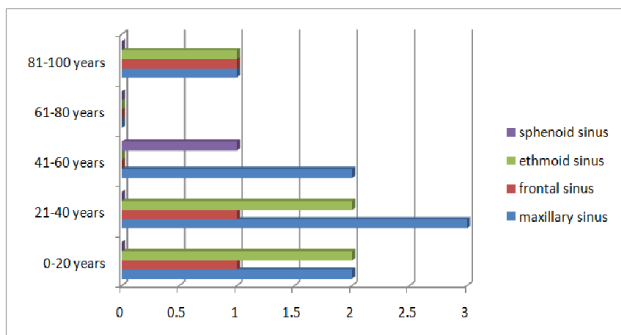
**Table 9. Incidence of various neoplastic conditions Affecting para nasal sinuses**

Neoplasm	No. of Patients	
Benign	Osteo	3
	Fibrous dysplasia	3
	Ossifying fibroma	2
Malignant	Leukemic infiltrations	1
	Sinonasal malignancy	2
	Metastasis	1

- 12 cases of various neoplastic lesions were studied. 1 case of ethmoid sinus osteoma was taken. 3 cases of fibrous dysplasia involving primarily the frontal, ethmoid and maxillary sinuses with involvement of the orbital wall were studied. 2 cases of ossifying fibroma involving the maxillary sinus were studied and 2 cases of sinonasal malignancies of epithelial origin and 1 case leukemic infiltration involving B/L maxillary sinus and 1 case of direct metastasis of sphenoid sinus by nasopharyngeal ca were studied.

**Table 10. Incidence of types of paranasal sinus involvement in various age groups in cases of neoplasm (benign, malignant)**

Age Group of patients	Maxillary Sinus	Frontal Sinus	Ethmoidal sinus	Sphenoid Sinus
0-20 years	2	1	2	0
21-40 years	3	1	2	0
41-60 years	2	0	0	1
61-80 years	0	0	0	0
81-100 years	1	1	1	0



- Incidence of neoplastic involvement was highest in the age group of 21-40 years followed by 10-20 years age group.
- In all age groups incidence of maxillary sinus involvement was highest followed by ethmoid sinuses.
- Sphenoid sinus was least commonly affected.
- Lebnerdt *et al.* in March 2001 conducted a study to assess clinical and radiological differentiation between chronic sinusitis and differential pathologies such as malignancy, inverted papilloma, or mycosis. They conducted a prospective study and included all patients who had a unilateral opacification of the paranasal sinuses.

**Table 11. Incidence of local extension and bony changes in neoplastic lesions of paranasal sinuses**

Local Extension of Malignant SOL	No. of Patients
Orbit / cheek	4
Nasal Cavity	5
Intra Cranial extension	0
Bone involvement	6

It was concluded that unilateral opacification of paranasal sinuses in MDCT or MRI is especially at a higher age, an incidence for a neoplasm or mycotic sinusitis and therefore an early histological diagnosis or operative treatment is always suggested. (Lehnerdt *et al.*, 2001)

- Jurkiewicz D, Wojdas, A, Hermanowski M *et al* studied 113 patients out of these 69% males, 31 females showed sinonasal malignancy of epithelial origin. In 82% cases over 72% in advanced stage (T<sub>3</sub> and T<sub>4</sub>) (Juskiewicz *et al.*, 2007)
- In our study, out of the 2 male patients (of age group 50-80 years) had malignant involvement of paranasal sinuses both cases showed spread to orbit/cheek with no Intra cranial extension was seen.
- In our study Sensitivity of MDCT in diagnosis of sinonasal malignancy was 100% because of limited available sample size.
- 6 patients of neoplastic lesions showed bone involvement in the form erosion or sclerotic changes. Out of these, 2 cases of Ca, 2 cases of ossifying fibroma and 1 case of mets showed bony erosions.
- Chen, Hsu *et al.* showed that MDCT is superior in revealing bone erosion, particularly in the region of the cribriform plate, orbit, pterygopalatine fossae, and infratemporal fossae. Intracranial extension can also be detected as dural enhancement after the administration of contrast material (Chen *et al.*, 2002).

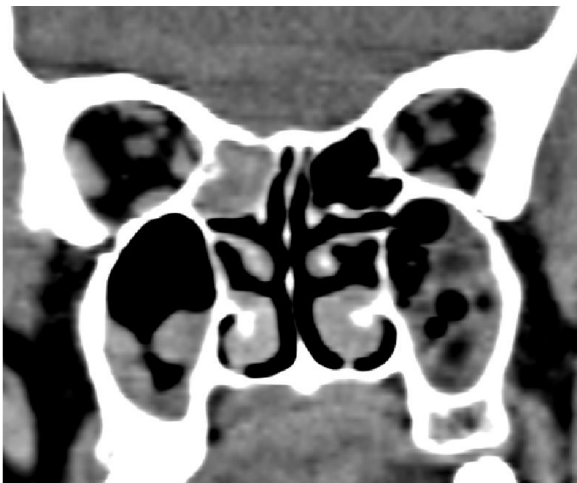**Table 12. Incidence of different clinical presentations of patients with malignant conditions**

Clinical Features	No. of Patients
Headache	1
Nasal blockage	5
Nasal discharge	4
Nasal bleeding	3
Pain over sinus	6
Local swelling	7

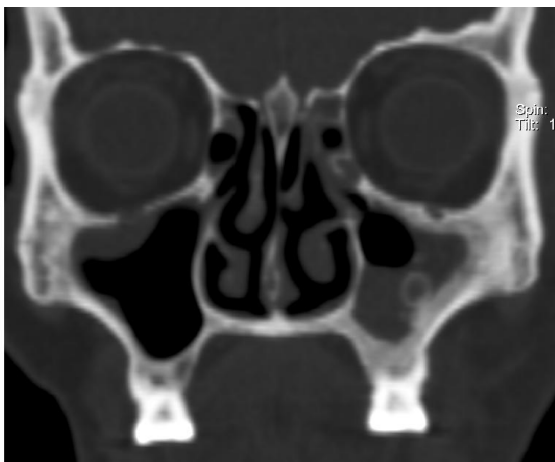
- Localized swelling and edema are the involved paranasal sinus was the commonest clinical feature present in 54% of the patients, followed by pain.
- Complaints of patients with sinonasal tumors include diplopia, proptosis, nasal stuffiness, anosmia, epistaxis, facial mass. Patients with antral and ethmoidal cancers have an average delay of 6 months between the onset of symptoms and establishment of a clinical diagnosis. (Harrison 1971)
- M.D.C.T was helpful in evaluating critical areas of P.N.S. such as
- Anterior and posterior osteomeatal units, cribriform plate, olfactory fossa
- Relation between optic nerve, internal carotid artery and sphenoid sinuses, which helped in planning and evaluation before FESS.

### Conclusion

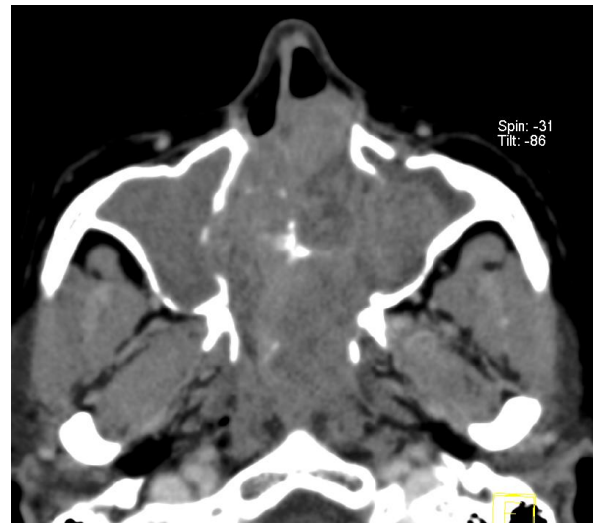
Out of 60 cases, 12 cases were of neoplastic involvement, 43 cases were of inflammatory conditions and 5 cases were of trauma. Neoplastic involvement of paranasal sinuses was slightly higher in 21-40 years than 41-60 years age distribution.



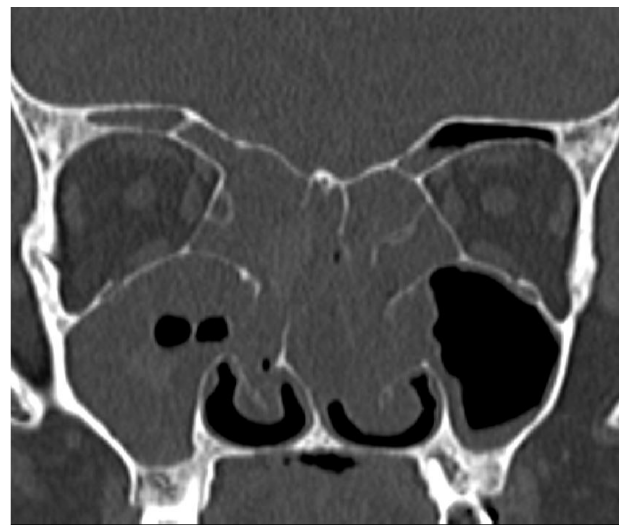Case no 9- LT SIDE MAXILLARY SINUSITIS



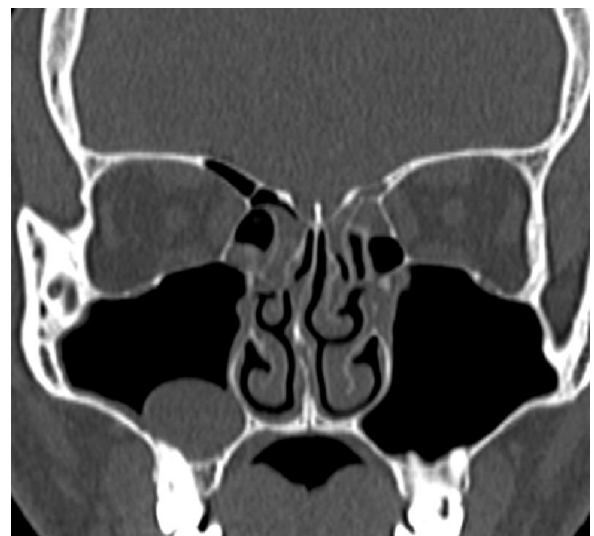
Case no 32- CHRONIC SINUSITIS



Case no 22- BONY CHANGES IN CHRONIC SINUSITIS

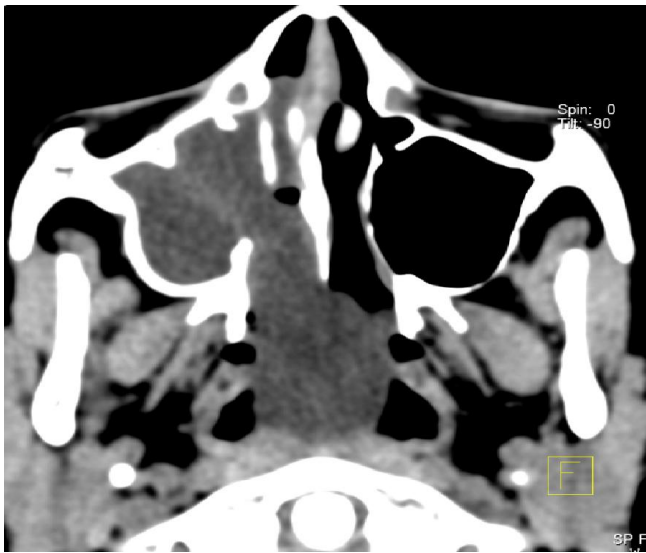


Case no2 -FUNGAL SINUSITIS

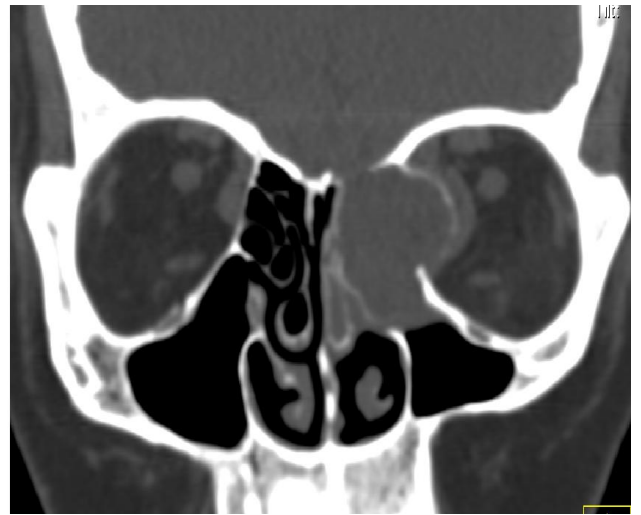

Case no1-SINONASAL POLYPOSIS

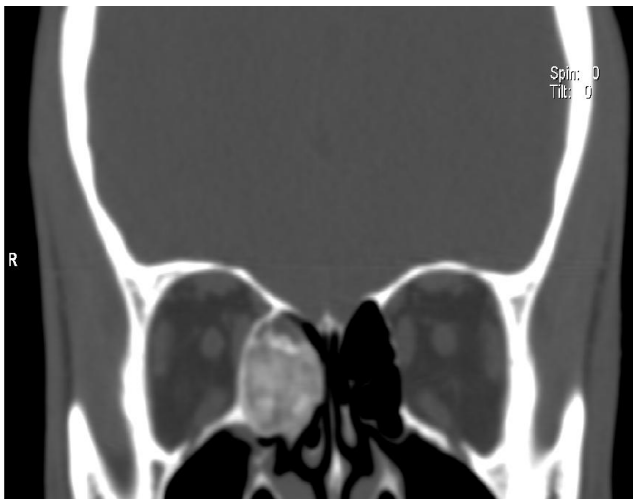



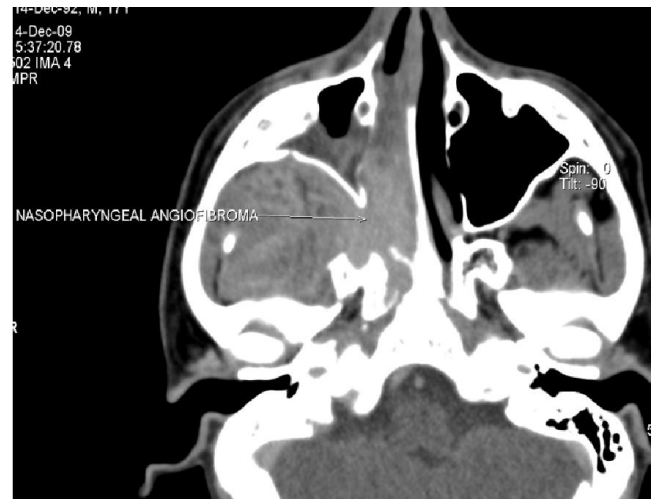
Case no 48-POLYP IN RT MAXILLARY SINUS



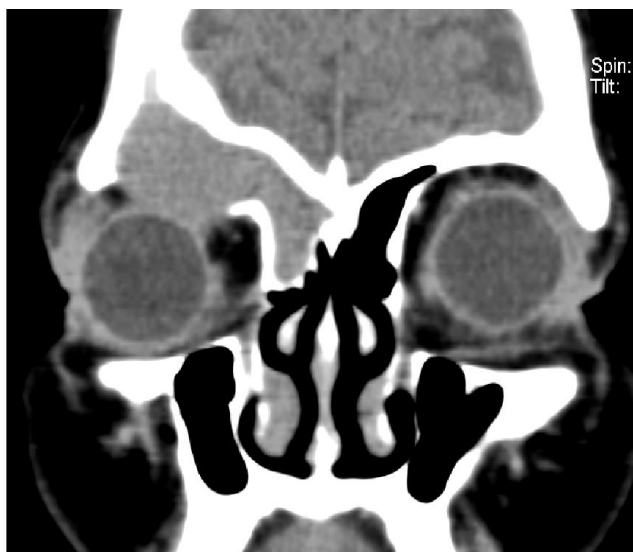Case no 35- MUCOCELE IN RT FRONTAL SINUS WITH EXTENSION INTO RT ORBIT



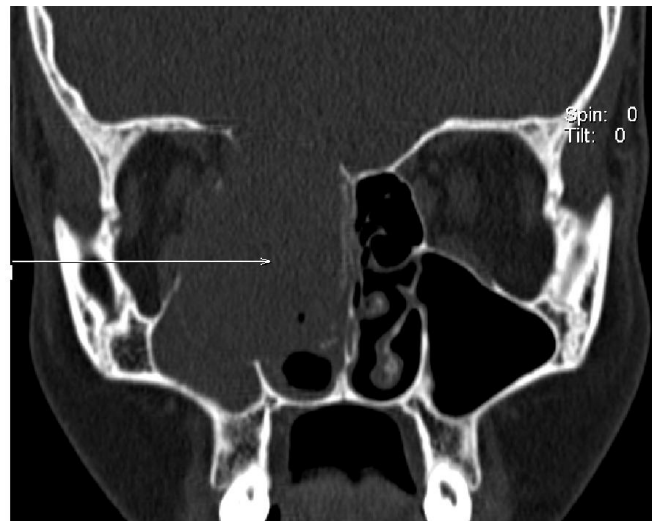
Case no 33- RT SIDE ANTROCHOANAL POLYP



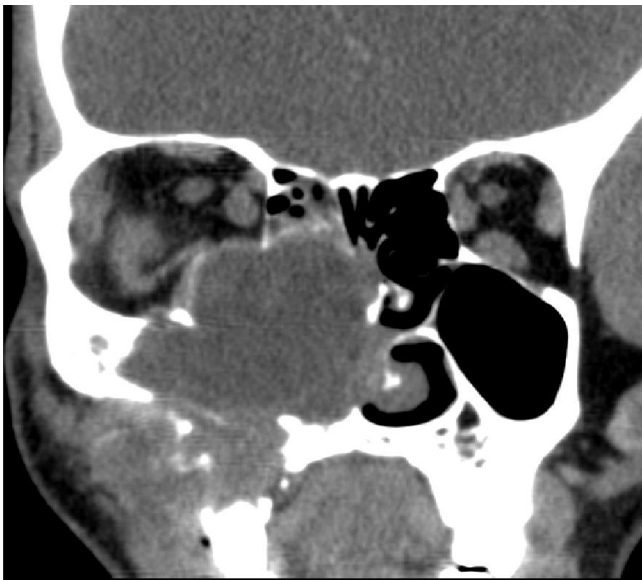Case no 31- LT ETHMOIDAL MUCOCELE



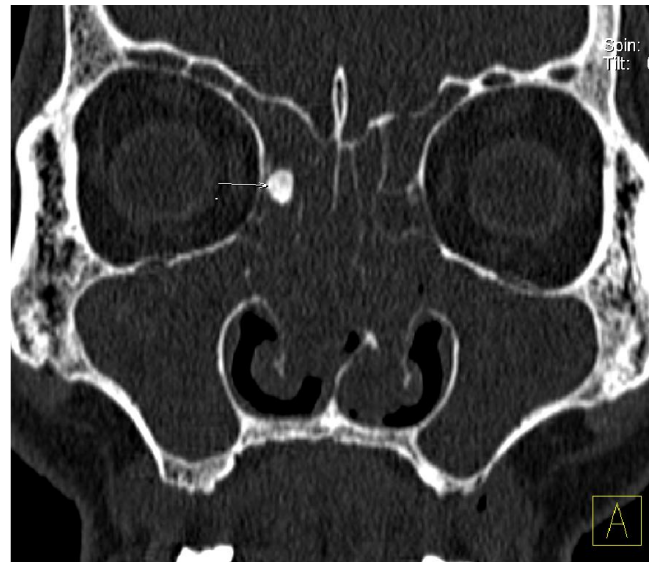
Case no 36- FIBROUS DYSPLASIA OF RT ETHMOID SINUS



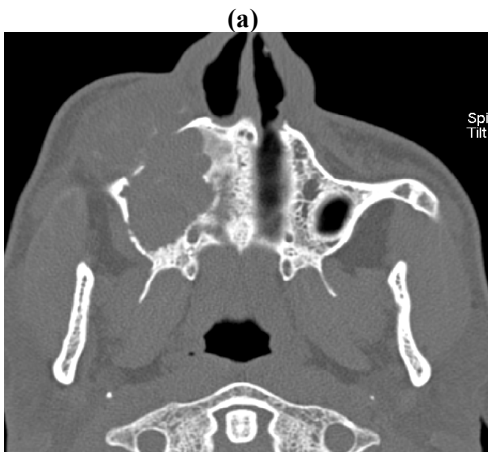
Case no 27- RT NASOPHARYNGEAL ANGIOFIBROMA



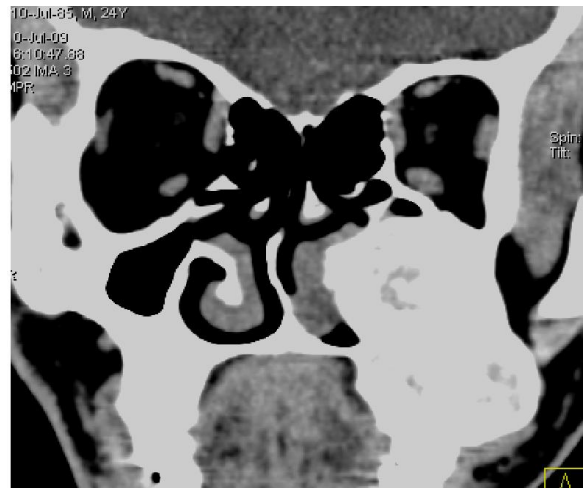Case no 37 – GIANT CELL REPAIRATIVE TUMOUR



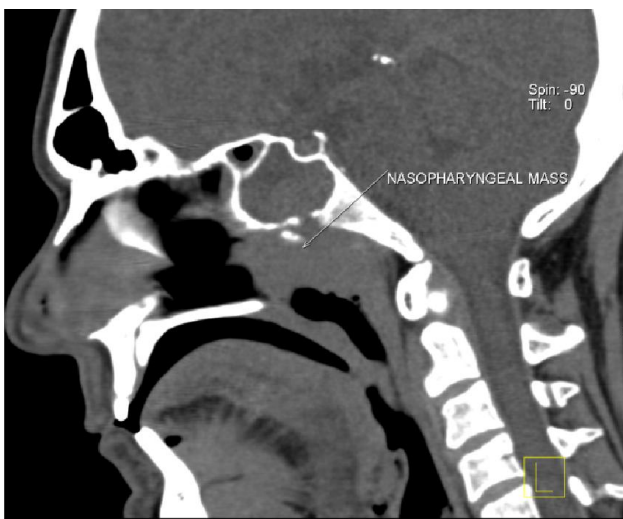
Case no 17-OSTEOMA OF RT ETHMOID SINUS WITH POLYPOSIS



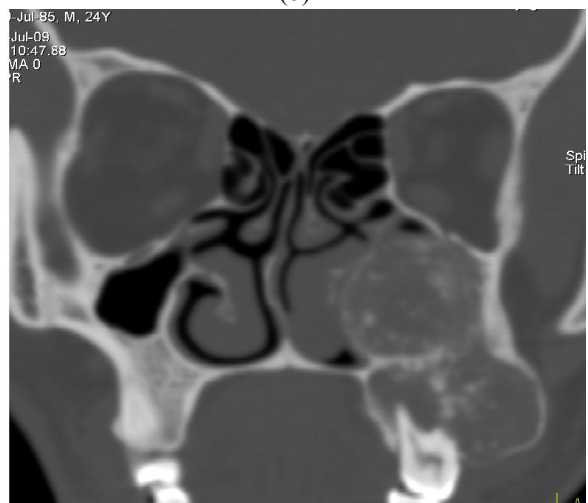(B),EROSION OF BONY WALL OF RT. MAX SINUS  
Case no 29- CARCINOMA RT MAXILLARY SINUS



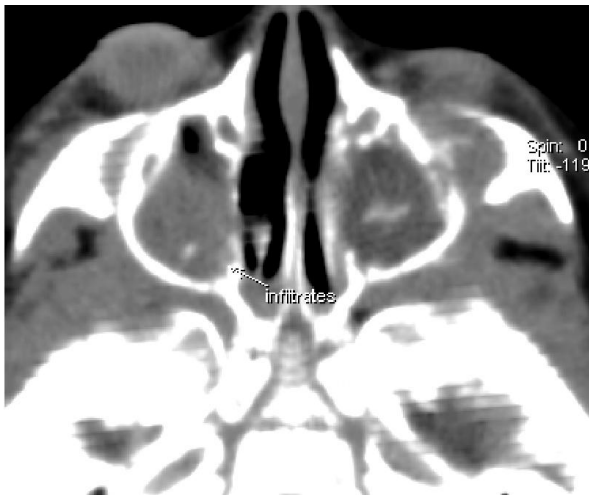(b)



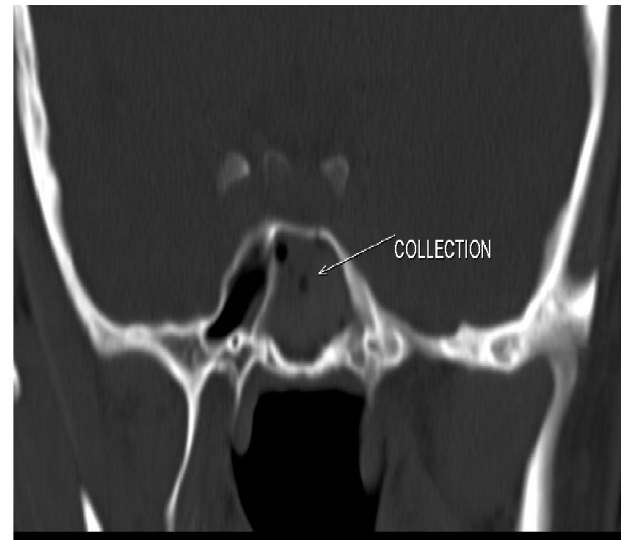Case no-40- NASO\_PHX\_MASS INVOLVING SPHENOID SINUS



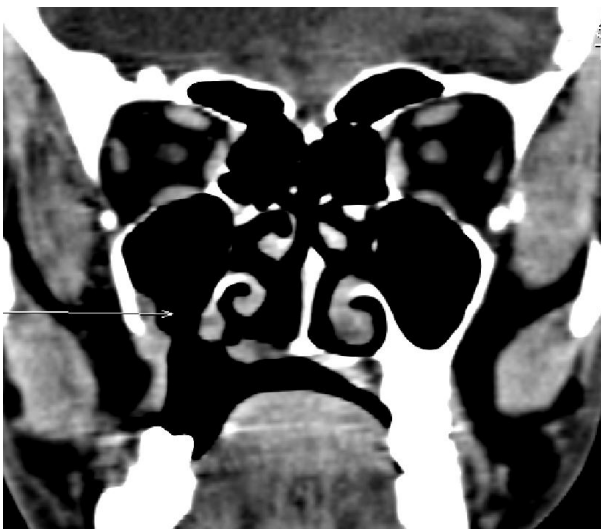Case no 38-OSSIFYING FIBROMA INVOLVING LT MAXILLARY SINUS



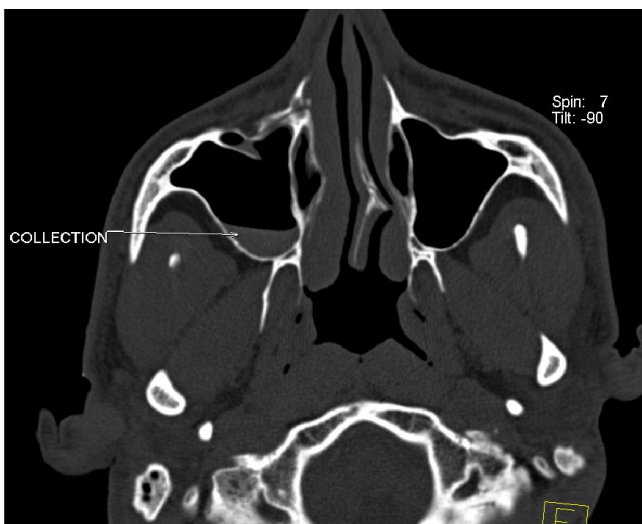
**Case no 45- LEUKEMIC INFILTRATES IN B/L MAX SINUSES**



**Case no 57- COLLECTION WITH FRACTURE ROOF OF SPHENOID SINUS**



**Case no 41-OROANTRAL FISTULA**



**Case no-52 COLLECTION WITH FRACTURE ANTERIOR WALL OF RT MAX SINUS**

Most commonly involved paranasal sinus was the maxillary sinus followed by ethmoid sinuses, frontal and sphenoid sinuses respectively. Local extension was noted in 5 of the cases which helped in the accurate preoperative assessment. So MDCT is the procedure of choice in evaluation of malignant tumors because accurate assessment of size and extent determined operability. Sensitivity of detection of sinonasal malignancy was 100% by MDCT because of limited available sample size

Lesions inaccessible by conventional radiography could be easily studied by MDCT planning. This helped in the early diagnosis and thus improved the prognosis of these patients. Sensitivity of MDCT in diagnosing sinusitis was 90% and positive predictive value of 90.4%. Sinonasal polyps showed association with allergy in 55% of cases. Axial and coronal sections with 3D reconstruction images, in cases of trauma helped in delineating the fractures involving the paranasal sinuses and in planning the maxillofacial surgery of such patients.

M.D.C.T was helpful in evaluating critical areas of P.N.S. such as anterior and posterior osteomeatal units, cribriform plate, olfactory fossa, relation between optic nerve, internal carotid artery and sphenoid sinuses which helped in planning and evaluation before FESS

M.D.C.T is superior compared to older conventional CT scan because of High resolution:nature of lesion, bony changes and extension of lesions are better appreciated. Superior in tumor staging and in assessment of metastatic lymphadenopathy. Better evaluation of anatomical variations secondarily affecting the sinuses. Speed of scanning: scan is completed in few seconds, reduces the motion artifacts and helpful in traumatic and serious patients. Fast reconstruction of coronal, sagittal and 3D images: imaging in different planes and higher radiation can be avoided. 3D bony images: in delineating extension of fracture, helps in planning maxillofacial surgeries.



MDCT is superior over MRI in detecting calcification, bony changes and haemorrhage within the lesion, however difficulty in differentiating between malignancy and chronic inflammation such as fungal sinusitis, radiation exposure and contrast allergy are the causes of its limitation, where the MRI has its own advantages and also contrast-enhanced MRI is superior in demonstrating an intracranial tumor margin and dural disease, as well as any intracranial complications of sinusitis such as meningitis, cerebritis, intracranial abscess, and orbital complications.

## REFERENCES

- Bhattacharya, N. and Fried, M.P. 2003. Laryngoscope Jan;113(1):125-9.
- Chen, C.C., Hsu, L., Hecht, J.L. and Janecka, I. Bimaxillary chondrosarcoma: clinical, radiologic, and histologic correlation. *AJNR*, 2002; 23:667-670
- Duvoisin, B., Landry, M., Chapuis, L., Krayenbuhl, M., Schnyder, P. 1991. Low-dose CT an inflammatory disease of the paranasal sinuses. *Neuroradiology*, 33:403-406
- Harrison, D.F.N. 1971. Management of malignant tumors of the paranasal sinuses *Otolaryngeal Clin. North Am.*, 4: 159-177.
- Juskiewicz, D., Wojdas *et al.* 2007. Malignant sinonasal tumours, *Otolaryngology*, 61(4):572-5.
- Lehnerdt, G., Weber, J. and Dost, P. 2001. Unilateral opacification of paranasal sinuses in CT or MRI : an indication of an uncommon histological finding. *Laryngohinootologic March*; 80(3); 141-145.
- Staikuniene, Vaitkus, S. *Medicina (Kaunas)*. 2008. 44(4):257-65.
- Tidsskr Nor Laegeforen. 2003. Dec 4;123(23):3362-4

\*\*\*\*\*