



RESEARCH ARTICLE

RESULTS OF WINDOW SHADE GRAFTING IN TYMPANOPLASTY FOR PERFORATIONS WITH NARROW ANTERIOR MARGIN

Dr. Ninad S. Gaikwad, *Dr. Nilam U. Sathe, Dr. Rumita Ghosh, Dr. Rumita Ghosh
and Dr. Dhanashree Chiplunkar,

Dept of ENT and Head – Neck Surgery, Seth G. S. Medical College and KEM Hospital, Parel,
Mumbai-400 012, India

ARTICLE INFO

Article History:

Received 05th October, 2015
Received in revised form
26th November, 2015
Accepted 11th December, 2015
Published online 31st January, 2016

Key words:

Window shade grafting;
Tympanoplasty.

Copyright © 2016 Dr. Ninad S. Gaikwad et al. This is an open access article distributed under the Creative Commons Attribution License, which permits unrestricted use, distribution, and reproduction in any medium, provided the original work is properly cited.

Citation: Dr. Ninad S. Gaikwad, Dr. Nilam U. Sathe, Dr. Rumita Ghosh, Dr. Rumita Ghosh and Dr. Dhanashree Chiplunkar, 2016. "Results of window shade grafting in tympanoplasty for perforations with narrow anterior margin", *International Journal of Current Research*, 8, (01), 25640-25643.

ABSTRACT

Introduction: Among the many other techniques employed, window shade grafting was first described by Calcaterra in 1972². We present our experience and results using this technique of tympanic membrane grafting in perforations with narrow anterior rim.

Materials and Methods: The study was conducted from 2004 to 2007. A total of 35 patients of chronic suppurative otitis media (tubotympanic type) with a perforation with narrow anterior rim were included in the study. 15 (42.8%) patients were male and 20 (57.1%) were female. The youngest patient was 9 years old and the oldest was 52 years, the mean age being 25.7 years.

Conclusion: Tympanoplasty in a perforation with a narrow anterior rim has a poor result than posterior perforations primarily because of an inadequate scaffolding for the graft. Window shade tympanoplasty, therefore, gives good results in perforations with a narrow anterior rim with respect to graft take up rates as well as hearing results.

INTRODUCTION

Underlay and overlay techniques of tympanic membrane grafting in tympanoplasty have been extensively documented in literature. There have been numerous modifications of these two techniques over the years with varying success rates. Almost all have been developed to overcome the shortcomings of the general techniques in dealing with certain specific situations. A narrow anterior rim in a central tympanic membrane perforation is one such situation. The overlay technique has been traditionally used to tackle this condition, but the results, mainly on account of anterior angle blunting and hearing improvement (Glasscock *et al.*, 1973) have been largely unsatisfactory. Among the many other techniques employed, window shade grafting was first described by Calcaterra in 1972 (Calcaterra, 1972). We present our experience and results using this technique of tympanic membrane grafting in perforations with narrow anterior rim.

*Corresponding author: Dr. Nilam U. Sathe,
Dept. of ENT and Head – Neck Surgery, Seth G. S. Medical College
and KEM Hospital, Parel, Mumbai-400 012, India.

MATERIALS AND METHODS

The study was conducted from 2004 to 2007. A total of 35 patients of chronic suppurative otitis media (tubotympanic type) with a perforation with narrow anterior rim were included in the study. 15 (42.8%) patients were male and 20 (57.1%) were female. The youngest patient was 9 years old and the oldest was 52 years, the mean age being 25.7 years (Table 1).

The most common complaint of the patients was otorrhoea in 29 (82.8%) patients, followed by hearing loss in 19 (54.28%), tinnitus in 16 (45.7%) and vertigo in 5 (14.3%). Of those having a history of otorrhoea, mucopurulent ear discharge was most common, being reported by 21 (60%) patients, followed by a dry ear in 8 (22.8%) patients, mucoid ear discharge in 4 (11.4%) and purulent discharge in 2 (5.7%) patients. The duration of disease was less than 5 years in 17 (48.6%) patients, while in 9 (25.7%) patients it was more than 10 years. The remaining 9 (25.7%) patients reported the duration of ear discharge to be between 5-10 years. The disease was left sided in 18 (51.4%) patients, right sided in 8 (22.8%) and bilateral in 9 (25.7%) individuals. The tympanic membrane perforation was central in 18 (51.4%), subtotal in 10 (28.6%) and total in 2

(5.7%). 4 (11.4%) patients had an anteriorly placed perforation and 3 (8.6%) had an atelectatic tympanic membrane. The diseased ears were dry for at least 3 weeks pre-operatively. All patients underwent a pre-operative pure tone audiogram, and only those with purely conductive hearing loss were included in the study. The hearing level was assessed by calculating the mean of the hearing level at 500 Hz, 1 kHz and 2 kHz. Hearing loss was classified as minimal (hearing level 16 to 25dB), mild (26 to 40dB), moderate (41 to 55dB) and moderately severe (56 to 70dB). Hearing loss above that was not observed in our study (table II).

Surgical Technique

32 patients were operated under local anaesthesia with 2% lignocaine with 1: 2,00,000 adrenaline. General anaesthesia was used for only 3 patients. A standard postaural incision was taken and the temporalis fascia graft was harvested. The periosteum over the mastoid bone was elevated and the external auditory meatus was entered by a posterior meatotomy. The perforation margins were freshened and the tympanomeatal flap was raised (Fig 1). The annulus was elevated and the middle ear was entered (Fig 2). Ossicular mobility and continuity and the status of the middle ear was assessed. No patient included in the study required ossicular reconstruction. The external auditory canal skin is then elevated anteriorly from the annular groove with a circular knife from 6'o clock to 3'o clock and then 3'o clock to 12'o clock position. The skin is elevated in a medial to lateral position for about 0.5 to 1cm (Fig 3 & Fig 4). A slit is made in the superior part of the temporalis fascia to accommodate the handle of malleus. The temporalis fascia graft is then placed by the underlay technique, under the handle of malleus and is tucked under the raised EAC flap anteriorly (Fig 6).

The anterior EAC skin flap is then replaced over the graft (Fig 7), thus creating a double layer of tympanic membrane similar to Shouldice's repair of hernia. The tymano-meatal flap is then repositioned posteriorly as well. Gel foam is kept in the middle ear and EAC to support the graft (Fig 5 & 8). The wound is finally closed in layers and a mastoid dressing applied. Post-operatively, the patients were put on oral antibiotics, antihistaminics and topical nasal decongestants. The antibiotics and topical nasal decongestants were continued for one week and antihistaminics for 3 weeks. The skin sutures were removed after 7 days. All patients were followed up for one year. Post operative audiometry was done after 6 weeks. The status of the graft, neotympanum and anterior angle blunting were observed.

RESULTS AND ANALYSIS

The graft uptake was first assessed at 3 weeks. It was well taken up in 34 (97.1%) cases. At 3 months, one patient developed a recurrence of tympanic membrane perforation. The tympanic membrane grafting was, therefore, successful in 33 (94%) cases. The first patient in whom graft failed had a pre-operative total perforation with a hypertrophic mucosa and granulations, whereas the second patient had a subtotal perforation with hypertrophic mucosa. Both the patients were adults. None of the operated ears developed anterior angle blunting. The perforation site and graft result is detailed in table III. Post operative hearing results were recorded at 6 weeks after surgery. They were classified as excellent for air-bone gap reduced to 0-10db, good for air-bone gap between 10-20db, fair for 20-30db and poor more than 30db. 16 (45.7%) patients had good hearing results, 14 (40%) had excellent results and 5 (14.3%) had fair result (table IV). No patient had a poor result. There was no significant change in bone conduction in any of the patients.

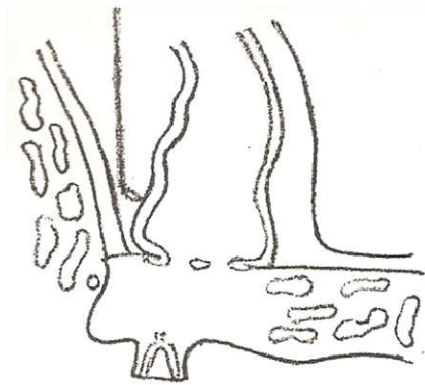


Fig. 1. Elevation of Posterior EAC Flap

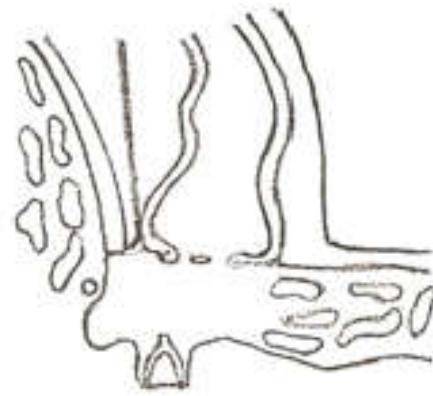


Fig. 2. Elevation of Posterior Annulus

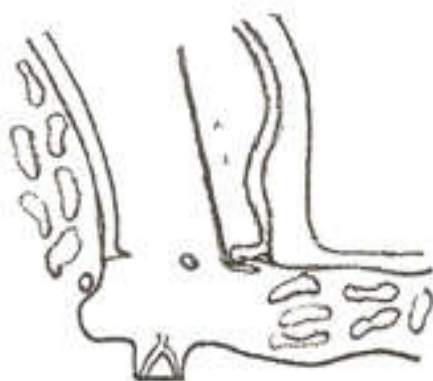


Fig. 3. Elevation of Anterior EAC Wall Flap from Annular Groove

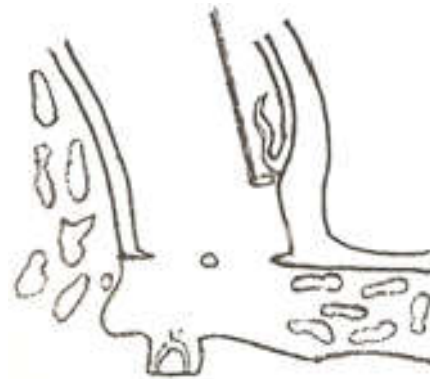


Fig. 4. Further Elevation of Anterior EAC Wall Flap

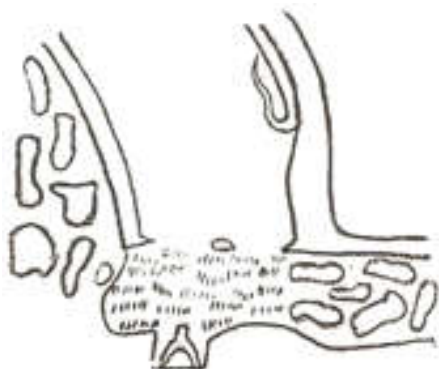

Fig. 5. Gel Foam filled in Middle Ear Space

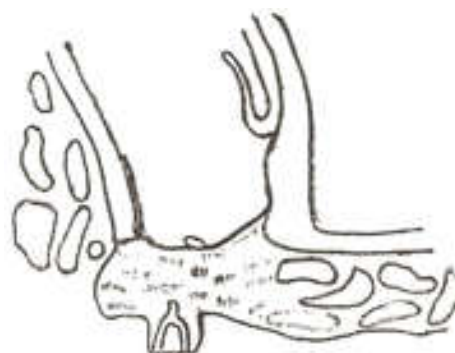


Fig. 6. Graft Placed in Position

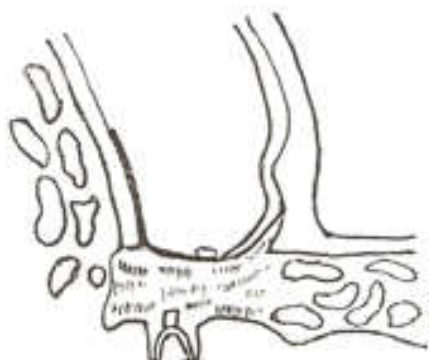


Fig. 8. Posterior EAC Flap Revisited and EAC filled with Gel Foam

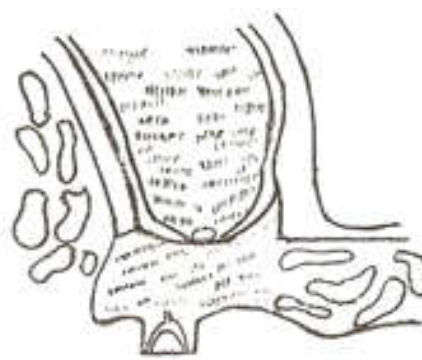


Fig. 7. Anterior EAC Flap Revisited over Graft

Table 1.

Age of Patients	No. of patients
0-10	1(2.8%)
10-20	12 (34.3%)
20-30	16 (45.7%)
30-40	4 (11.4%)
>40	2 (5.7%)

Table 2.

Classification of hearing loss	Pre op Hearing Loss
Minimal	4 (11.4%)
Mild	21 (60%)
Moderate	8 (22.8%)
Moderately- Severe	2 (5.7%)

Table 3.

Site/Size of Perforation	Graft Taken up at 1 year	Graft Failure at 1 year	Total
Atelectatic	2	0	2
Anterior	3	0	3
Central	18	0	18
Subtotal	9	1	10
Total	1	1	2

Table 4.

Post op Hearing Result (air-bone gap)	Number of patients
Excellent (0-10db)	14 (40%)
Good (10-20db)	16 (45.7%)
Fair (20-30db)	5 (14.3%)
Poor (>30dB)	0

Table 5.

Pre-operative hearing loss	Postoperative hearing status				Total no. of Patients
	Excellent	Good	Fair	Poor	
Minimal	2 (50%)	1 (25%)	1 (25%)	0	4
Mild	7 (33.3%)	12 (57.1%)	2 (9.5%)	0	21
Moderate	4 (50%)	2 (25%)	2 (25%)	0	8
Moderately severe	0	1 (50%)	1 (50%)	0	2

The post operative hearing result with respect to pre-operative hearing status (including patients with graft failure) is given in table V below:

DISCUSSION

Double breasting implies surgical overlapping of tissues to provide additional strength for repair of defects in tissue integrity. A popular example is Shouldice's hernioplasty, where the two ends of fascia transversalis are overlapped over each other to decrease the surface area and to increase the tensile strength of the posterior wall of anterior abdominal wall. The objective is to prevent recurrence. Double breasting techniques in tympanoplasty are used for placement of graft in large, subtotal, total or anteriorly placed tympanic membrane perforations where the anterior rim of the perforation is too narrow to support the graft medial to it.

Failure to secure the graft in such a situation leads to graft separation and residual or recurrent anterior perforation. According to a study by Cable³, for a given overlap, the pressure required to overcome the surface tension decreases as the perforation size increases, i.e. the larger the perforation size, the greater the overlap required to resist a given pressure on the graft before leakage occurs. Prolapse of the graft through the perforation occurs if the overlap is insufficient. The overlap by double breasting technique is 3-4 mm. This reduces the graft failure rates, residual perforation and lateralization of graft as compared to traditional methods of myringoplasty. Perforations >50% of the surface area had poor uptake rates (Albu et al., 1998; Jurovitzki et al., 1988; Jurovitzki et al., 1973) than smaller perforations. Sade (1981) showed that larger perforations with or without annulus or anterior perforations without adequate rim of tympanic membrane have resulted in unsatisfactory results with frequent residual perforations. Window shade tympanoplasty was first performed by Calcaterra (Calcaterra, 1972) in 1972 in an attempt to manage such a perforation successfully. His technique was further modified by Schraff et al. (2005) in 2005. Both reported a low rate of recurrence.

Numerous other techniques for grafting for perforations with thin anterior margin have been described in literature. Overlay grafting is one of the traditional methods of grafting a perforation with a narrow anterior rim. However, anterior angle blunting is very common with this technique. Glasscock (Glasscock, 1973), found blunting of the anterior sulcus as the most frustrating aspect of overlay technique that could affect vibrating qualities of the new drum and in some cases, immobilize the malleus handle and lead to poor hearing gain. Kerr flap (Primrose et al., 1986), is among the more popular techniques of double breasting. The incidence of anterior angle blunting with this technique is negligible. In cartilage shield tympanoplasty, the entire tympanic membrane is replaced by cartilage. Hearing results with this technique are a matter of concern (Aidonis et al., 2005). In medio-lateral graft tympanoplasty (Jung et al., 2009), there was a 97% success rate as compared to a 96% success rate in medial graft tympanoplasty.

The major expected complication of double breasting techniques is anterior angle blunting. It has been observed to result in decreased hearing gain. Kerr and Primrose reported no anterior angle blunting in their experience with Kerr flap as did (Sharp et al., 1992). In our study, attempts were made to minimize the effects of anterior angle blunting by 1) avoiding excessive fascia in the anterior tympanomeatal angle, 2) replacing the canal skin over the fascia for just 2-3 mm and 3) canalplasty in all cases of anterior wall overhang to be able to visualize the anterior angle. Hearing results were within 10dB in 14 patients, 20dB in 30 patients and within 30dB in all 35 patients.

Conclusion

Tympanoplasty in a perforation with a narrow anterior rim has a poor result than posterior perforations primarily because of an inadequate scaffolding for the graft. Window shade tympanoplasty, therefore, gives good results in perforations with a narrow anterior rim with respect to graft take up rates as well as hearing results.

REFERENCES

- Aidonis, I., Robertson, T.C., Sismanis, A. 2005. Cartilage shield tympanoplasty: a reliable technique. *Otol Neurotol.*, Sep; 26(5):838-41
- Albu, S., Babighian, G., Trabalzini, F. 1998. Prognostic factors in tympanoplasty. *Am J Otol.* Mar; 19(2):136-40
- Booth, J.B. 1973. Myringoplasty--factors affecting results. Final report. *J Laryngol. Otol.*, 87(11):1039-84.
- Cable, H.R., 1981. Surface tension and temporalis fascia grafts. *J Laryngol Otol.* Jul; 95(7):667-730
- Calcaterra, T.C. 1972. The window shade technique of tympanic membrane grafting. *Laryngoscope.* 82:45-49.
- Glasscock, M.E. 1973. 3rd. Tympanic membrane grafting with fascia: overlay vs. undersurface technique. *Laryngoscope.* May; 83(5):754-70.
- Jung, T., Kim, Y.H., Kim, Y.H., Park, S.K., Martin, D. 2009. Medial or medio-lateral graft tympanoplasty for repair of tympanic membrane perforation. *Int J Pediatr Otorhinolaryngol.* Jul; 73(7):941-3
- Jurovitzki, I., Sadé, J. 1988. Myringoplasty: long-term followup. *Am J Otol.*, Jan; 9(1):52-5.
- Primrose, W.J., Kerr, A.G. 1986. The anterior marginal perforation. *Clin Otolaryngol Allied Sci.* Jun; 11(3):175-6.
- Sadé, J., Berco, E., Brown, M., Weinberg, J., Avraham, S. Myringoplasty, 1981. Short and long-term results in a training program. *J Laryngol Otol.*, Jul;95(7):653-65
- Schraff, S., Dash, N., Strasnick, B. 2005. "Window shade" tympanoplasty for anterior marginal perforations. *Laryngoscope.* Sep; 115(9):1655-9.
- Sharp, J.F., Terzis, T.F., Robinson, J. 1992. Myringoplasty for the anterior perforation: experience with the Kerr flap. *J Laryngol Otol.*, Jan; 106(1):14-6.
