



## CASE REPORT

### DENTIGEROUS CYST ASSOCIATED WITH HORIZONTALLY IMPACTED MANDIBULAR SECOND PREMOLAR – A RARE CLINICAL ENTITY

\*<sup>1</sup>Dr. Sanjay Kumar Sinha, <sup>2</sup>Dr. Bimleshwar Kumar and <sup>3</sup>Dr. Birendra Prasad Gupta

<sup>1</sup>Government Dental College and Hospital, Patna, Private Practitioner

<sup>2</sup>Assistant Professor, Department of Oral and Maxillo-Facial Surgery, Dr. B.R. Ambedkar Dental College, Patna

<sup>3</sup>Government Dental College and Hospital, Patna, Private Practitioner

#### ARTICLE INFO

##### Article History:

Received 23<sup>rd</sup> February, 2016

Received in revised form

04<sup>th</sup> March, 2016

Accepted 26<sup>th</sup> April, 2016

Published online 10<sup>th</sup> May, 2016

##### Key words:

Cysts, Dentigerous cyst, Impaction, Odontogenic cyst, Tooth.

Copyright © 2016, Dr. Sanjay Kumar Sinha et al. This is an open access article distributed under the Creative Commons Attribution License, which permits unrestricted use, distribution, and reproduction in any medium, provided the original work is properly cited.

Citation: Dr. Sanjay Kumar Sinha, Dr. Bimleshwar Kumar and Dr. Birendra Prasad Gupta, 2016. "Dentigerous cyst associated with horizontally impacted mandibular second premolar – A rare clinical entity", *International Journal of Current Research*, 8, (05), 30801-30804.

#### ABSTRACT

Dentigerous cysts are benign odontogenic cysts that surrounds the crown of impacted, embedded, unerupted or developing tooth. These cysts are the second most common odontogenic cysts of the oral cavity after radicular cysts and they are most frequently associated with impacted mandibular third molars, less frequent with canines and maxillary third molars. but dentigerous cysts involving impacted second premolars are extremely rare occurrence. We hereby present a rare case of dentigerous cyst in fourteen year old male child associated with an unerupted/impacted mandibular second premolar which was successfully managed at our clinic.

## INTRODUCTION

Dentigerous cysts are benign odontogenic lesions arising from the completed crown of impacted, embedded or unerupted tooth (Larsen, 1993). They are the second most common type of odontogenic cysts, and the most common developmental cysts of the jaws. (Regezi *et al.*, 2008) They are caused by the accumulation of fluid between the crown and reduced enamel epithelium, attached at the cemento-enamel junction of an impacted or unerupted tooth. (Sumita *et al.*, 2006; Shah *et al.*, 2002) Dentigerous cysts may occur at any age group but the greatest incidence is in the second and third decade, Males are more likely to develop dentigerous cysts than females. (Shun, 2008; Shetty and Sandler, 2004) When such patients are examined, it will reveal missing tooth or teeth associated with noticeable swelling. Pathological fracture is also one of the complications if left untreated. Dentigerous cysts are tentatively diagnosed on routine dental radiographs. They are mostly associated with an impacted mandibular third molars and canines and also maxillary molars, but mandibular premolars have rarely been reported in the literature. This case report presents a rare case of a dentigerous cyst associated with an unerupted horizontally impacted mandibular second premolar in a fourteen year old child reported to our clinic.

## Case History

A male child aged 14 years reported to our clinic with chief complain of swelling and occasional pain in left side of lower jaw. On further enquiry, patient told us that he had noticed swelling about two month back, then patient was examined thoroughly. On extraoral examination- There was marked facial asymmetry (Fig.1) found in lower left side of jaw. There was obvious swelling noticed in lower left side of mandible., No other abnormalities were seen extraorally. On intraoral examination lower left second deciduous molar was found over retained even at the age of fourteen (Fig.2) and second premolar was missing, Swelling was fluctuant in nature, mild tender and was extending from left second molar to first premolar. There was no pus discharge from swelling. Overall patient had good oral hygiene. To diagnose this unidentified swelling patient was suggested to go for OPG X-ray, FNAC of the lesion, CBCT of left side of mandible and routine blood tests. XRAY OPG (Fig.3)revealed large radiolucent area below second deciduous molar and radiolucency was extending from mandibular first premolar to mesial root of first molar.X-ray OPG also suggested horizontally impacted second premolar near inferior border of mandible. CBCT (Fig. 4,5) of the patient was then examined, CBCT suggested well defined corticated,unilocular lytic lesion situated in left posterior mandible associated with left impacted second premolar.lesion

\*Corresponding author: Dr. Sanjay Kumar Sinha

Government Dental College and Hospital, Patna, Private Practitioner

was extending from mesial root of 36 to mesial aspect of 34. The lesion was measuring approx. 20.1mm x 20.9mm x 21.2mm in its latest dimension of mesio-distal, supero-inferior, and bucco-lingual. There was mild displacement of first premolar, margins of the lesion were thin and variably corticated, the mandibular canal was displaced inferiorly. Final impression was CBCT was dentigerous cyst with impacted premolar.

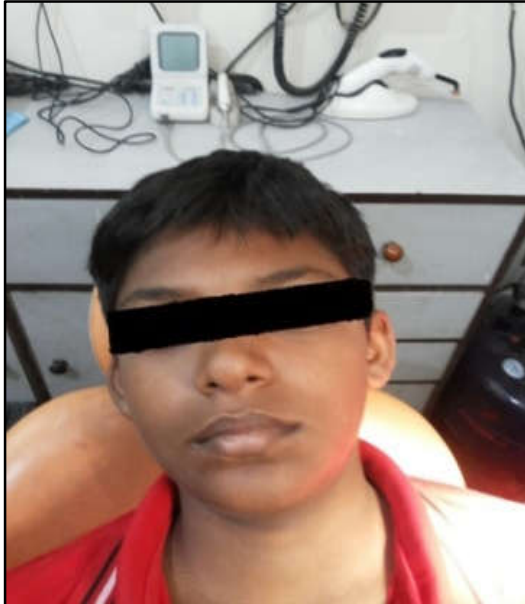

Fig. 1. Patient's frontal view

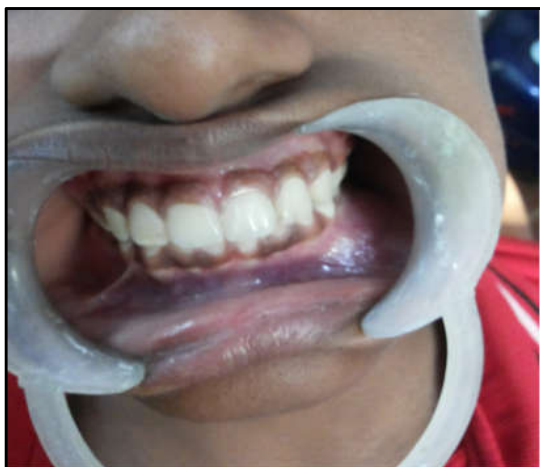

Fig. 2. Intraoral view

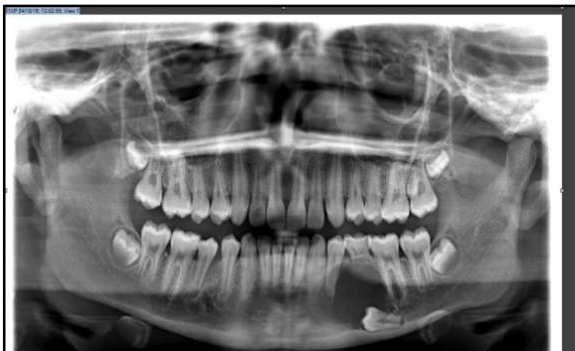

Fig. 3. Patient's OPG

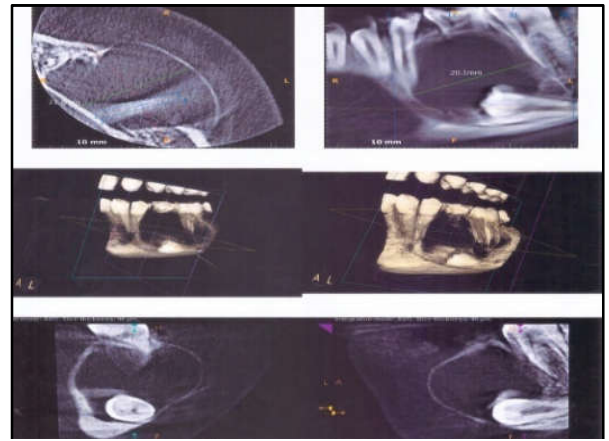


Fig. 4. CBCT of the patient

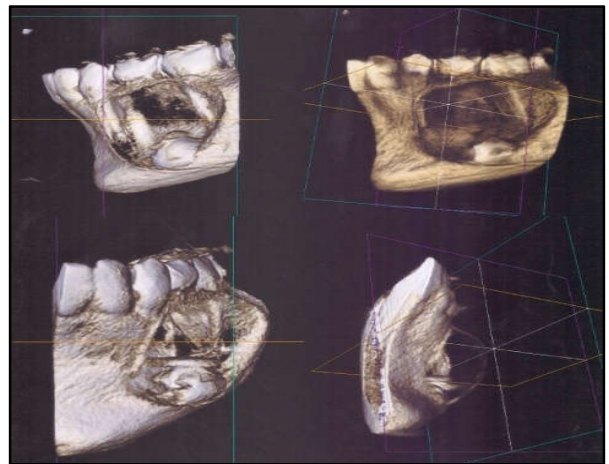


Fig. 5. CBCT of the patient

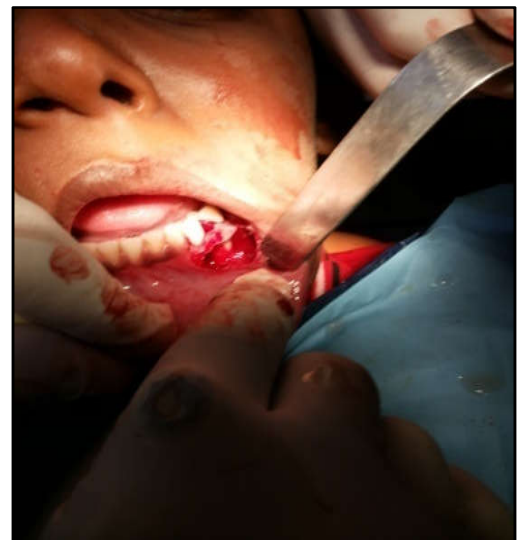


Fig. 6. Intraoperative view

Blood picture was normal. FNAC also suggested to be non inflammatory cyst. All investigations and clinical features helped us to reach the diagnosis as dentigerous cyst associated with horizontally impacted mandibular second premolar which is extremely a rare clinical entity. Then surgery (Fig. 6) was planned. Patient was put on prior antibiotic coverage, Complete

enucleation was done under local anaesthesia and offending tooth was retrieved (Fig. 7). Collected specimen was sent for histopathology which later on confirmed to be dentigerous cyst.



Fig. 7. Tooth after surgical retrieval

## DISCUSSION

Dentigerous cysts are developmental cysts that enclose crown of an unerupted tooth at cemento-enamel junction. Dentigerous cysts are developmental cyst of odontogenic origin and the most prevalent, comprising 14 to 24% of the entire jaw cyst. (Regezi and Sciubba, 1999; Rubin, 2002) The exact histopathogenesis of these cysts is unknown. They are believed to be caused by expansion of dental follicles resulting from accumulation of fluid in the space between the tooth crown and epithelial components. (Edamatsu *et al.*, 2005) Dentigerous cyst are normally solitary, without any symptoms incidentally found during routine radiographic examination to locate status of missing teeth. They can occur at any location of the jaw but frequently seen in relation to the impacted mandibular third molars followed by the maxillary canines and maxillary third molars.<sup>10,11</sup> sometimes cyst become infected and painful resulting in expansion and thinning of cortex which may lead to pathological fracture.

On radiographic examination, dentigerous cysts appear as unilocular radiolucent area with well-defined and often sclerotic borders associated with the crown of unerupted tooth. The borders may be ill-defined when infected. Histologically, the lumen is lined by 2 to 4 cell layers of cuboidal to flattened nonkeratinized epithelial cells but may form keratin by metaplasia. The epithelium may be hyperplastic with the presence of hyaline bodies associated with inflammation. The connective tissue is more collagenous when inflamed and contain varying degree of chronic inflammatory cell infiltration. Dentigerous cysts are treated most commonly by enucleation, marsuplizations and decompression of cyst by fenestration. The criteria of treatment modalities are based on age, size and position of tooth.

Dentigerous cysts are treated most commonly by enucleation, marsuplizations and decompression involved and relation to adjacent teeth and vital structures. Treatment of choice for dentigerous cysts is removal of the associated tooth and enucleation of the soft tissue component. Large dentigerous may be treated with marsuplization followed by enucleation.

Prognosis is excellent when cyst is enucleated as whole to minimise chances of recurrence. Complete removal of the cyst is extremely important because ameloblastoma, squamous cell carcinoma and mucoepidermoid carcinoma have been reported as potential complications of untreated dentigerous cysts. (Shafer *et al.*, 2006)

## Conclusion

Dentigerous cyst is most commonly seen with impacted third molars, but dentigerous cyst associated with mandibular second premolar is a rare condition. Orthopantomograph (OPG), cone beam computed tomography (CBCT) and FNAC are important diagnostic tools to diagnose such cases. In this case report we have surgically treated horizontally impacted mandibular second premolar associated with dentigerous cyst successfully. Post operative healing was uneventful.

## REFERENCES

- Aziz, S.R. 2002. (Division of Oral and Maxillofacial Surgery, New York Presbyterian Hospital/Columbia University, New York, NY, USA. sa195@columbia.edu), Dourmas MA, Roser SM. Inferior alveolar nerve paresthesia associated with a mandibular dentigerous cyst. *J Oral Maxillofac Surg.*, 2002 Apr; 60(4):457-459.
- Edamatsu, M., Kumamoto, H., Ooya, K. and Echigo, S. 2005. Apoptosis related factors in the epithelial components of dental follicles and dentigerous cysts associated with impacted third molars of the mandible. *Oral Surg Oral Med Oral Pathol Oral Radiol Endod.*, 99:17-23.
- Larsen, P.E. Odontogenesis and odontogenic cysts and tumors. In: Cummings CC (ed). *Otolaryngology head and neck surgery*. 2nd. St Louis; Mo: Mosby- Year Book Inc; 1993.
- Regezi, A.J. and Sciubba, J.J. Cysts of the oral region in oral pathology: Clinical pathologic correlations. 3rd ed. Philadelphia: WB Saunders; 1999. p. 288-321.
- Regezi, A.J., Sciubba, J.J. Jordan, R.C.K. *Oral Pathology: Clinical Pathologic Correlations*. 5th ed. St. Louis: Saunders; 2008. 242-4p.
- Rubin, D.M. (Department of Oral and Maxillofacial Surgery, NSUCDM, Ft Lauderdale, FL 33328-2018, USA), Vendrenne D, Portnof JE. Orthodontically guided eruption of mandibular second premolar following enucleation of an inflammatory cyst A case report. *J Clin Pediatr Dent*, 2002 Fall; 27(1):19-23.
- Shafer, W.G., Hine, M.K. and Levy, B.M. 2006. *A textbook of oral pathology*. 4th ed. India: Reed Elsevier India Private Ltd; 260-5p.
- Shah, N. 2002. (Department of Oral and Maxillofacial Surgery, Central Middlesex Hospital, London), Thuau H, Beale T. Spontaneous regression of bilateral dentigerous cysts associated with impacted mandibular third molars. *Br Dent J.*, Jan 26;192(2):75-76.
- Shah, N., Thuau, H. and Beale, T. 2002. Spontaneous regression of bilateral dentigerous cysts associated with impacted mandibular third molars. *Br Dent J.*, 192:75-6.
- Shetty, R. and Sandler, P.J. 2004. Keeping your eye on the ball. *Dental Update* 31398-402.

Shun, Y. 2008. Dentigerous cyst associated with an impacted anterior maxillary supernumerary tooth. *J Dent Child (Chic)*, 75:104-7.

Sumita, M., Vineet, R., Karen, B. and Thomas, G. 2006. Non-syndromic bilateral dentigerous cysts of mandibular premolars: A rare case and review of literature. *Hong Kong Dental Journal*, 3:129-33.

\*\*\*\*\*