



## RESEARCH ARTICLE

### FINE NEEDLE ASPIRATION OF CERVICAL LYMPH NODES

Dr. Bolde, S. A., \*Dr. Pudale, S, S., Dr. Nikhar, C. K., Dr. Pandit, G. A. and Dr. Kamble, S.

Assistant Professor, Dr. V. M. G. M. C. Solapur, India

#### ARTICLE INFO

##### Article History:

Received 23<sup>rd</sup> June, 2016  
Received in revised form  
29<sup>th</sup> July, 2016  
Accepted 26<sup>th</sup> August, 2016  
Published online 20<sup>th</sup> September, 2016

##### Key words:

FNAC,  
Cervical Lymphadenopathy,  
Tuberculous Lymphadenitis.

#### ABSTRACT

**Introduction:** Lump in the neck is the most likely clinical problem to be encountered. Fine needle aspiration cytology (FNAC) is found to be simple, safe, cheap, OPD based procedure which is very useful in diagnosing cervical lymphadenitis, which are superficial and easily accessible, and have very little cosmetic damage.

**Aims:** To diagnose various cervical lymph node lesions by FNAC and to correlate FNAC findings clinically and histopathologically.

**Material and method:** This two years prospective study was done in department of Pathology in tertiary care center. A total of 234 FNAC were included in this study. Detailed clinical history, physical examination and investigations were recorded.

**Results:** Out of 234 cases of cervical lymph node aspiration, maximum belonged to nonneoplastic category, followed by malignant lesions in 20 cases. Tuberculous lymphadenitis was the most common non neoplastic lesion encountered in 102 cases (48.11%). Malignant lesion were detected in 20 cases (8.54%), in which metastatic squamous cell carcinoma accounted for 12 cases, followed by adenocarcinoma (2 cases) and lymphoma (6 cases). Thus, FNAC plays an important role in separating inflammatory lesions from cystic and neoplastic lesions in which no surgical excision is required. Early specific diagnosis allows prompt and appropriate treatment.

Copyright©2016, Dr. Bolde et al. This is an open access article distributed under the Creative Commons Attribution License, which permits unrestricted use, distribution, and reproduction in any medium, provided the original work is properly cited.

Citation: Dr. Bolde, S. A., Dr. Pudale, S, S., Dr. Nikhar, C. K., Dr. Pandit, G. A. and Dr. Kamble, S. 2016. "Fine needle aspiration of cervical lymph nodes", International Journal of Current Research, 8, (09), 38030-38034.

## INTRODUCTION

FNAC is valuable investigatory tool for the diagnosis of neoplastic and non- neoplastic lesions of lymph nodes. It is quick and inexpensive method which is used to sample cervical lymph node (Orell *et al.*, 2012; Singh, 1989). It is minimally traumatic diagnostic procedure and advocated its routine use before subjecting the patient to open biopsy (Ansari and Deria, 1997). It helps in separating inflammatory lesions from neoplastic lesions and makes surgical excision unnecessary.

## MATERIALS AND METHODS

This two years prospective study was done in department of Pathology in tertiary care center. The consent was taken from ethical committee of the institute. Detailed clinical history, physical examination and investigations were recorded. This study included 234 cases with cervical lymphadenopathy which were detected clinically.

FNAC was done in all cases, smears were stained with rapid papanicolaou and Haematoxylin and Eosin stain. Special stains like Ziehl Nelson were used wherever required. Under light microscopy, lesions were reported and categorized as inflammatory, benign and malignant.

## RESULTS

The present study included 234 cases with cervical lymphadenopathy which were detected clinically. The age of patients ranged from 3 years to 75 years. Male to female ratio was 1.4: 1. Out of 234 cases of cervical lymph node aspirations, 212 (90.60%) belonged to non- neoplastic category, followed by malignant lesions in 20 cases (8.55%). Tuberculous lymphadenitis was the most common non neoplastic lesion encountered in 102 cases (48.11), followed by reactive lymphadenitis 80 cases (37.74%), suppurative lymphadenitis 22 cases (10.38%) and granulomatous lymphadenitis 08 cases (3.77%). Maximum cases of tuberculous lymphadenitis were having AFB and HIV positive status. Malignant lesions were detected in 20 cases (8.54%), of which 12 cases showed metastatic squamous cell carcinoma, followed by adenocarcinoma (2 cases) and lymphoma (6 cases).

\*Corresponding author: Dr. Pudale, S, S.,  
Assistant Professor, Dr. V. M. G. M. C. Solapur, India.

**Table 1. Cytohistological correlation of lymph node lesions**

CYTODIAGNOSIS	No. OF CASES(T=234)	No. OF BIOPSIES	HISTOPATHOLOGICAL DIAGNOSIS		
			CORRECT ON HPR	REACTIVE LN	TB LN
Reactive lymphadenitis	80 (37.74%)	08	07		01
TB lymphadenitis	102(48.11%)	30	29	01	
Suppurative lymphadenitis	22(10.38%)	04	03		01
Granulomatous lymphadenitis	08(3.77%)	02	0		02
Metastatic SCC	12(5.13%)	03	03		
Metastatic adenocarcinoma	02(0.85%)	02	02		
NHL	04(1.71%)	02	02		
Hodgkin's disease	02(0.85%)	02	02		
Inadequate	02(0.85%)	02	NA	02	
TOTAL	234 (100%)	53	48	03	04

No- Number TB – Tuberculosis

HPR – Histopathological report NHL – Non – Hodgkin's lymphoma

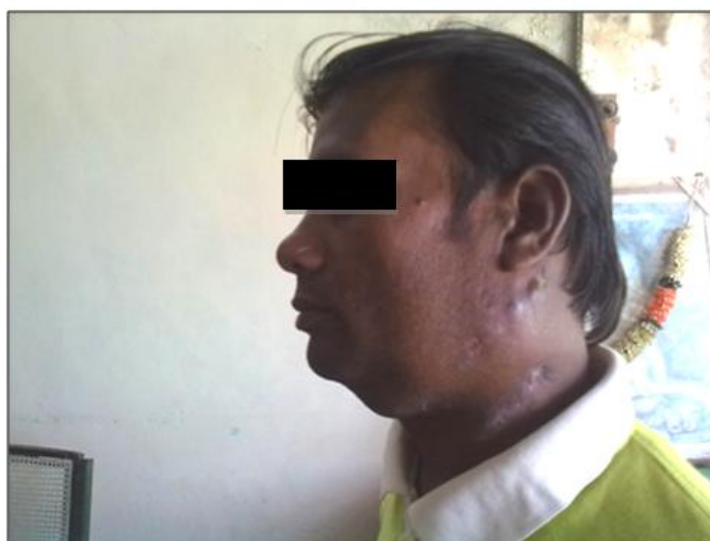LN – Lymph node SCC – Squamous cell carcinoma

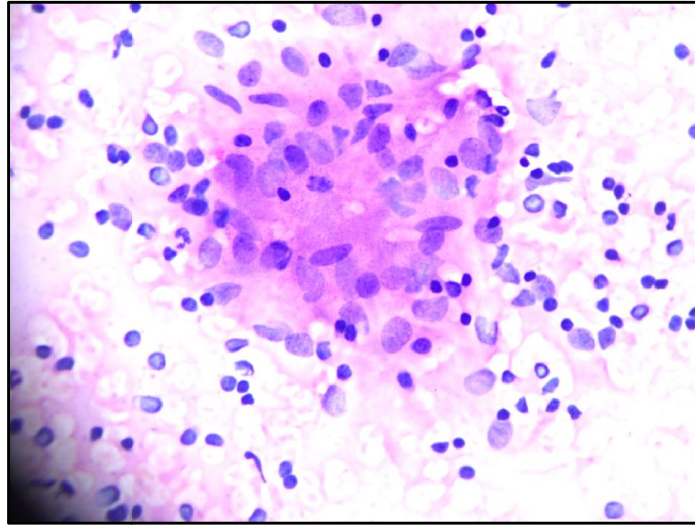
NA – Not applicable

**Table 2. comparison of present study with other studies for distribution of lesions of lymph node**

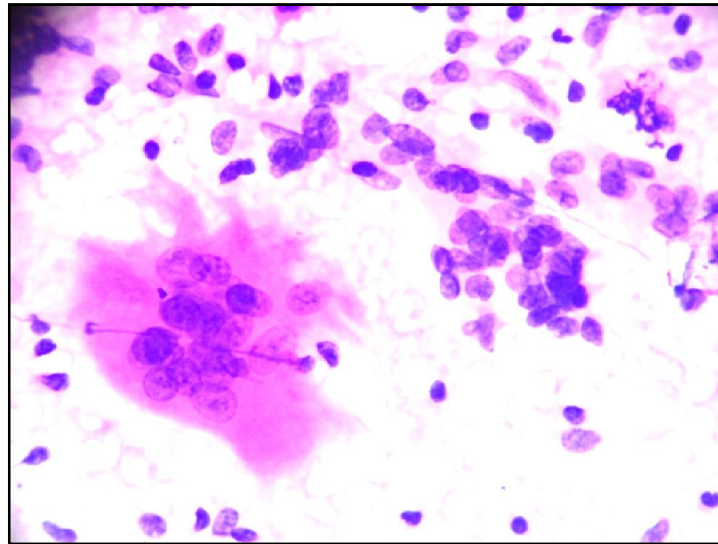
LESION	Frable&Frable (1974) <sup>5</sup>	BorgesAM(1986) <sup>6</sup>	Shaha at al(1986) <sup>7</sup>	Bandyopadhyay at al (1996) <sup>8</sup>	Hag et al(2003) <sup>4</sup>	Mazariqbal et al (2010) <sup>9</sup>	Present series
BENIGN/ NONNEOPLASTIC	43 %	14.96%	53%	64%	84%	-	90.60%
a)Reactive	-	6.58%	-	20%	45%	13.63 %	34.19%
b)Tuberculosis	-	8.38%	-	44%	30%	70.45%	43.59%
c)Others	-	-	-	-	9%	-	12.82%
MALIGNANT	57%	66.95%	44%	30%	16%	-	8.54%
a)Metastatic carcinoma	-	65%	33%	24%	11%	11.36 %	5.98%
i)SCC	-	50.56%	22%	14%	-	-	5.13%
ii) Adenocarcinoma	-	4.51%	11%	4%	-	-	0.85%
iii) Others	-	9.93%	-	6%	-	-	-
b)Lymphomas	-	1.95%	11%	6%	5%	4.54 %	2.56%
INCONCLUSIVE	-	5.41%	-	-	-	-	-
INADEQUATE	-	12.68%	3	6	-	-	0.85%

SCC- Squamous cell carcinoma

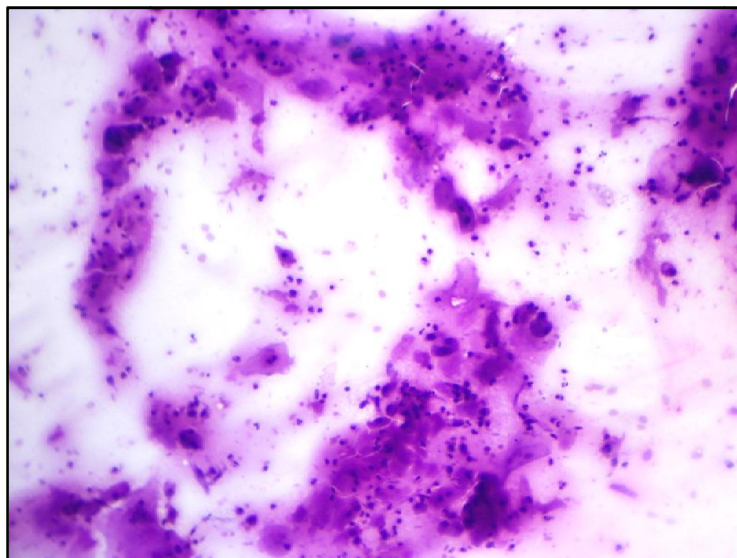
**Fig. 1. Tuberculous Lymphadenitis (healed sinuses)–Left cervical lymph node**



**Fig. 2. TB Lymphadenitis (H & E, High Power) –Epithelioid granuloma with necrosis**



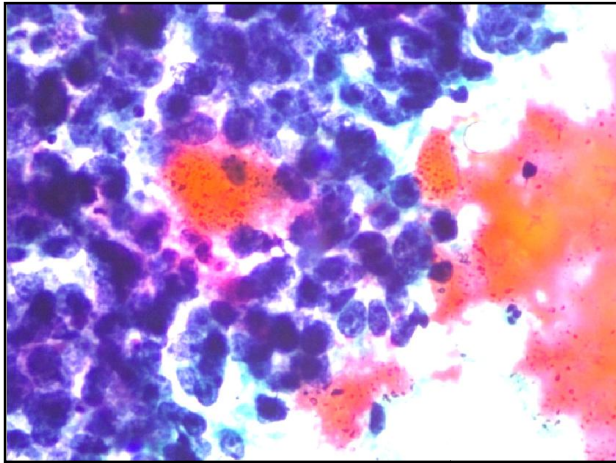
**Fig. 3. TB Lymphadenitis (H & E, High Power) – Multi-nucleated giant cell**



**Fig. 4. Cervicle Lymphnode (H & E, Low Power) - Epithelial metastases (SCC)**

**Table 3. comparison of distribution of malignant lymph node lesions with other studies**

Author	Lymphoma	Metastatic malignancy
Hag <i>et al</i> (2003)	5 %	11 %
Abdul <i>et al</i> (2011)	2 %	6 %
Farzana <i>et al</i> (2010)	3.9 %	4.5 %
Fatima <i>et al</i> (2011)	5.5 %	8.7 %
Present study	2.56 %	5.98 %

**Fig. 5. Cervicle Lymphnode (Pap stain, High Power) - Epithelial metastases (SCC)**

The larynx was the most common site of primary metastasizing to cervical lymph node. The cytologic diagnosis of lymph node FNA cases was confirmed on histopathology in 48 (90.57%) out of 53 lymph node biopsies.

## DISCUSSION

In the present study, age group of patients ranged from 3 years to 75 years with. Male to female ratio was 1.4:1. With respect to this, Hag *et al.* (2003) found wide age range of 7 months to 90 years. In the present study, 234 cervical lymph nodes aspirates were studied. The benign and non-neoplastic lesions formed the largest group in the present series (90.60%) and this is consistent with the observations as described in table number 2. Among the non- neoplastic group, tuberculous lymphadenitis was the most frequent lesion observed. Similar observations were reported by Bandopadhyay *et al.* (1996) and Borger, (1991). High prevalence of tuberculosis in our country explains high incidence of tuberculosis in the present study (Park, 2007). In maximum number of cases of tuberculous lymphadenitis, epithelioid cell granulomas with necrosis was observed. Gupta *et al.* (1992), Raghuveer *et al.* (1998) and Sen *et al.* (1999) have also observed similar results. Twenty lymph node aspirates were positive for malignancies in the present much more frequently than lymphoma. With respect to this, all of the authors enlisted in table number 3 found similar observations.

## Acknowledgement

Patients and their families who had given consent for FNAC.

## Conclusion

FNAC is found to be a simple, safe, inexpensive OPD based procedure which is very useful in diagnosing superficial and easily accessible cervical lymph node lesions. It helps in separating inflammatory lesions from neoplastic lesions and makes surgical excision unnecessary. Early specific diagnosis such as tuberculosis allows prompt and appropriate treatment. Thus, FNAC plays an important role in diagnosing various cervical lymph node lesions and helps in avoiding unnecessary surgical intervention.

## REFERENCES

- Ansari, M. and Deria, N. 1997. "Origins of Fine Needle Aspiration Cytology", *journal clinical pathology*, 10; 541-543.
- Bandopadhyay, S.N. *et al.* 1996. "Role of Fine Needle Aspiration Cytology in the diagnosis of cervical lymphadenopathy", *WO & HNS*; vol.48(4): 289-294.
- Borges, A.M. 1991. Aspiration cytology in the management of head and neck masses. In: Krishnamurthy SC, editor. *Aspiration cytology for clinicians and pathologists*. 1<sup>st</sup> ed. Bombay: TATA Press Limited.
- Farzana, S., Mirza, T., Mustafa, S., Saima, S., Sharafat, S. 2010. An experimental status of fine needle aspiration cytology of head and neck lesions in a tertiary care scenario. *Journal of Basic and Applied Sciences*, 6(2):159-162.
- Fatima, S., Arshad, S., Ahmad, Z., Hasan, S. 2011. Spectrum of Cytological findings in patients with Neck Lymphadenopathy – Experience in a tertiary Care Hospital in Pakistan. *Asia Pacific journal of Cancer Prevention*, vol 12.
- Frable WJ, Frable MA. Thin needle aspiration biopsy in the diagnosis of head and neck tumors. *The laryngoscope* 1974;84: 1069-1077
- Gupta, A.K., Nayar, M., Chandra, M. 1992. Critical appraisal of fine needle aspiration cytology in tuberculous lymphadenitis. *Acta Cytologica*, 36(3): 391-394.
- Hag, I.A.E., Chiedozi, L.C., Reyeas, F.A.A., Kollur, S.M. 2003. Fine needle aspiration cytology of head and neck masses : seven years experience in tertiary care hospital. *Actacytologica*, 47:387-389.
- Khan, A.H., Hayat, A.S., Ghulam, H.B. *et al.* 2011. Study on Role of Fine Needle aspiration Cytology in Cervical lymphadenopathy. *World Applied Sciences Journal*. 12 (11):1951-1954.
- Mazar, I., Anis, S., Asadullah, A. 2010. Frequency of tuberculosis in cervical lymphadenopathy. *Journal of Surgery Pakistan*, 15(2):107-109.
- Orell, S.R., Sterret, G.F., Walters, Max, N.I., Darrel Whitaker, D. 2012. Ed., *Manual and atlas of fine needle aspiration cytology*, 5<sup>th</sup> ed. London, Churchill Livingstone, 1-3.
- Park, K. 2007. *Textbook of preventive and social medicine*. 19<sup>th</sup>ed: Jabalpur; M/S BanarsidasBhanot Publications.
- Raghuveer, C.V., Bhattacharya, S., Pai, M.R. 1998. Fine needle aspiration cytological study. *Indian Journal of Pathology and Microbiology*, 41:206.
- Sen, R. 1999. Cytomorphological pattern in tuberculous lymphadenitis. *Indian Journal of Tuberculosis*,46:125.

Shaha, A. Webber, C. and Marty, J. 1986. Fine needle aspiration in the diagnosis of cervical lymphadenopathy. *The American journal of Surgery*, Oct:152:420-423.

Singh, J.P. *et al.* 1989. "Role of Fine Needle Aspiration Cytology in diagnosis of Tuberculous lymphadenitis", *Indian journal Pathology & Microbiology*, vol.32(2): 101-104, 1989.

\*\*\*\*\*