



ISSN: 0975-833X

## RESEARCH ARTICLE

### ACUTE PANCREATITIS, A COMPLICATION OF ACUTE HEPATITIS E INFECTION- A CASE REPORT

<sup>1</sup>Dr. Surya Prakash Yarramalle, <sup>2</sup>Kartik Munta, <sup>3,\*</sup>Dr. Manimala Rao, S. <sup>4</sup>Dr. Yogesh Harde, <sup>5</sup>Dr. Sandeep, G.B. and <sup>6</sup>Dr. Rajkumar Jupally

<sup>1,2,3,4</sup>Department of Critical Care Medicine, Yashoda Multi-Speciality Hospital, Somajiguda, Hyderabad, India

<sup>5</sup>Department of Anaesthesia and Critical Care Medicine, Yashoda Multi-Speciality Hospital, Somajiguda, Hyderabad, India

<sup>6</sup>Department of Anaesthesia and Critical Care Medicine, Yashoda Multi-Speciality Hospital, Somajiguda, Hyderabad, India

#### ARTICLE INFO

##### Article History:

Received 03<sup>rd</sup> September, 2016  
Received in revised form  
18<sup>th</sup> October, 2016  
Accepted 10<sup>th</sup> November, 2016  
Published online 30<sup>th</sup> December, 2016

##### Key words:

Acute Pancreatitis,  
Viral Hepatitis,  
Hepatitis E Virus.

Copyright©2016, Dr. Surya Prakash Yarramalle et al. This is an open access article distributed under the Creative Commons Attribution License, which permits unrestricted use, distribution, and reproduction in any medium, provided the original work is properly cited.

Citation: Dr. Surya Prakash Yarramalle, Kartik Munta, Dr. Manimala Rao, S. Dr. Yogesh Harde, Dr. Sandeep, G.B. and Dr. Rajkumar Jupally. 2016. "Acute pancreatitis, a complication of acute hepatitis e infection- a case report", *International Journal of Current Research*, 8, (12), 43009-43011.

#### ABSTRACT

Acute pancreatitis secondary to viral infections is well established. Acute pancreatitis as a complication of fulminant hepatic failure has been mostly reported but as secondary to non fulminant hepatitis especially due to HEV infection has been rarely reported. Leakage of intracellular enzyme and cell destruction has been attributed as main cause. We describe a case report of acute pancreatitis secondary to viral hepatitis due to HEV infection.

## INTRODUCTION

Acute pancreatitis is an inflammation of the exocrine pancreas. Alcohol and cholelithiasis remains the main etiological factors but viral infections are also considered as other important etiology. Most common viruses are mumps, Coxsackie, Epstein-Barr virus and measles viruses (Parenti, 1996; Wislocki, 1966). Acute pancreatitis as a complication of fulminant hepatitis is well known. Earliest case was reported in mid 90's, about pancreatitis as a complication of infectious hepatitis (Lisney, 1944). Hepatotropic viruses have a strong predilection for hepatocytes, but there are evidences indicating their involvement in organs like pancreas and gall bladder (Hoefs *et al.*, 1980; Shimoda *et al.*, 1981). New onset abdominal pain in a patient with acute viral hepatitis should raise the suspicion of acute pancreatitis and should be appropriately investigated. Pancreatitis has been reported rarely in acute (non fulminant) viral hepatitis (Ede *et al.*, 1988; Ham and Fitzpatrick, 1973). It has been reported with hepatitis A (HAV), hepatitis B (HBV) and hepatitis E virus (HEV) infection.

\*Corresponding author: Dr. Manimala Rao, S.,  
Department of Critical Care Medicine, Yashoda Multi-Speciality Hospital, Somajiguda, Hyderabad, India.

There are few case reports of hepatitis E virus causing acute pancreatitis.

### Case report

A 20 year old male presented with history of yellowish discolouration of eyes and urine since 4 days. He was afebrile, and had stable vital parameters. There was icterus, without any tenderness over epigastrium or umbilical region, with a palpable liver. Lab data showed Haemoglobin 15.2 gm%, white cell count of 9,500/mm<sup>3</sup>, blood sugar 72 mg/dl, blood urea 17 mg/dl and normal electrolytes. Liver function test revealed serum bilirubin 15.1 mg/dl (direct 11, indirect 3.2), alkaline phosphatase 255 IU/L, SGOT 6033 IU/L, SGPT 5763IU/L. X ray of chest and ECG were normal. Ultrasound examination of abdomen reported mild splenomegaly, distended gall bladder, absence of gall stones and normal pancreas [Fig 1]. History of alcohol abuse, gall stone disease, drugs (relevant to the causation of jaundice), or trauma to abdomen were excluded. In view of high levels of SGOT and SGPT, serum sample for viral etiology was evaluated and it revealed raised IgM antibodies to hepatitis E virus while other viral markers were negative.

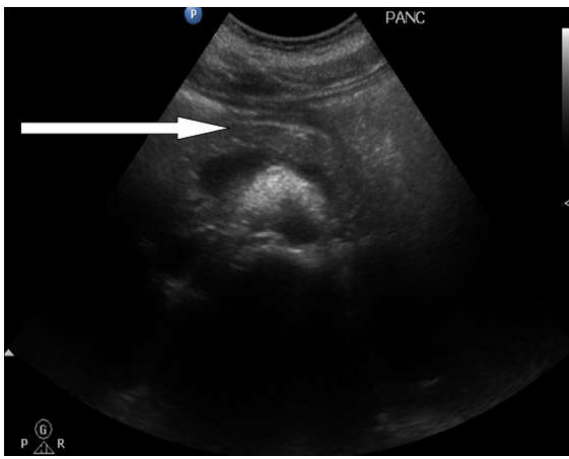


Figure 1. Ultrasound Abdomen With Normal Pancreas

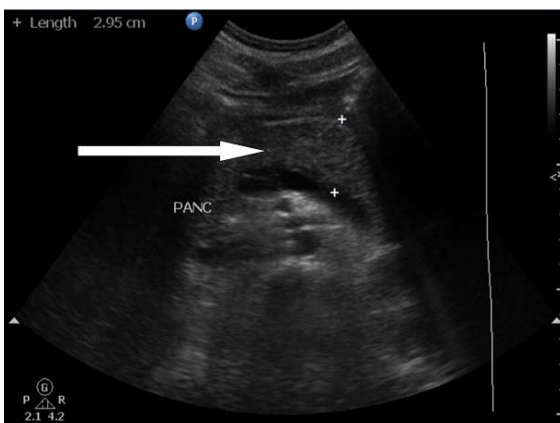


Figure 2. Ultrasound abdomen with edematous pancreas

Decreasing trend of SGOT 220IU/L, SGPT 1304IU/L were noted during supportive care. Patient was discharged 3 days after hospital stay as his general condition improved. Five days later patient was readmitted with complaint of pain in abdomen, radiating to back and associated with an episode of vomiting. Palpation of abdomen revealed tenderness in the epigastric region. Investigations showed raised white cell count 21,870 cells/mm<sup>3</sup>, serum bilirubin 14.5 mg% (direct 9, indirect 1.4), alkaline phosphatase 153 IU/L, SGOT 84 IU/L, SGPT 281IU/L. Pancreatic work up showed elevated serum lipase 11,640 IU/L and elevated serum amylase of 1,601IU/L. Ultrasound examination of abdomen revealed bulky pancreas with peripancreatic fluid collection [Fig 2]. Lipid profile was found to be normal. A diagnosis of hepatitis E induced acute pancreatitis was made and conservative management was planned. He was discharged from the hospital and was asymptomatic two weeks after discharge.

## DISCUSSION

Acute pancreatitis as a complication of viral infection is well established. Mumps virus commonly causes pancreatitis even in the absence of parotitis (Geokas *et al.*, 1972). Recently it has been reported about pancreatic involvement in benign forms of viral hepatitis (Lisney, 1944; Shimoda *et al.*, 1981; Ham, 1973). Most of the cases reported acute pancreatitis as a complication of fulminant hepatic failure (Bhagat *et al.*, 2008; Ichihara *et al.*, 1992; Jain *et al.*, 2007; Mishra *et al.*, 1999). According to a case series in 2002, the incidence of extrahepatic manifestations of viral hepatitis is 6.4% among

448 cases. Various reports showed among the hepatitis viruses, hepatitis A, B, and non-A non-B viruses as cause of acute pancreatitis (Parenti *et al.*, 1996; Wislocki, 1966; Shimoda *et al.*, 1981; Ede *et al.*, 1973). Results of main case series done in Indian patients (summarised in Table 1) acute pancreatitis is most commonly seen in young patients, in second or third weeks of hepatitis illness and was self limiting. Our patient during the second week of illness, developed pancreatitis secondary to Hepatitis E virus infection. Very few cases have been reported from India regarding Hepatitis E viral infection as a cause of pancreatitis. According to World Health Organization (WHO), incidence of Hepatitis E virus (HEV) infections worldwide is estimated to be 20 million per year with 3.3 million symptomatic cases and 56,600 HEV related deaths. South and East Asia have the highest prevalence of HEV infection than rest of the World.

Table 1. Summary of the data from three previous studies from India

	Mishra <i>et al.</i>	Jain <i>et al.</i>	Bhagat <i>et al.</i>
Total Number of patients	6	6	7
Age (mean)	13.5 yr	23.9	19.4
Gender (M: F)	5 : 1	7 : 0	6 : 1
HepA: HepE	3 : 3	4 : 2	3 : 4
Method of confirmation of viral hepatitis	Serology	Serology	Serology
Day of onset of pancreatitis	10-22	2-30	3-17
Mortality	0	0	0

HEV infection can be either asymptomatic or fulminant acute hepatitis. Diagnosis of HEV infection in immunocompetent individuals is by detection of anti-HEV immunoglobulin M (IgM), raised titers of anti-HEV immunoglobulin G (IgG), or detection of HEV RNA in blood or stool where as in immune compromised individuals is by detection of HEV RNA in blood or stool. In our patient, raised IgM antibodies to hepatitis E virus were found. Ham *et al.* autopsied 42 cases of acute liver failure mainly due to viral hepatitis and found all grades of pancreatitis. The mechanism of pancreatic injury in viral hepatitis is unclear. Proposed mechanism is associated with oedema of ampulla of Vater secondary to viral hepatitis and acute liver failure. Recently, hepatitis viruses causing damage to the pancreatic acinar cell membrane, leading to the leakage of intracellular enzymes, and setting off a chain of intracellular events culminating in cell death was proposed. Onset of severe abdominal pain in second or third week of hepatitis, should caution the clinician regarding the diagnosis of associated acute pancreatitis in a case of viral hepatitis.

## Conclusion

Acute pancreatitis might occur within two or three weeks of onset of hepatitis. This complication though has low incidence should always be considered when an acute hepatitis patient complains of abdominal pain and it requires further evaluation. Though Hepatitis E virus is a rare cause of acute pancreatitis secondary to acute hepatitis, its evaluation should be performed if routine tests are inconclusive. The prognosis of the patients with acute pancreatitis secondary to acute hepatitis remains usually good.

## REFERENCES

- Amarapurkar DN, Amarapurkar AD. Extrahepatic manifestations of viral hepatitis. *Ann Hepatol.* 2002; 1:192-5.

- Bhagat, S.; Wadhawan, M.; Sud, R. and Arora, A. - Hepatitis viruses causing pancreatitis and hepatitis: a case series and review of literature. *Pancreas*, 36: 424-427, 2008.
- Ede, R.J., Moore, K.P., Marshall, W.J., Williams, R. 1988. Frequency of pancreatitis in fulminant hepatic failure using isoenzyme markers. *Gut*, 29:778-81.
- Geokas, M.C., Olsen, H., Swanson, V. & Rinderknecht, H. 1972. The association of viral hepatitis and acute pancreatitis. *Calif. Med.*, 117: 1-7.
- Ham, J.M., Fitzpatrick, P. 1973. Acute pancreatitis in patients with acute hepatic failure. *Am J Dig Dis.*, 18:1079-83.
- Hoefs, J.C., Renner, I.G., Askhcavai, M., Redeker, A.G.1980. Hepatitis B surface antigen in pancreatic and biliary secretions. *Gastroenterology*, 79: 191-94.
- Ichihara, S.; Sato, M. and Kozuka, S. 1992. Prevalence of pancreatitis in liver diseases of various etiologies: an analysis of 107,754 adult autopsies in Japan. *Digestion*, 51: 86-94.
- Jain, P.; Nijhawan, S.; Rai, R.R.; Nepalia, S. & Mathur, A. - Acute pancreatitis in acute viral hepatitis. *Wld J. Gastroent.*, 13: 5741-5744, 2007.
- Lisney, A.A. 1944. Infective hepatitis in Leicestershire, a survey of 1,062 cases. *Proc Roy Soc Med*37:165.
- Lopez Morante A., C. Rodriguez de Lope, G. San Miguel, and R. Pans Romero, "Acute pancreatitis in hepatitis A infection," *Postgraduate Medical Journal*, vol. 62, pp. 407-408, 1986.
- Maity S. G. and G. Ray, "Severe acute pancreatitis in acute hepatitis E," *Indian Journal of Gastroenterology*, vol. 21, no. 1, pp. 37-38, 2002.
- Mishra, A.; Saigal, S.; Gupta, R. & Sarin, S.K. 1999. Acute pancreatitis associated with viral hepatitis: a report of six cases with review of literature. *Amer. J. Gastroent.*, 94: 2292-2295.
- Oliveira, L.C.; Rezende, P.B.; Ferreira, A.L. *et al.* - Concurrent acute hepatitis and pancreatitis associated with hepatitis B virus: case report. *Pancreas*, 16: 559-561, 1998.
- Parenti, D.M., Steinberg, W., Kang, P. 1996. Infectious causes of acute pancreatitis. *Pancreas*, 13:356-71.
- Shimoda, T., Shikata, T., Karasawa, T., Tsukagoshi, S., Yoshimura, M., Sakurai, I. 1981. Light microscopic localization of hepatitis B virus antigens in the human pancreas. Possibility of multiplication of hepatitis B virus in the human pancreas. *Gastroenterology*, 81:998-1005.
- Wedemeyer H, Pischke S, Manns MP. Pathogenesis and treatment of hepatitis e virus infection. *Gastroenterology*, 2012;142:1388-97.
- WHO. Hepatitis E [cited 14 October 2014]. Available from:<http://www.who.int/mediacentre/factsheets/fs280/en/>.
- Wislocki, L.C 1966. Acute pancreatitis in infectious mononucleosis. *N Engl J Med.*, 275:322-23.

\*\*\*\*\*