



## CASE REPORT

### PANCREATIC CANCER COMPLICATING PREGNANCY

**\*Dr. Sumathi, N.**

Professor of OG, GRH Madurai, Tamil Nadu

#### ARTICLE INFO

##### Article History:

Received 05<sup>th</sup> October, 2016  
Received in revised form  
26<sup>th</sup> November, 2016  
Accepted 30<sup>th</sup> December, 2016  
Published online 31<sup>st</sup> January, 2017

##### Key words:

Pancreatic carcinoma, LSCS,  
Whipples procedure. Gemcitabine.

**Copyright**©2017, Sumathi. This is an open access article distributed under the Creative Commons Attribution License, which permits unrestricted use, distribution, and reproduction in any medium, provided the original work is properly cited.

**Citation:** Dr. Sumathi, N., 2017. "Retail managers' perception on coca-cola company's success of glass package recovery and recycling in Nairobi in Kenya", *International Journal of Current Research*, 9, (01), 45815-45817.

#### ABSTRACT

Pancreatic neoplasms, both benign and malignant, are uncommon during pregnancy. There have been only eight reported cases of pancreatic adenocarcinoma. Adenocarcinomas of the pancreas during pregnancy present a unique treatment challenge. In all cases the goal is to minimize both maternal and fetal risk. In this article we discuss about a 25 yrs old G2P1L1, Previous LSCS, a case of pancreatic carcinoma. Oncologist opinion was obtained, planned to continue pregnancy with explained risk of fetal anomaly. Serial USG, LFT, Serum amylase level monitored. The size of lesion in pancreas was not increasing. Elective repeat LSCS was done and delivered an alive term male baby wt 3kg with no anomaly and good apgar. Patient is now on follow up with oncologist. This case has been presented for its rarity.

#### INTRODUCTION

25yrs old, G2P1L1/Previous LSCS with LMP-25/08/2012 came for regular AN checkup with H/O 4 months amenorrhoea. On examination patient general condition was fair. P/A-pfannensteil scar+, laparotomy scar+, uterus 16 weeks. USG done on 22.12.12 revealed a single live viable foetus with growth corresponding to 17 weeks 1 day GA by U/S in transverse lie with estimated foetal weight of 184gms and USG EDD 31/05/2013, normal nuchal thickness, no evidence of chromosomal anomalies at present. Maternal abdomen: 16\*14\*12.4 cm [1453ml] cystic solid with internal echoes and minimal vascularity interspersed between tail of the pancreas, spleen and left kidney. Impression was infected pancreatic pseudocyst. Patient didn't revealed the reason for laparotomy initially, but after USG admitted that she was diagnosed as a case of pseudopapillary tumor of pancreas in 2008. Mass was inoperable and she completed 6 cycles of chemotherapy at Govt. Rajaji hospital. On 03/08/2008, multiple small bits of tissue were taken for biopsy which showed groups of carcinomatous cells with occasional glandular pattern. Aspirated fluid sent for C/S shows growth of staphylococcus aureus. CT SCAN on 27/2/2008 – pseudopapillary tumor. Chemotherapy – six cycles completed. Follow up scan done after chemotherapy showed well defined cystic lesion with thick irregular wall seen in the retrogastric region, abutting from anterior surface of tail of pancreas, indentation of posterior wall of body of stomach. Lesion measures 6.1\*5cm in present scan. No obvious peritoneal seedling seen. No ascites.

**\*Corresponding author: Dr. Sumathi, N.**  
Professor of OG, GRH Madurai, Tamil Nadu, India

CT SCAN on 21/03/2009 showed mild reduction in size of mass of 6\*4.1cm. CT SCAN again on 26/10/2009 showed well defined lesion with cystic, solid component seen in retrogastric region measuring 5.8\*4.3cm. After 2009 pt didn't turned up for further follow up, until in 2012 when she became pregnant and came for regular AN check up. Oncologist opinion suggested to continue the pregnancy and premature induction if necessary. Patient can be referred back after delivery and chance of fetal anomaly to be explained to the patient.

#### Investigations

Hb-10.4g%, RBS-110mg%, Bilirubin- 0.79mg, SGOT - 23IU/L, SGPT-28IU/L, ALP-87IU/L, Sr.amylase-67U/L, Sr. protein – 6.5g. Albumin 3.5g, Globulin 3g, PT 17sec, INR 1.2 USG done on 23/02/2013 - single live fetus, GA-26 to 27 weeks, Placenta fundal posterior grade I, AFI-13.5, No fetal anomaly at present. Maternal abdomen showed 14.4\*12.7\*13.5cm vascular mass with multiple cystic areas adjacent to tail of pancreas.

#### Management

Pt was planned for elective repeat LSCS and delivered an alive term male baby on 14/05/2013 with no anomaly and good APGAR. On 19/07/2008, patient USG was repeated which showed 12.5\*8.6\*9.2cm mass with mixed echogenicity in tail of pancreas with no evidence of any significant para aortic lymphadenopathy, with moderate amount of free fluid noted in abdomen and pelvis. Impression was Retroplacental sarcoma. Patient on follow up with oncologist.

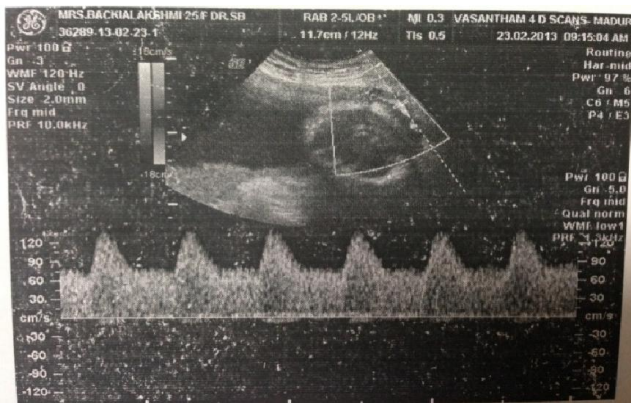


Figure 1. USG picture showing fetus

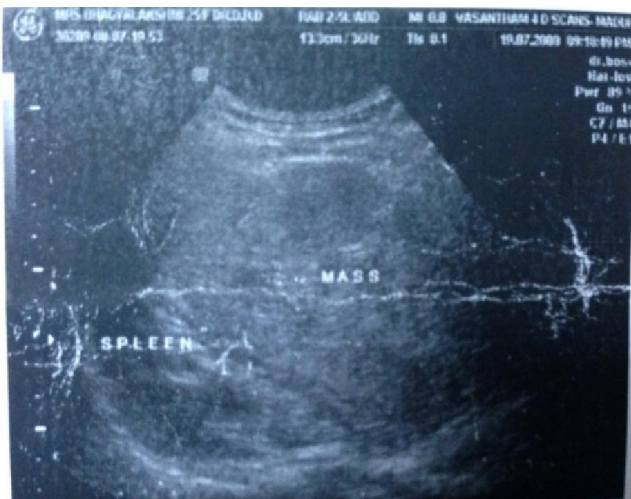

Figure 2. USG picture showing placental mass

## DISCUSSION

Most pancreatic cancers are adenocarcinomas. They are highly lethal. They are difficult to diagnose as often the diagnosis is made late in the course of disease (World Cancer Report, 2014). Only curative treatment is surgical removal. Chemotherapy after surgery can lower the chances of the recurrence. Many organizations exist to help provide information and support for patients and families fighting with pancreatic cancer. Two major categories of pancreatic cancers are Cancer of endocrine pancreas – islet cell cancers secrete insulin, glucagon and Pancreatic adenocarcinomas – 95%. Risk factors are genetic syndromes – BRCA 2, African American race, Tobacco use, Obesity, Sedentary lifestyle, H/O diabetes, H/O pancreatitis, Fatty diet, H. pylori infection, No identifiable cause in most people. Symptoms are weight loss, Jaundice and mostly present with Non specific symptoms. 75% diagnosis is by USG, CT guided biopsy if any suspicion, ERCP, Tumor markers – CA 19-9

## Treatment protocols

Surgical resection for pancreatic cancer is potentially the only curative treatment approach. Primary tumor size measurements are often discordant between CT scan and pathologic specimen after resection. Stage I and II -resectable local disease – whipples procedure [pancreaticoduodenectomy], Neoadjuvant therapy - a) capecitabine and 5-FU, b) FU/cisplatin plus radiation, c) gemcitabine/cisplatin . Adjuvant monotherapy - gemcitabine 1000mg/m<sup>2</sup> IV over 30 min weekly for 3 weeks

every 4 weeks for 6 cycles. Chemoradiation: gemcitabine + RT - 1.8Gy/day to a total of 50.4Gy 3-5 cycles after chemoradiation with gemcitabine weekly every 28 day for 3 cycles. Stage III - locally advanced resectable disease, Neoadjuvant : gemcitabine weekly 3 weeks every 28 days (OR) 5FU 500mg/m<sup>2</sup>/day IV bolus on 1-3 and 29-31 with radiotherapy. Stage IV - treatment recommendation for metastatic disease median overall survival on gemcitabine based therapy is between 5.5 to 7yrs. Generally poor outcomes with standard therapy. Prognosis for Stage I, II – after whipple procedure, 20% 5 yrs survival, 80% < 2 yrs, Stage IV – survival rate is just around 6 months

## Recent updates

Genetics and early detection - KRAS oncogene affects regulation of all growth. By ERCP – pancreatic juice is collected and samples are studied for the changes. Targeted therapies are growth factor inhibitors - erlotinib approved for use with gemcitabine, Anti angiogenic factors, Drugs that target the tumor stroma, Cancer vaccines and immuno Therapy are under clinical trials

## Gemcitabine

A nucleoside analogue – arrests tumor growth. The triphosphate analogue of gemcitabine replaces cytidine during DNA replication as only one additional nucleoside can be attached to faulty nucleoside – resulting in apoptosis. The diphosphate analogue binds to RNR [ribonucleotide action site – inactivates irreversibly - cell can't produce deoxy ribonucleotide for DNA replication – induced cell apoptosis. Administered by IV route. It was intended as an antiviral drug but clinical testing showed that it killed leukemia cells (McMillan *et al.*, 2015).

## Review of literature

If diagnosed during pregnancy at 18-20 weeks of gestation ERCP, stent placement and pancreaticoduodenectomy done can be performed successfully. One study found 71 cases in a cohort of 11606 female cancer patients aged 15 – 44 yrs[0.6%]. Simchule *et al* diagnosed the first case, a primary pancreatic cancer unresectable tumor in pregnant woman (Simchule *et al.*, 1995). A healthy boy delivered by LSCS at 28 weeks and choledochoduodenectomy done. Patient died 3 months after surgery. Gamberdella reported the second case. ERCP was performed at 24 weeks and cholecystostomy done (Gamberdella, 1984). At 32 weeks healthy twins delivered by LSCS patient died 3 months postpartum. Duff and Greene reported the third case (Duff, 1985). A woman with abdominal mass detected at 13 weeks of gestation. Open biopsy taken and it was a solid papillary tumor. Patient developed pulmonary embolism. And embolectomy done. Patient spontaneously aborted after which whipple procedure was done. Regardless of the pregnancy, the evaluation and treatment should not be compromised although it may not to be modified. The specific risk associated with each according to the gestational age of the fetus, most of the procedures can be safely performed.

## Conclusion

Pancreatic tumors occurring during pregnancy present a unique diagnostic and treatment dilemma. Mucinous cystic neoplasms (MCNs) and adenocarcinomas represent the most commonly

reported tumors of the pancreas during pregnancy. In the case of intrauterine growth restriction (IUGR) or maternal instability, urgent surgical intervention should be undertaken regardless of gestational age. Benign tumors diagnosed during the first trimester and without concern for IUGR may be managed expectantly, while the diagnosis of a malignant tumor during the first trimester should prompt a discussion about termination of the pregnancy in order to pursue optimal therapy. The second trimester of pregnancy remains the most favorable time for surgical intervention for tumors of the pancreas, and resectable tumors diagnosed during this trimester should undergo surgical resection. Tumors of the pancreas diagnosed during the third trimester can be resected after an early delivery. Unresectable tumors have a poor prognosis, and a multidisciplinary approach to these patients can allow for the best outcome for both the mother and the fetus.

## REFERENCES

- Duff, P. 1985. green VP – pregnancy complications by solid papillary tumor of pancreas. *Am.J.obstetric and gynec.*, May 1; 152 (1):80-1
- Gamberdella, F.R. 1984. Pancreatic cancer in pregnancy a case report *Am.J.ofrite. Gynec.*, May 1;149 (1): 15-7.
- McMillan, M.T., Lewis, R.S., Drebin, J.A., Teitelbaum, U.R., Lee, M.K., Roses, R.E., et al. 2015. The efficacy of adjuvant therapy for pancreatic invasive intraductal papillary mucinous neoplasm (IPMN). *Cancer*, Nov 20. feb.15,122 (4):521-533
- Simchule, E.J., Welch, J.P., Orlando, R. 1995. antepartum diagnosis of pancreatic cancer a case report [conn.med] May, 59 (5): 259-62.
- World Cancer Report, 2014. World Health Organization. 2014. Chapter 5.7. ISBN 92-832-0429-8

\*\*\*\*\*