



RESEARCH ARTICLE

A RARE CASE OF MULTIPLE HYPERCEMETOSIS IN A FEMALE PATIENT

*¹Pradeep Christopher, ¹Jasline David, J., ¹Poorna Devadoss and ²Raja Satish, P.

¹Dept of Orthodontics, Thai Moogambigai Dental College and Hospital, Golden George Nagar, Chennai, Tamilnadu, India

²Reader, Dept of Omfs, Sibar Dental College, Guntur, Andhra Pradesh

ARTICLE INFO

Article History:

Received 16th December, 2016
Received in revised form
07th January, 2017
Accepted 27th February, 2017
Published online 31st March, 2017

Key words:

Hypercementosis,
Cemental hyperplasia.

ABSTRACT

Hypercementosis is an excessive, non-neoplastic deposition of radicular cementum and is mostly presented as a solitary lesion or in rare cases as a multiple type. It usually occurs in the premolar and molar region of the mandible with no sex predilection. Hypercementosis is coupled with a number of etiological factors, which may be local or systemic in nature. It is decision making choice for a general dental practitioner to manage such situations. We report a female patient with multiple hypercementosed tooth.

Copyright©2017, Pradeep Christopher et al. This is an open access article distributed under the Creative Commons Attribution License, which permits unrestricted use, distribution, and reproduction in any medium, provided the original work is properly cited.

Citation: Pradeep Christopher, Jasline David, J., Poorna Devadoss and Raja Satish, P. 2017. "A rare case of multiple Hypercementosis in a female patient", *International Journal of Current Research*, 9, (03), 47947-47949.

INTRODUCTION

In 1931, Gardner and Goldstein defined hypercementosis as an excessive growth of cementum of the tooth observed radiographically as circumscribed cemental hyperplasia (Leider, 1987). It is characterised by an excessive, non-neoplastic deposition of radicular cementum involving a single tooth, several teeth or the entire dentition. Hypercementosis may present secondary to either local factors or systemic disorders, but in most cases represents as an idiopathic, age-related phenomenon. Systemic disturbances associated with a more generalized hypercementosis include Paget's disease of bone, thyroid goiter, rheumatic fever, arthritis, acromegaly, calcinosis and possible vitamin A deficiency (Leider, 1987 and Noonan, 2008). Hypercementosis has been noticed not only on erupted teeth but also on a tooth that is not erupted. A female patient with multiple hypercementosed tooth is described here.

Case Report

A female patient aged 41 years reported to a private Dental clinic with complains of pain in the left upper back tooth. On intraoral examination badly decayed 28 was supraerupted with generalized attrition was noticed (Figure 1). OPG revealed multiple hypercementosed tooth both in maxillary and

mandibular posterior region, some degree of hypercementosis in the mandibular anterior region were appreciated (Figure 2). It was decided to carry out a surgical extraction of the 28 and the treatment plan was explained to the patient. An informed consent was obtained from the patient for surgical extraction of 28 in case of any resistance. There was no significant medical history. Her hemogram was within normal parameters. Estimation of serum calcium, phosphorus, alkaline phosphatase, T₃, T₄ and TSH levels showed normal values. Strict aseptic techniques were followed during the surgical extraction procedure (Figure 3). A course of broad spectrum antibiotics and analgesics were prescribed for the patient. There was no post extraction complication.

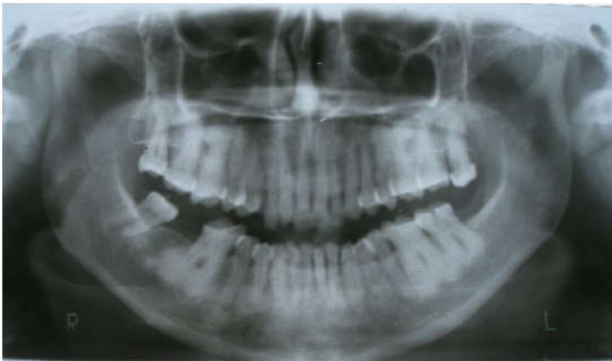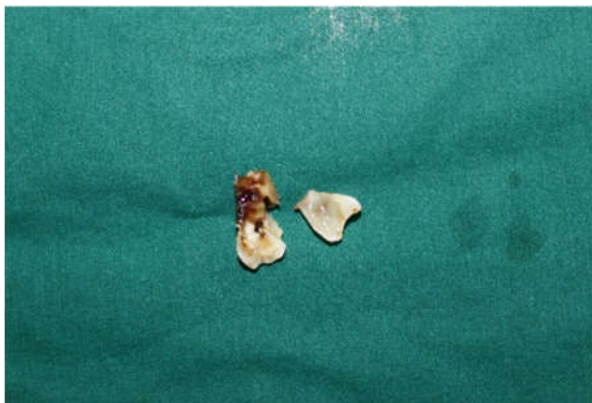
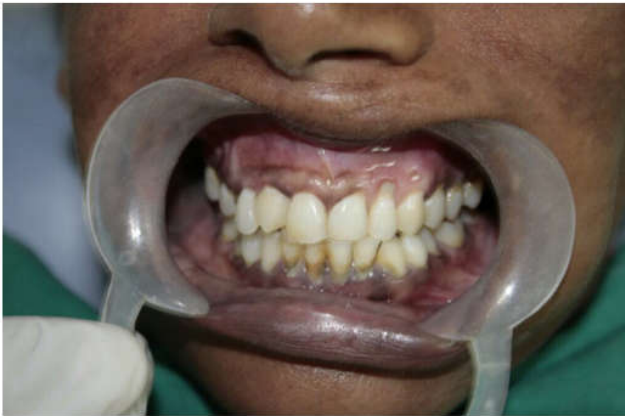DISCUSSION

Hypercementosis is an abnormal and prominent thickening of cementum which can be generalised or localised in form. Generalized hypercementosis is characterized by increased thickness of cementum involving all teeth and is a classical feature of Paget's disease.³ Localised hypercementosis affects single tooth with nodular thickening of apical third of root. Cemental spikes or outgrowths of cementum on the root surfaces are an uncommon condition and a rare manifestation of hypercementosis. Various reasons like functional stress due to occlusal forces, continuous dental eruption, incorporation of periodontal cementicles during physiologic cementum deposition, reactionary deposition in response to periapical

*Corresponding author: Pradeep Christopher

Dept of Orthodontics, Thai Moogambigai Dental College and Hospital, Golden George Nagar, Chennai, Tamilnadu, India

inflammatory processes as well as atherosclerosis, acromegaly, deforming arthritis, thyroid diseases and Paget's disease were seem to be contributing systemic factors (Noonan, 2008).



Functional stress cannot be considered as an etiological factor in our case because the opposing mandibular third molar was missing. In tooth without antagonist, hypercementosis usually presents as nodular thickening of apical third of root and occurs as an attempt to maintain the width of the periodontal ligament and to compensate the accelerated eruption of the tooth. Since this patient had no obvious systemic contributory factors, the mechanism for hypercementosis cannot be explained in simple terms and hence presumed to be idiopathic in nature. The literature on the etiology and pathogenesis of hypercementosis is sparse (Suter, 2011). It is known that root cementum is a dynamic tissue that shows progressive thickening over life, with variations among tooth groups and tooth surfaces. Hypercementosis may be completely asymptomatic and found on routine radiographic examination (Zhou, 2012). Hypercementosis is regarded essentially in adults, and the frequency perceived to be increasing with maturing age (Patil, 2015). Many of these cases authenticate a positive family history that advocate a hereditary influence. The excessive cementum may be hypocellular or cellular

cementum resembling osteocementum. Often this excessive deposited cementum material is systemized in concentric layers and may be applied over the entire root or limited to the root apex (Suter, 2011). Root thickening may cause occasional difficulty during extraction of such tooth necessitating transalveolar extraction procedures. In Paget's disease, the cementum formation can also be disorganized, resulting in hypercementosis, even involving the periodontal ligament space (Napier Souza, 2004; Basdra, 1997 and Zustin, 2010).

Conclusion

Hypercementosis is conjoined with a number of etiological factors, which may be local or systemic in nature. This condition epitomize an adaptive change of the periodontal ligament, portrayed by excessive cementum thickness on the root surface. In conclusion, the concomitant occurrence of hypercementosis and periodontitis suggests that periodontitis also appears to be a predisposing factor for hypercementosis development. However, it is unclear whether one or several factors may have a role in the pathogenesis of multiple hypercementosed tooth that warrants further investigation. In the present case, no etiologic factor could be found for the extensive hypercementosis. The final diagnosis of hypercementosis in this case was challenging because of the atypically large area of involvement, including multiple teeth, as well as secondary inflammation of the marginal and apical periodontal spaces. Hypercementosis is a rare phenomenon which may be identified with routine radiographs. In such cases, additional precautions to be taken in treatment planning like lab investigations to rule out any systemic medical conditions and transalveolar extractions.

Financial support and sponsorship: Nil.

Conflicts of interest: There are no conflicts of interest.

REFERENCES

- Basdra, E.K., Stellzig, A., Komposch, G. 1997. Generalized hypercementosis in a young female patient. *Oral Surg Oral Med Oral Pathol Oral Radiol Endod.*, 83(4): 418-419.
- Jeddy, N., Radhika, T., Saravanan, R., Prabakar, R. 2014. Localized multiple cemental excrescences: A rare presentation of hypercementosis. *J Clin Diagn Res.*, 8: ZD16-7.
- Leider, A.S., Garbarino, V.E. 1987. Generalized hypercementosis. *Oral surg Oral Med Oral Pathol.*, 63 (3):375-380.
- Napier Souza, L., Monteiro, Lima Junior, S., Garcia Santos Pimenta, F.J., Rodrigues Antunes Souza, A.C., Santiago Gomez, R. 2004. Atypical hypercementosis versus cementoblastoma. *Dentomaxillofac Radiol.*, 33(4): 267-270.
- Noonan, V.L., Gallagher, G., Kabani, S., Kemp, S. 2008. Hypercementosis. *J Mass Dent Soc.*, 56: 45.
- Patil, S.R., Yadav, N. 2015. Generalized hypercementosis with multiple missing teeth in a young female: A rare case report. *Int J Health Allied Sci.*, 4: 178-80.
- Seed, R., Nixon, P.P. Generalised hypercementosis: A case report. *Prim Dent Care*
- Suter, V.G., Reichart, P.A., Bosshardt, D.D., Bornstein, M.M. 2011. Atypical hard tissue formation around multiple teeth. *Oral Surg Oral Med Oral Pathol Oral Radiol Endod.*, 111: 138-145.

- Weinberger, A. 1954. The clinical significance of hypercementosis. *Oral Surg Oral Med Oral Pathol.*, 7:79-87.
- Zhou, J., Zhao, Y.F., Xia, C.Y., Jiang. L. 2012. Periodontitis with hypercementosis: report of a case and discussion of possible aetiologic factors. *Australian Dental Journal*, 57: 511-514.
- Zustin, J., Friedrich, R.E. 2010. Hypercementosis and Odontogenic Epithelial Hyperplasia Associated with a Tooth Root Remnant Mimicking a Neoplasm. *A Case Report. In Vivo.*, 24(4): 571-574.
