



RESEARCH ARTICLE

COMPARISON OF FIBRIN GLUE AND SUTURES FOR ATTACHING LIMBAL CONJUNCTIVAL
AUTOGRAFT AFTER PTERYGIUM EXCISION

*Prashanth, B. M.S., Narendra P Datti, M.S., Kanthamani, Sangeetha, T., Shrey Maheshwari,
Bhavya Reddy and Dildar Singh

Department of Ophthalmology, Sri Devaraj Urs Academy of Higher Education and Research, Tamaka, Kolar

ARTICLE INFO

Article History:

Received 09th December, 2016
Received in revised form
20th January, 2017
Accepted 05th February, 2017
Published online 31st March, 2017

Key words:

Pterygium, Fibrin glue,
Conjunctival autograft,
Operating time.

ABSTRACT

Purpose: To compare efficacy of fibrin glue versus conjunctival suturing after pterygium excision in terms of operating time, postoperative symptoms, signs, recurrences & safety in terms of anaphylactic reaction and disease transmission (HIV, HBsAG).

Materials and Methods: This hospital based prospective study was conducted at R.L. Jalappa Hospital and Research Centre, Tamaka, Kolar between January 2015 and June 2016. Study included 100 patients fulfilling inclusion criteria and all were worked up according to the protocol. Patients were randomly allocated to 2 groups, Group A (Fibrin group =50) and Group B (Suture group =50) who underwent pterygium excision with limbal conjunctival autograft with fibrin glue and pterygium excision with limbal conjunctival autograft with suture respectively. Patients were followed up at 1st day, 3rd day, 10th day, 1st month and 6th month for postoperative symptoms and signs like pain, foreign body sensation and lacrimation, sub conjunctival haemorrhage, graft retraction/gaping and recurrences.

Results: Mean age of Limbal conjunctival auto graft with suture was 52.39 years and 53.22 years in fibrin glue group. Mean operating time was 43.00 minutes in the suture group compared to fibrin glue group which was 22.78 minutes. Patients in fibrin glue group had less symptoms of pain, foreign body sensation, lacrimation, sub conjunctival haemorrhage and graft gaping compared to suture group. Recurrence was noted in 3 & 1 patient in suture group & fibrin glue group respectively at the end of six-month follow-up period.

Conclusion: Fibrin glue was found to be a safe and effective method for attaching limbal conjunctival autograft following pterygium excision. Its use results in a shorter operating time, less post-operative discomfort, inflammation, recurrence and no anaphylactic reaction and disease transmission like HIV and HBsAG compared to suturing.

Copyright©2017, Prashanth et al. This is an open access article distributed under the Creative Commons Attribution License, which permits unrestricted use, distribution, and reproduction in any medium, provided the original work is properly cited.

Citation: Prashanth, B. M.S., Narendra P Datti, M.S., Kanthamani, Sangeetha, T., Shrey Maheshwari, Bhavya Reddy and Dildar Singh, 2017. "Comparison of fibrin glue and sutures for attaching limbal conjunctival autograft after pterygium excision", *International Journal of Current Research*, 9, (03), 47541-47544.

INTRODUCTION

Pterygium is a frequently occurring ocular surface lesion with characteristic wing shaped fleshy growth, encroaching from conjunctiva upon the cornea. Although simple to excise, high rates of recurrence make its management challenging. The prevalence of pterygium in India ranges from as low as 0.75% to as high as 10.42% in different states and an overall average in prevalence being 5.2% (Singh et al., 1997). Pterygium is associated with decreased visual acuity due to involvement of visual axis, irregular astigmatism, extra ocular motility restriction and cosmetic intolerance (Yanoff et al., 2008). UV light induced localised damage to limbal-conjunctival cells and thus deficiency has been the most recent concept for causation.

*Corresponding author: Prashanth, B. M.S.,
Department of Ophthalmology, Sri Devaraj Urs Academy of Higher Education and Research, Tamaka, Kolar

Although the best technique for a successful outcome after pterygium excision is yet to be determined, in recent years, pterygium excision with limbal-conjunctival autograft with sutures has become a standard procedure, as it is associated with least recurrence rate. However it requires higher surgical expertise and is associated with disadvantages including prolonged operative time and suture related complications such as button holes, dellen ulcer, suture abscesses, symblepharon, granuloma formation, tissue necrosis and graft dehiscence (Figueiredo et al., 1997). After excision there is chemotaxis and influx of polymorphonuclear leukocytes, which then release the angiogenic factor which is the stimulus for neovascularisation and recurrence (Koranyi et al., 2004). Fibrin glues have been used in an array of ophthalmic procedures such as conjunctival closure in strabismus, vitreoretinal and glaucoma surgery (Panda et al., 2005). Because of its biological and biodegradable properties, fibrin

based adhesives may be used to attach the conjunctival autograft without inducing inflammation (Chan and Boisjoly, 2004). Tissue adhesives of different types had been used in previous studies to attach conjunctival grafts and compared with the use of sutures, were associated with a shorter operative time and reduced postoperative complaints (Harvey *et al.*, 2005; Vichare *et al.*, 2013; Javadekar *et al.*, 2013 and Arora *et al.*, 2010). Hence we conducted this study to compare the efficacy and safety of fibrin glue versus suturing for attaching limbal-conjunctival autograft after pterygium excision.

MATERIALS AND METHODS

This prospective randomised study was carried out between January 2015 and June 2016 on 100 pterygium patients fulfilling the selection criteria after informed consent. Patients with recurrent pterygium, temporal pterygium, pre-existing glaucoma, anticoagulant therapy, hypersensitivity to human blood products, Immune system disease, eyelid or ocular surface diseases eg- blepharitis, sjogren syndrome and dry eye and ocular trauma were excluded from this study. After detailed ocular and systemic history, a thorough ocular examination including visual acuity, refraction, keratometry, ocular movements, fluorescein staining and slit lamp examination is done. The patients were randomly allocated to 2 groups, Group A (50) and Group B (50) by using computerised random number method / table. Group A underwent pterygium excision followed by autologous limbal conjunctival graft attachment by fibrin glue and Group B underwent pterygium excision followed by autologous limbal conjunctival graft attachment by nylon 10-0 sutures. Operating time was noted for all patients in each group. Postoperatively both the groups received sub conjunctival injection of gentamycin and dexamethasone given away from the graft site followed by application of antibiotic ointment eye patch for 24 hours. Postoperatively the patient was evaluated on 1st day, 3rd day, 10th day, 1st month and 6th month. At each postoperative visit, the patients from both the groups were examined for the symptoms and signs like pain, foreign body sensation and lacrimation, subconjunctival haemorrhage, graft retraction/gaping and recurrences and blood test for HIV and HBsAG at 3rd and 6th month.

The assessment of symptoms like pain, foreign body sensation and lacrimation was done using a questionnaire and the responses were graded on a scale of 0 to 3 as:

- Absent –no symptom
 - Mild –Patient had tolerable symptom and present occasionally
 - Moderate –Tolerable symptom present throughout the day or intolerable symptom present occasionally
 - Severe –Intolerable symptom present throughout the day
- Observed data were compiled and analysed followed by comparison of the results with previously published studies.

RESULTS

The study included 100 patients with mean age of 53.22 years (range 25 -73) in fibrin glue group (Group A) and 52.39 years (range 23 -84) in the conjunctival autograft group (Group B).

Group A comprised of 7 (14%) male and 43 (86%) females whereas group B had 18 (36%) male and 32 (64%) female. Age and sex distribution is presented in table 1 & 2 respectively. Graph 1 shows the mean operating time to be 22.78 minutes in fibrin glue group and 43.00 minutes in the suture group. There was statistically significant difference between the operating times between the two groups with results favouring the fibrin glue group. (p=0.001)

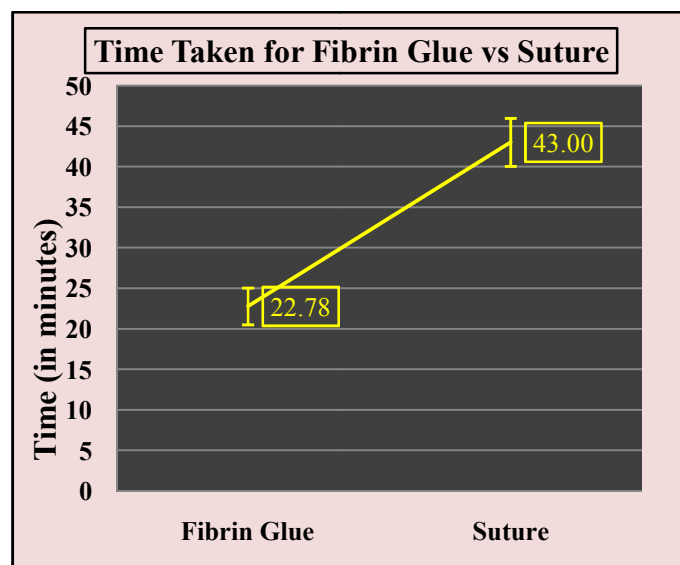
Table 1. Age distribution of patients studied

Age*	Category	Mean	Standard deviation	Range
	Fibrin Glue	53.22	13.07714	25 to 73
	Suture	52.39	14.3567	23 to 84

Sl no	Parameters	Fibrin group	Suture group	P value
-------	------------	--------------	--------------	---------

Table 2. Gender distribution of patients studied

Category	Fibrin Glue	Suture
Males	7	18
Females*	43	32



Graph 1. Operating time in both groups

While comparing two groups for symptoms and sign on subsequent postoperative follow-up, there were more patients with pain, foreign body sensation & lacrimation in the suture group which was statistically significant. Table 3-6

Table 3. Postoperative day 1 findings

Sl no	Parameters	Fibrin group	Suture group	P value	
1	Pain	Grade 0	14	0	0.0001
		Grade 1	34	45	
		Grade 2	2	5	
		Grade 3	0	0	
2	FB sensation	Grade 0	1	0	< 0.0001
		Grade 1	39	0	
		Grade 2	10	50	
		Grade 3	0	0	
3	Lacrimation	Grade 0	1	0	< 0.0001
		Grade 1	40	9	
		Grade 2	9	36	
		Grade 3	0	5	

Table 4. Postoperative day 3 findings

Sl no	Parameters		Fibrin group	Suture group	P value
1	Pain	Grade 0	35	32	>0.05
		Grade 1	14	18	
		Grade 2	1	0	
		Grade 3	0	0	
2	FB sensation	Grade 0	35	0	< 0.0001
		Grade 1	10	39	
		Grade 2	5	11	
		Grade 3	0	0	
3	Lacrimation	Grade 0	30	7	< 0.0001
		Grade 1	19	41	
		Grade 2	1	2	
		Grade 3	0	0	

Table 5. Postoperative day 10 findings

Sl no	Parameters		Fibrin group	Suture group	P value
1	Pain	Grade 0	45	43	0.46
		Grade 1	4	6	
		Grade 2	1	1	
		Grade 3	0	0	
2	FB Sensation	Grade 0	45	14	< 0.0001
		Grade 1	5	33	
		Grade 2	0	3	
		Grade 3	0	0	
3	Lacrimation	Grade 0	45	32	< 0.05
		Grade 1	4	18	
		Grade 2	1	0	
		Grade 3	0	0	
4	Sub conjunctival Haemorrhage		0	1	0.31

Table 6. Postoperative findings – 1st month

Sl no	Parameters		Fibrin Group	suture group	p-value
1	Pain	Grade 0	48	48	0.44
		Grade 1	2	1	
		Grade 2	0	1	
		Grade 3	0	0	
2	FB Sensation	Grade 0	50	39	0.001
		Grade 1	0	10	
		Grade 2	0	1	
		Grade 3	0	0	
3	Lacrimation	Grade 0	49	45	<0.05
		Grade 1	1	5	
		Grade 2	0	0	
		Grade 3	0	0	
4	Graft Gaping		0	1	0.31

Table 7. Postoperative findings – 6 months

Sl no	Parameters	Fibrin group	Suture group
1	Recurrence	1(2%)	3(6%)
2	Anaphylactic reaction	NO	NO

There was no statistically difference in graft gaping between two groups on postoperative day 1, day 3, day 10 and 1 month. (P = 0.31). Table 6. Recurrence was seen in 3 (6%) patients at the end of 3rd month in suture group and 1 (2%) recurrence in fibrin glue group Table 7. Fibrin glue was found to be safe as there was no anaphylactic reaction and disease transmission like HIV and HBsAg noted at the end of 6 months follow-up. Table 7

DISCUSSION

Conjunctival autograft surgery is generally regarded as the procedure of choice for the treatment of primary and recurrent pterygium, because of its efficacy and long term safety. A free

conjunctival graft is harvested from the superior bulbar conjunctiva and is attached in place over the bare scleral defect. The conjunctival autograft can be attached with sutures, fibrin glue, electrocautery or autologous blood (Ang *et al.*, 2007). Recently Fibrin glue has been used for the attachment of conjunctival graft, that mimics coagulation cascade resulting in its adhesive capability (Siedentop *et al.*, 2001). It reduces the total surgical time required (to place sutures is saved) (Tidrick *et al.*, 1944) and has been found to lower the risk of postoperative wound infection, contrary to conventional suturing.¹⁴This can be attributed to accumulation of mucous and debris in sutures which may act as a nidus for infection.

Mean operating time was 22.78 minutes in fibrin glue group whereas it was more in the suture group of patients which was 43.00 minutes which was statistically significant. This is comparable with other studies.

Mean Operating Time			
Sl no	Study	Fibrin glue	Suture
1	Our study	22.78 minutes	43.00 minutes
2	Koranyi <i>et al</i>	9.7 minutes	18.5 minutes
3	Karalezli <i>et al</i>	15.7 minutes	32.5 minutes
4	Cha DM <i>et al</i>	27.71 minutes	43.30 minutes
5	Arora <i>et al</i>	13-16 minutes	25-35 minutes

In the present study on examination significantly lower pain was reported by patients in the fibrin glue group, mild pain=34 (68%), moderate=2 (4%) and 14 (28%) patients did not experience pain when compared to group 2, wherein majority 45 (90%) experienced mild pain and 5 (10%) had moderate pain (*P<.0001). However, during the follow up at day 3, day 10 and 1st month, post-operative pain reported by patients was similar in both the groups (P>.05). This is comparable with other study by Vichare *et al.* who noted that pain was less in fibrin glue than those with suture group (P>0.05) ⁽⁸⁾and similarly a study by Ratnalingam *et al.* noted that on a 10-point numerical rating scale, both the fibrin adhesive and the suture group had low median pain scores. However, the pain scores immediately post- surgery and 1 week post-surgery were significantly lesser in the fibrin adhesive group (P>.05) (Ratnalingam *et al.*, 2010). In the present study, foreign body sensation in fibrin glue group was significantly better when compared to suture group as shown in table 3-6. This is comparable with other studies. Study from India by Bisen *et al.* reported that, in fibrin glue patients, post -operative foreign body sensation of mild and moderate grade was seen in 54.54% and 36.36% of eye respectively.

At the end of 1 month, 90.91% had no foreign body sensation and 9.09% had mild sensation. Compare to this in suture group, 100% patients had severe foreign body sensation on day 1 (P<.001) (Bisen *et al.*, 2009). Similar results were reported in a study by Bahar *et al* which observed foreign body sensation in 20% fibrin glue patients while in suture group 60% patients felt foreign body sensation on 1st post- operative day (P<0.001), (Bahar, 2008). In the present study lacrimation was significantly less in fibrin glue group at day 1, day 3, day 10 and 1st month (P<0.05). This is comparable with other studies which noted lacrimation to be lower in fibrin group than suture group (Vichare *et al.*, 2013; Ratnalingam *et al.*, 2010 and UyHs, 2005). In the present study one patient in the suture group had graft gaping/retraction of 1 mm at the nasal site of the graft due to loose suture. The patient was closely examined on subsequent follow-up visits and re-epithelialisation of the conjunctival defect was seen after 1st month follow-up.

Graft Gaping			
Sl no	Studies	Fibrin glue	Suture
1	Our study	0	1
2	Vichare N et al	3	5
3	UY et al	0	1
4	Marticoarena	2	0

In the present study three cases in suture group and one case in fibrin glue group reported with recurrence at the end of third and six month follow up period. This is comparable with other studies.

Recurrence			
Sl no	Studies	Fibrin glue	Suture
1	Our study	1 (2%)	3 (6%)
2	Vichare N et al	1 (3.3%)	3 (10%)
3	RituArora et al	0	2
4	Koranyi et al	2 (8%)	4 (20%)
5	Karalezli et al	4%	12%
6	Farid et al	3.7%	20%

Conclusion

Thus we conclude that fibrin glue is a safe and effective method for attaching limbal conjunctival autograft following pterygium excision. Its use results in a shorter operating time, less post-operative discomfort and inflammation compared to suturing and there was less recurrences of pterygium in fibrin glue compared to sutures. Fibrin glue use was also found to be safe as there is no anaphylactic reaction and disease transmission like HIV and HBsAG.

REFERENCES

- Ang, L.P., Chua, J.L., Tan, D.T. 2007. Current concepts and techniques in pterygium treatment. *Curr Opin Ophthalmol.*, 18(4):308-13.
- Arora, R., Goyal, J., Kanj, J., Seetaram, S. 2010. Fibrin glue Vs Vicryl Suture in Limbo Conjunctival Autograph in The Management of Primary Pterygium. *Cornea Session*, III:263-265.
- Bahar, I., Weinberger, D., Dan, G., Avisar, R. 2006. Pterygium surgery fibrin glue versus vicryl sutures for conjunctival closure. *Cornea*, Dec; 25(10):1168-1172.
- Bisen, R.K., Desai, R.J., Mehta, F., Billore, O.P., Randeri, J.K. and Jain, P., et al. Comparison of cut and paste (No Suture) with cut and suture Technique of pterygium surgery. *New Delhi; AICO 2009 Proceedings*; 2009.
- Cha, D.M., Kim, K.H., Choi, H.J., Kim, M.K., Wee, W.R. 2012. A comparative study of the effect of fibrin glue versus sutures on clinical outcome in patients undergoing pterygium excision and conjunctival autografts. *Korean J Ophthalmol*, Dec;26(6): 407-13
- Chan, S.M., Boisjoly, H. 2004. Advances in the use of adhesives in ophthalmology. *Curr Opin Ophthalmol*, 15:305-10.
- Farid, M., Pirnazar, J.R. 2009. Pterygium recurrence after excision with conjunctival autograft: a comparison of fibrin tissue adhesive to absorbable sutures. *Cornea*, Jan; 28(1):43-45.
- Figueiredo, R. S., Cohen, E. J., Gomes, J. A. P., Rapuano, C. J. and Laibson, P. R. 1997. Conjunctival Autograft for pterygium surgery: how well does it prevent recurrence? *Ophthalmic Surg Lasers*, 28:99-104.
- Harvey, S.U., Johan, M.G.R., Flores, J.D.G., Ruben, L.B.S. 2005. Comparison of fibrin glue and sutures for attaching conjunctival autografts after pterygium excision. *Ophthalmology*, 112:667-71.
- Javadekar, S.D., Deokrishna, S., Sharma, A. 2013. Autologous Fibrin Glue versus Sutures for Conjunctival Autografting in Pterygium Surgery. *International Journal of Recent Trends in Science and Technology*, 7:01-05.
- Karalezli, A. C. Kucukerdinmez, Y. A Akova, et al. 2008. Fibrin glue versus sutures for conjunctival. *BR J Ophthalmol*, 92:1206-10.
- Koranyi, G., Seragard, S., Kopp, E.D. 2004. Cut and paste: a no suture, small incision approach to pterygium surgery. *Br J Ophthalmol*, 88:911-914.
- Maicoarena, J., Rodriguez-Ares, M.T., Tourino, R., Mera, P., Valladares, M.J., Martinez-de-la-Casa, J.M., et al. 2006. Pterygium surgery; conjunctival autograft using fibrin adhesive. *Cornea*, 25:34-6.
- Marone, P., Monzillo, V., Segu, C., Antoniazzi, E. 1992. Antibiotic-impregnated fibrin glue in ocular surgery: In vitro antibacterial activity. *Ophthalmologica.*, 213:12-5.
- Panda, A., Kumar, S., Kumar, A., Bansal, R., Bhartiya, S. 2009. Fibrin glue in ophthalmology. *Indian J Ophthalmol*, 57:371-379.
- Ratnalingam V, Eu AL, Ng GL, Taharin R, John E. Fibrin adhesive is better than sutures in pterygium surgery. *Cornea* 2010;29:485-9.
- Siedentop, K.H., Park, J.J., Shah, A.N., Bhattacharya, T.K., O'Grady, K.M. 2001. Safety and efficacy of currently available fibrin tissue adhesives. *Am J Otolaryngol.*, 22:230-5.
- Singh, M.M., Murthy, G.V., Venkatraman, R., Rao, S.P., Nayar, S. 1997. A study of ocular morbidity among elderly population in a rural area of central India. *Indian J Ophthalmol.*, 45(1):61-5.
- Tidrick, R.T., Warner, E.D. 1944. Fibrin fixation of skin transplant. *Surgery.*, 15:90-5.
- UyHs, Reyes JMG, Flores JDG, Lim-Bon-Siong R. 2005. Comparison of fibrin glue and sutures for attaching conjunctival autografts after pterygium excision. *Ophthalmology*, April;112(4):667-67.
- Vichare, N., Choudhry, T. and Arora, P. A comparison between fibrin sealant and sutures for attaching conjunctival autograft after pterygium excision *Medical journal armed forces India* 2013;69:151-155.
- Yanoff, M, Duker, J. 2008. Textbook of ophthalmology. 2nd Edition. Elsevier publication, p.446-7.
