



## RESEARCH ARTICLE

### ROLE OF TRIPLE PHASE CT IN EVALUATION OF FOCAL LIVER LESIONS

\*Dr. Divya Bagoria, Dr. Reena Mathur, Dr. Avinash Gupta, Dr. Sumitra Choudhary  
and Dr. Jaya Pamnani

JLN Medical College, Ajmer

#### ARTICLE INFO

##### Article History:

Received 14<sup>th</sup> December, 2016  
Received in revised form  
20<sup>th</sup> January, 2017  
Accepted 09<sup>th</sup> February, 2017  
Published online 31<sup>st</sup> March, 2017

##### Key words:

Triple phase CT,  
HCC,  
AVM-Arteriovenous malformation.

#### ABSTRACT

**Aims and Objectives:** To study the role of triple phase CT scan in detection, characterisation, differentiation and diagnosis of liver lesions. To study the enhancement patterns of various liver lesions on triple phase CT scan.

**Materials and Methods:** A Hospital based prospective study was conducted on 100 patients having clinical suspicion of liver pathology or with suspected/proved focal liver lesions by other imaging modalities were referred to CT for diagnosis had undergone triphasic CT for evaluation of liver lesions in the department of Radiodiagnosis, JLN Medical College and Associated groups of hospital. After image acquisition different phases were evaluated in detail to identify lesions and characterise their nature. Then lesions were classified statistically to derive the conclusions.

**Results:** There were 59 benign cases and 41 malignant cases out of total 100 patients. Metastases and hemangiomas were the most common detected lesion in 20% of patients (total 40%). There were 16% cases of HCC, 12 % cases of abscess, 9 % cases of simple cyst, 8% cases of hepatic trauma, 4% cases of hydatid cyst, focal fatty infiltration, and cholangiocarcinoma each and 1% cases of FNH, hepatoblastoma and AVM each. On triple phase CT scan, hemangioma (except one) showed peripheral nodular enhancement followed by centripetal filling Metastasis to liver were hypoenhancing on all post contrast phases (18 out of 20).

**Conclusion:** Triple phase CT is helpful in confident diagnosis of hepatic lesion. It has an indispensable role in characterising, evaluating and differentiating various hepatic lesions which helps in guiding appropriate management plan with proper surgical triage.

Copyright©2017, Dr. Divya Bagoria et al. This is an open access article distributed under the Creative Commons Attribution License, which permits unrestricted use, distribution, and reproduction in any medium, provided the original work is properly cited.

Citation: Dr. Divya Bagoria, Dr. Reena Mathur, Dr. Avinash Gupta, Dr. Sumitra Choudhary and Dr. Jaya Pamnani. 2017. "Role of triple phase ct in evaluation of focal liver lesions", *International Journal of Current Research*, 9, (03), 48075-48078.

## INTRODUCTION

CT scan is very helpful to evaluate focal as well as diffuse liver pathology. Characterization of focal liver lesions at CT was based mainly on their appearance during the portal venous phase but nowadays with helical CT imaging during the arterial phase has become possible. Triple phase CT is based on various enhancement patterns of lesions in different phases. On NECT liver tumors usually are not visible. In the arterial phase hypervascular tumors will enhance. In the portal venous phase hypovascular tumors are detected. In the equilibrium phase these lesions will become hyperdense or hypodense to the normal liver.

## AIMS AND OBJECTIVES

- To study the role of triple phase CT scan in detection and diagnosis of liver lesions.
- To study the role of triple phase CT scan in differentiation of liver lesions.

- To study the enhancement patterns of various liver lesions on triple phase CT scan.

## MATERIALS AND METHODS

**Study design:** Hospital based prospective study on 100 patients.

### Inclusion criteria

- Patients of any age group having clinical suspicion of liver disease.
- Patients of any age group with suspected/proved focal liver lesions by other imaging modalities.

### Exclusion criteria

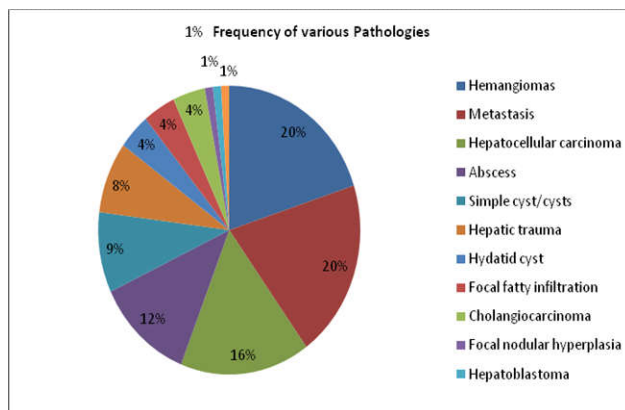
- All pregnant women with suspected liver disease.
- All patients with hypersensitivity to CT contrast agents and in patients in whom CT is contraindicated due to any other reason.

The entire liver was scanned in craniocaudal direction and

portal (70 seconds) and equilibrium phases (after 8-10 minutes of contrast administration). After image acquisition different phases were evaluated in detail to identify lesions and characterise their nature. Then lesions were classified statistically to derive the conclusions.

## OBSERVATIONS AND ANALYSIS

- Following observations made according to age, sex, symptoms and CT appearances and the study data were analyzed.
- In present study the largest age group is 41-50 years (26 % of all patients).
- Most common presentation is abdominal pain- 92 % followed by anorexia – 34%.
- Both lobes were involved in 42% of patients followed by 38% with right lobe involvement and rest had left lobe involvement.
- 55 % cases showed multiple lesions and 45% had solitary lesions.
- In my study there were 59 benign cases and 41 malignant cases out of total 100 patients. Metastases and hemangiomas were the most common detected lesion in 20% of patients (total 40%). There were 16% cases of HCC, 12 % cases of abscess, 9 % cases of simple cyst/cysts, 8% cases of hepatic trauma/laceration, 4% cases of hydatid cyst, focal fatty infiltration, and cholangiocarcinoma each and 1% cases of FNH, hepatoblastoma and AVM each.



98% of patients with hemangiomas showed peripheral nodular enhancement. 90% of patients with metastasis showed hypovascular hypoenhancing lesions. 75 % of patients with HCC had multifocal lesions. 10/16 patients had portal vein thrombosis.

### CT appearance OF HCC

CT appearance	No. of Patients	Percentage
Solitary	4	25%
Multifocal	12	75%
Diffuse	0	0
Hypodense on Noncontrast scan	12	75%
Isodense on Noncontrast scan	4	25%
Hyperenhancing on arterial phase with washout	16	100%
Hypo- or isoenhancing on arterial phase with or without washout	0	0%
Necrosis- present	15	93.75%
Necrosis- absent	1	6.25%
Tumor in portal vein- present	10	62.5%
Tumor in portal vein- absent	6	37.5%

### CT Appearance of Cholangiocarcinoma

CT appearance	No. of Patients	Percentage
Mass forming	2	50%
Periductal infiltrating	1	25%
Intraductal	1	25%

## DISCUSSION

The present study was carried out on 100 patients. Youngest patient was 7 years old having hepatoblastoma and the oldest patient was 80 year old having HCC.

**Hemangiomas:** On triple phase CT scan, all the lesions (except one) showed peripheral globular (nodular) enhancement followed by gradual filling toward the centre (filling in) and prolonged enhancement on the equilibrium phase. Absence of contrast washout in delayed phase and nodular peripheral centripetal enhancement are useful to differentiate hemangiomas from hypervascular liver metastases. This is in accordance with a study done by D F Leslie<sup>61</sup> and Kim T<sup>56</sup>. Triple phase CT scan correctly diagnosed all the cases (100%) of hemangiomas.

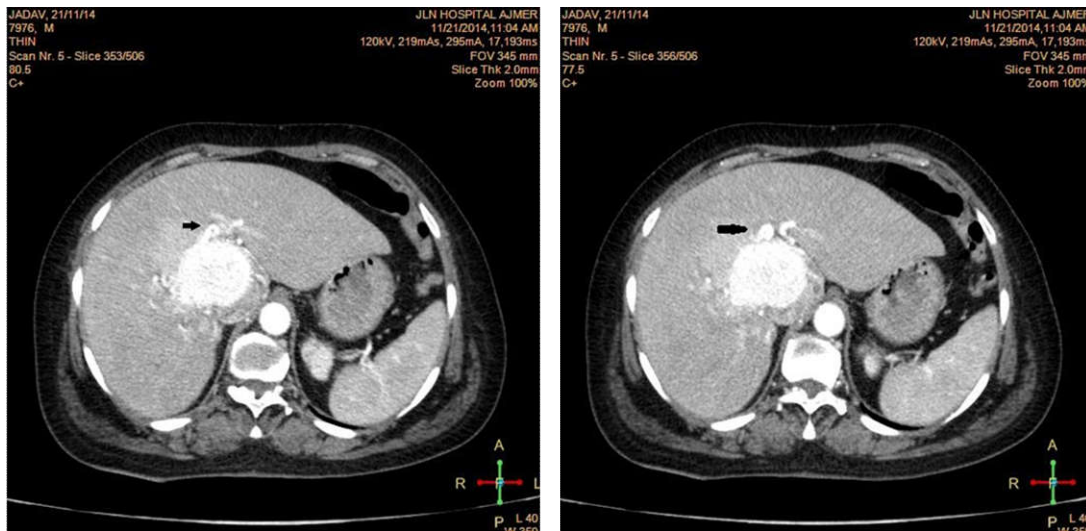
**Metastasis:** The lesions appear hypoenhancing on all post contrast phases in eighteen patients (90%). Hypodense lesion on noncontrast CT and less enhancement than surrounding liver on postcontrast studies is the most common appearance of hepatic metastases. This was in accordance with a study done by Soyer P<sup>64</sup>. One patient showed lesions as hyperdense on all phases in relation to fatty liver. One (5%) showed lesions as hyperenhancing on arterial phase images which became hypodense due to washout in delayed phase images.

**Hepatocellular carcinoma:** All patients had mass of size more than 20 mm with hyperenhancement in late arterial phase and early washout and 10 patients had tumor in portal vein. Typical pattern of enhancement in form of hyperenhancement on arterial phase and iso to hypoenhancement on portal venous and delayed phase was detected in all 16 (100%) patients of hepatocellular carcinoma. In 10 (62.5%) patients tumor in portal vein (or its branches) was present. In two patients portal cavernoma formation was noted due to tumor in portal vein. Capsular enhancement on delayed phase images was noted in two patients (12.5%).

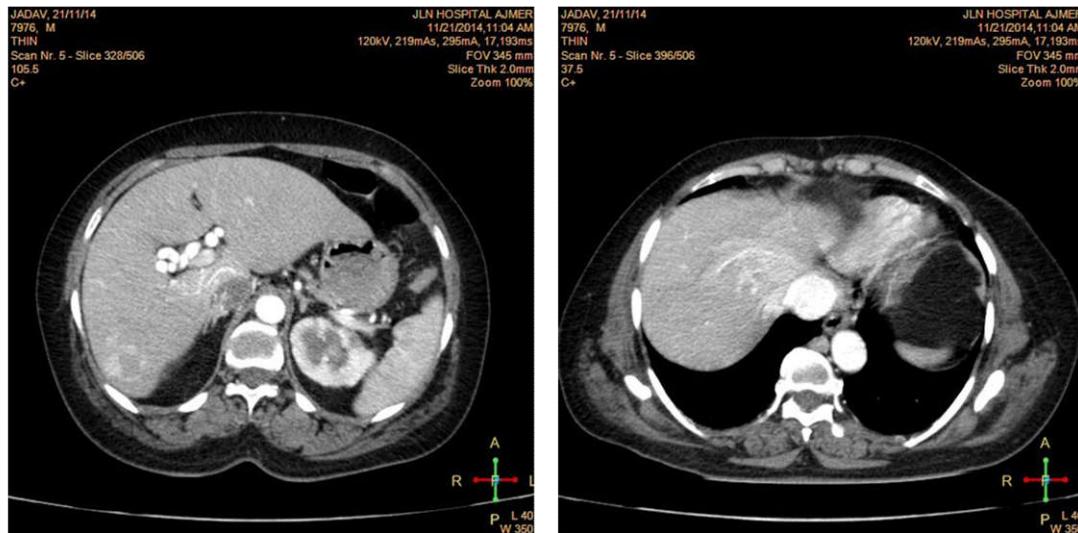
**Abscess:** On CT scan, they were hypodense on plain scan & showed peripheral enhancement on contrast study. 2 patients (16.66 %) showed air foci within the abscess cavity out of which one patient had broncho-hepatic fistula. Three patients transient hepatic attenuation difference (THAD). One patient showed double target pattern of enhancement with central hypodensity surrounded by enhancing rim and outermost layer showing hypodensity. Two patients (16.66%) showed presence calcification in abscess, one of them was almost completely replaced by calcification.

**Simple cyst/cysts:** On CT scan, they appeared as non-enhancing hypodense lesions (HU: 0 to 15) with smooth margins.

**Hepatic trauma:** All patients had hepatic laceration. 4 patients had associated intraparenchymal hematoma and 6 patients had associated subcapsular hematoma. All patients had



In images arrows show feeders



All images are of arterial phase, Caudate lobe is involved images show tortuous right hepatic artery is noted and IVC shows similar attenuation as aorta

One patient showed pseudoaneurysms arising from a segmental hepatic artery adjacent to the lacerated liver parenchyma. Pseudoaneurysm of hepatic artery is one of the rare complications of hepatic trauma seen in 1%.<sup>68</sup>

**Hydatid cyst:** On CT scan hydatid cyst was noted as well defined cystic lesion. 2 patients showed daughter cysts within the main cyst.

**Focal fatty infiltration:** On CT scan all the lesions were correctly identified because of characteristic location, geographic margin, sharp demarcation from surrounding parenchyma and enhancement parallel to rest of the liver parenchyma.

**Cholangiocarcinoma:** Mass forming cholangiocarcinomas were hypodense on noncontrast scans. They showed heterogeneous minor peripheral enhancement with gradual central enhancement on dynamic postcontrast CT. Periductal infiltrating cholangiocarcinoma showed a mass at hilum encasing common duct with adjacent thickening of bile duct

walls and dilatation. Intraductal cholangiocarcinoma appeared as hypodense mass in the lumen of the CBD.

**Focal Nodular hyperplasia (FNH):** On CT scan, the lesion appeared well defined, lobulated, hypodense on plain study with more hypodense central scar. On arterial phase the lesion showed homogenous enhancement with non enhancing central scar. On portal venous phase images the lesion showed homogenous enhancement with non enhancing central scar. On delayed phase images enhancement of scar was noted.

**Hepatoblastoma:** It was noted in a 7 year old male patient with raised serum  $\alpha$ -fetoprotein.

The mass was hypodense on noncontrast CT images. The mass showed heterogeneous contrast enhancement and areas of necrosis on postcontrast CT images.

**Hepatic AVM**

## Summary

- Hemangioma:- Peripheral nodular enhancement.
- Metastases:- Hypodense lesion.
- HCC:- Hyperenhancement on arterial phase and iso to hypoenhancement on portal venous and delayed phase.
- Hepatic Abscess:-showed peripheral enhancement on contrast study.
- Trauma and hepatic abscess can have associated THAD.
- Hydatid cyst appears as cyst with daughter cysts, calcified cyst or cyst with endocyst.
- Fatty infiltration:- geographic area which parallels rest liver parenchymal enhancement
- Cholangiocarcinomas:- hypodense with delayed persistent enhancement.
- FNH:- homogenous enhancement with non enhancing central scar.
- Hepatoblastoma:- hypodense heterogenous enhancement with internal areas of necrosis.
- AVM:- enhancement almost equal to aorta on arterial phase.

## Conclusion

Triple phase CT is very effective in characterisation of focal hepatic lesions by accurately assessing size, location, enhancement patterns, necrosis, calcification and associated lymphadenopathy.

It is very less time consuming, cost-effective and highly sensitive. It can differentiate between benign and malignant lesions. It not only aids in diagnosis of liver lesions but helps in further assessment.

## REFERENCES

- David Sutton, Textbook of radiology and imaging, 7<sup>th</sup> edition, Vol. 1.
- Grainger, R.G. Allison D.J. Diagnostic radiology, 5<sup>th</sup> edition.
- Hind S. Alsaif *et al.* CT Appearance of Pyogenic Liver Abscesses Caused by *Klebsiella pneumoniae*; July 2011, *Radiology*, 260, 129-138.
- Hsien-Ping Lin, Wei-Chi Ho, Cheng-Chi Lee, Kwok-Ting Lin, and Yu-Chiang Lin; Infected Simple Hepatic Cysts — 3 Cases Report; *J Intern Med Taiwan*, 2009, 20, 373-377
- Leon Schiff, Eugene Schiff, Diseases of the liver, 6<sup>th</sup> edition, Lippincott.
- Mortelé KJ, *Ros PR.*; *Cystic focal liver lesions in the adult: differential CT and MR imaging features.* Radio Graphics, 2001; 21(4): 895–910.
- Zakim, Boyer, Reviewed by D H Adams 2003. Hepatology: a Textbook of Liver Disease, 4th edition, Saunders.

\*\*\*\*\*