



## CASE STUDY

### A RARE CASE OF GINGIVAL OVERGROWTH IN PRIMARY PULMONARY HYPERTENSION

**\*<sup>1</sup>Dr. Harish Chandran, <sup>1</sup>Dr. Nandini Manjunath, <sup>2</sup>Dr. Praveen J Shetty  
and <sup>3</sup>Dr. Merwyn Nithin Gonsalves**

<sup>1</sup>Department of Periodontics, AJ Institute of Dental Sciences, Mangalore

<sup>2</sup>Department of Cardiology, AJ Institute of Medical Sciences, Mangalore

<sup>3</sup>Department of Oral pathology, AJ Institute of Dental Sciences, Mangalore

#### ARTICLE INFO

##### Article History:

Received 16<sup>th</sup> January, 2017

Received in revised form

20<sup>th</sup> February, 2017

Accepted 07<sup>th</sup> March, 2017

Published online 30<sup>th</sup> April, 2017

##### Key words:

Calcium channel blocker,  
INR,  
Primary pulmonary hypertension,  
PT.

#### ABSTRACT

Primary Pulmonary Hypertension (PPH) is a life-threatening disease. Vasodilator drug have been used as a treatment but their efficacy is uncertain, a new treatment strategy using high dose of calcium channel blockers as one of the drug used. Nifedipine is one such drug of the family of calcium channel blockers that induced gingival overgrowth. Drug induced gingival overgrowth remains a significant problem for periodontologist. The pathogenesis of drug induced gingival overgrowth is uncertain and various risk factors and etiological agents like age, sex drug dose and duration, genetic factor and local factors. Management of such condition where it interferes with esthetic, function and occlusion includes non surgical or surgical intervention. This case report highlights the management of one such case of patient with primary pulmonary hypertension at dental office.

Copyright©2017, Dr. Harish Chandran et al. This is an open access article distributed under the Creative Commons Attribution License, which permits unrestricted use, distribution, and reproduction in any medium, provided the original work is properly cited.

Citation: Dr. Harish Chandran, Dr. Nandini Manjunath, Dr. Praveen J Shetty and Dr. Merwyn Nithin Gonsalves, 2017. "A rare case of gingival overgrowth in primary pulmonary hypertension", *International Journal of Current Research*, 9, (04), 49346-49349.

## INTRODUCTION

Primary pulmonary hypertension (PPH) is a disease of unknown etiology and poor prognosis. Platelet, endothelial and K1 channel dysfunction, as well as alterations in the prostaglandin metabolism have been suggested as probable causes of this disease. Patients with end stage PPH develop progressive right ventricular dysfunction, characterized by a hemodynamic pattern of decreased cardiac output and increased right atrial pressure and/or right ventricular end-diastolic pressure leading to heart failure and death. (Gomez *et al.*, 2001) Primary pulmonary hypertension has been defined by the world health organization (WHO) as pulmonary arterial hypertension of unknown cause. The prevalence of PAH varies among specific population but one study estimated that it affects 15 in 1 million adults. In 1987 Rich and Brundage conducted a preliminary study of the use of high doses of calcium channel blocking drugs in patient with primary pulmonary hypertension and found that when the drugs were titrated to produce maximal physiologic effects, there were substantial reductions in pulmonary artery pressure and pulmonary vascular resistance. (Rich and Brundage, 1987)

Many of the calcium channel blockers used as antihypertensive drugs have been effect on periodontal tissue causing gingival enlargement. Drugs that most commonly cause gingival enlargement include anticonvulsants, calcium channel blockers and immunosuppressants (Srivastava *et al.*, 2010). Nifedipine a dihydropyridine is one of the commonest antihypertensive drugs (calcium channel blockers) used to treat hypertension and some forms of angina. Nifedipine-induced gingival enlargement was first reported in 1984. The prevalence rates for nifedipine induced gingival overgrowth is ranging between 15% and 85% (Ellis *et al.*, 1993). The diagnosis of gingival overgrowth is made based on clinical examination and a history of the use of predisposing drugs (Bullon *et al.*, 2007). Gingival enlargement is usually noted within one to two months after the initiation of nifedipine therapy and appears to primarily affect interdental papilla and labial gingiva. The clinical management of the gingival overgrowth presents a continuous challenge. Treatment consists of periodic prophylaxis, scaling and, in more critical stages, periodontal surgery (Florio *et al.*, 2013).

## CASE REPORT

A 33 years old female patient was referred from the department of cardiology A J Institute of medical science Mangalore, with chief complaint of disfigured face and difficulty in eating due

\*Corresponding author: Dr. Harish Chandran,  
Department of Periodontics, AJ Institute of Dental Sciences, Mangalore

to abnormal gingival overgrowth. She is a known primary pulmonary hypertension patient which warrants her to be on Nicardia 20 mg (Antihypertensive) twice daily and Warfarin 2.5 mg (anticoagulant) once daily, lanoxin 0.25 mg (antihypertensive) once daily, aldactone 100 mg once daily and lasix 40 mg (diuretics) for life long. She has been taking the medication for the last 25 years. Patient noticed small gingival swelling 4 years back which gradually progressed to the present stage. Since last 2 years, preventing proper speech and mastication, causing inadequate lip apposition and poor esthetics which forced the patient to be on semisolid diet. On Intra oral examination, poor oral hygiene, generalized combined gingival overgrowth (grade III) on both upper and lower arches was seen (Figure 1) gingiva was soft to firm in consistency and the teeth were barely visible as the enlarged gingiva covered till the incisal/ occlusal third of the teeth. Grade I mobility was seen in lower anteriors due to gingival overgrowth. The teeth were malaligned and drifted apart. On the basis of medical, drug history and clinical findings, it was diagnosed as drug induced gingival over growth. The knowledge about signs and symptoms of primary pulmonary hypertension is required to be understood by the treating dentist. The major symptom of primary pulmonary hypertension includes shortness of breath, breathing with exertion, dizziness, fatigue, rapid breathing, cough, lethargy and swelling of legs.

Cardiologist consent was obtained with the necessary investigation like INR and Prothrombin time (PT) levels were assessed which was under normal limits and the hemoglobin level was found to be normal. Informed consent was obtained from patient before surgery. Surgical gingivectomy was planned in four sessions. Accordingly warfarin was withdrawn 4 days prior to procedure under physician guidance. Patient was posted for surgery in the morning hours and her regular medication and symptoms were monitored prior to the procedure. Quadrant wise gingival excision was performed under local anesthesia (LOX 2% without adrenaline) in 4 sessions with 1 week interval (figure 2). We had to stop the procedure intermittently due to the symptoms exhibited by the patient. However the soft tissue responded favorably during healing process and post op follow up was uneventful. The excised tissue was sent for biopsy and the report revealed hyperplastic and keratinized epithelium with highly fibrosed connective tissue with focal proliferation of fibroblasts and areas of proliferating blood vessels in a background of chronic inflammatory cells (Figure 3). After 1 month follow up (Figure 4, 5) gingival tissue was near normal and patient was able to masticate, swallow and speak and her warfarin was re started 1 day after the completion of surgery. Patient is on regular follow up, however recurrence of gingival overgrowth was explained to patient due to medications for her condition.

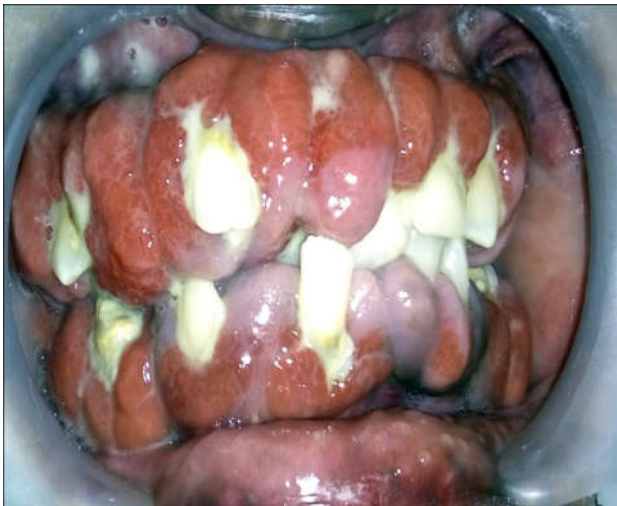

Figure 1. Intra oral picture showing the gingival overgrowth

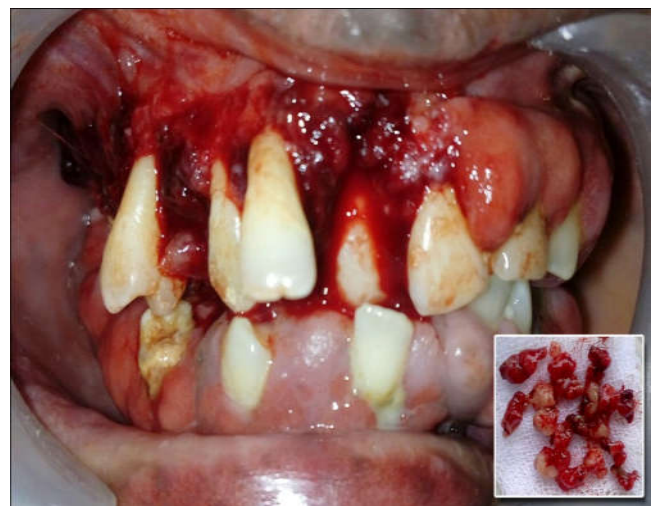

Figure 2. Surgical gingivectomy and excised tissue

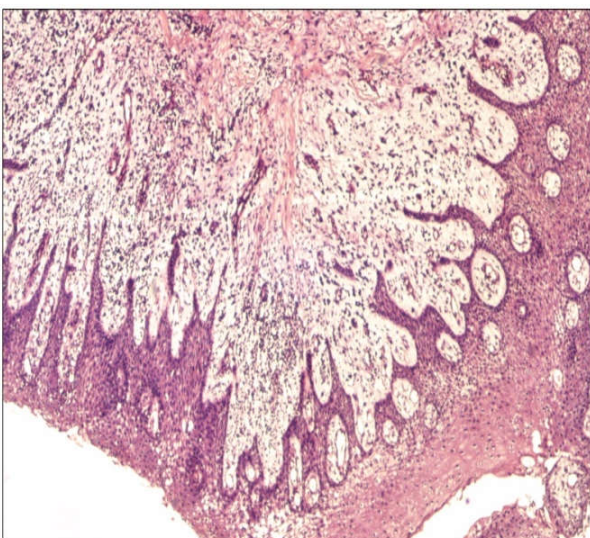


Figure 3. Histopathological view of the lesion at x10 magnification

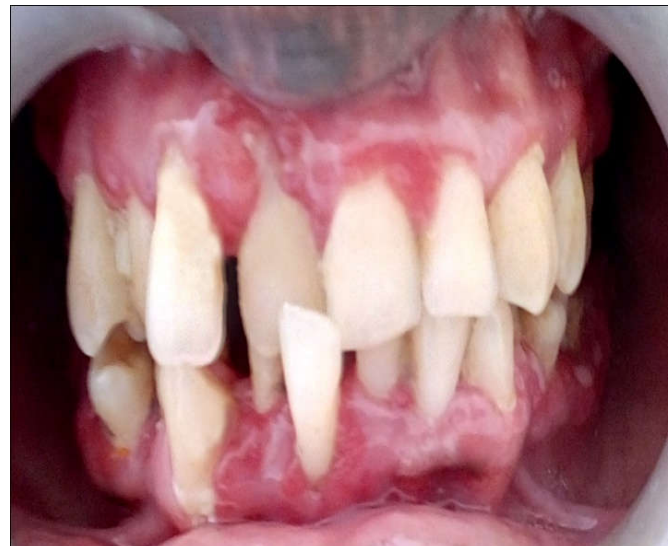
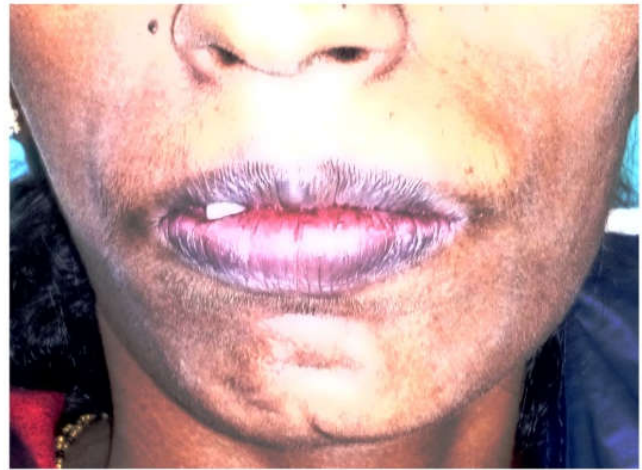
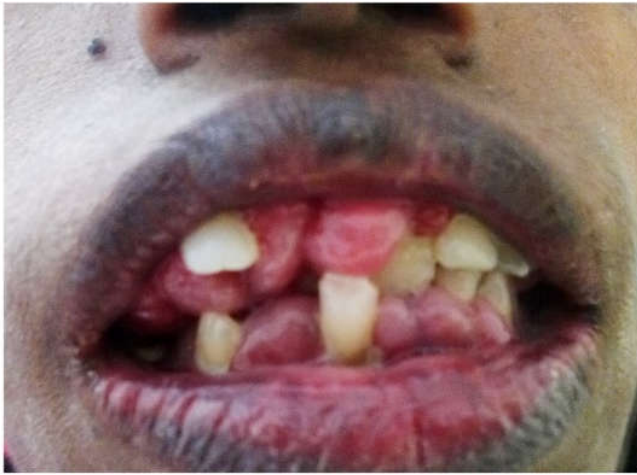
Figure 4. Intra oral views after 1 month follow up

PRE OPERATIVE



POST OPERATIVE

Figure 5. Extra oral views before and after

## DISCUSSION

Primary pulmonary hypertension is an uncommon disease that is progressive and incurable (Rich and Brundage, 1987). Nifedipine which is a calcium channel blocker used in the treatment of acute and chronic coronary insufficiency, including angina pectoris and refractory hypertension has been reported to induce gingival enlargement. There are various theories postulated in the pathogenesis of gingival enlargement due to nifedipine (Gelfand *et al.*, 1986). Huang *et al.*, have shown that inflammation is not the main factor in the pathogenesis of nifedipine-induced gingival overgrowth and concluded that, once the inflammation factor is eliminated, gingival overgrowth is influenced by androgen metabolism as demonstrated by the significant number of androgen receptor-presenting cells in gingival tissue of susceptible patients of the nifedipine group (Huang *et al.*, 2003). Factors like age, genetic predisposition, pharmacological actions, dose, plaque, and oral hygiene have been attributed for gingival enlargement in nifedipine-induced gingival enlargement. Other factors like increased production of heparin sulfate glycosaminoglycan (HSPG), basic fibroblast growth factor (bFGF), and transforming growth factor-beta (TGF- $\beta$ ) were found to be increased in nifedipine- and phenytoin-induced gingival hyperplasia (Hancock and Swan, 1992). Ellis *et al.* (1999) showed that plaque index and bleeding index on probing were strongly correlated with the severity of gingival overgrowth in patients using nifedipine. Meticulous, oral hygiene maintenance by patients using nifedipine may help control the degree of drug-induced gingival enlargement. The dose of the drug has an impact on gingival over growth. Ellis *et al.*, reported 15–316 times increase in nifedipine in the gingival crevicular fluid compared to plasma. So higher concentration of nifedipine in the gingival crevicular fluid could increase the severity of gingival enlargement (Ellis *et al.*, 1993). Cytochrome p-450 gene polymorphism which results in inter individual variation in enzyme activity may be a risk factor for drug induced gingival overgrowth (Seymour *et al.*, 2000). The age is indirectly proportional to the severity of the enlargement. Younger age people show more enlargements because they have greater fibroblastic metabolism and hormonal change than the elderly (Lu *et al.*, 2007). Thomason *et al.* (1995) related a higher prevalence of gingival overgrowth in younger patients when a treatment with nifedipine and cyclosporine was identified. It was obvious from our case that poor oral hygiene

along with drug dose and duration can increase the gingival growth. It was treated via with initial periodontal therapy including oral hygiene instruction and motivation, followed with surgical gingivectomy. There is a possibility for the gingival overgrowth to recur as long as the associated medication is continued and with other risk factors therefore supportive follow up protocol is advised to monitor her gingival and periodontal status to assess and reinforce oral hygiene periodically.

## CONCLUSION

It is important to evaluate the response of all patients with primary pulmonary hypertension to calcium channel blocking drugs given in appropriate dose. Increased dose of nifedipine proved increased gingival overgrowth. So the physician can consider altering the dose of nifedipine or combine it with other antihypertensive or substitute with other drugs. Patients with nifedipine therapy need prophylaxis at least once in three months for prophylactic control measures; it's for long term benefits for oral and systemic health.

## REFERENCES

- Bullon P, Gallardo I, Goteri G, Rubini C, Battino M, Ribas J, *et al.* 2007. Nifedipine and cyclosporin affect fibroblast calcium and gingiva. *J Dent Res.*, 86(4):357-62
- Ellis JS, Monkman SC, Seymour RA, Idle JR. 1993. Determination of Nifedipine in gingival crevicular fluid: A capillary gas chromatographic method for Nifedipine in microlitre volumes of biological fluid. *J Chromatogr.*, 621:95-101.
- Ellis JS, Seymour RA, Steele JG, Robertson P, Butler TJ, Thomason JM. 1999. Prevalence of gingival overgrowth induced by calcium channel blockers: a community-based study. *J Periodontol.*, 70(1):63-7.
- Florio O, Tfouni M, Balducci I, de Marco AC, Jardini MA, Almeida JD. 2013. Nifedipine-Induced gingival overgrowth. *Brazilian Dental Science*, 15(4):14-20.
- Gelfand EW, Cheung RK, Grinstein S, Mills G. 1986. Characterization of the role for calcium influx in nitrogen-induced triggering of human T-cells. Identification of calcium-dependent and calcium-independent signals. *Eur J Immunol.*, 16:907-11.

- Gomez A, Bialostozky D, Zajarias A, Santos E, Palomar A, Martinez ML *et al.* 2001. Right ventricular ischemia in patients with primary pulmonary hypertension. *J Am Coll Cardiol.*, 38(4):1137-42.
- Hancock RH. and Swan PH. 1992. Nifedipine- induced gingival over growth - Report of a case treated by controlling plaque. *J Clin Periodontol.*, 19:12-4.
- Huang W-T, Lu H-K, Chou H-H, Kuo MYP. 2003. Immunohistochemical analysis of Th1/Th2 cytokine profiles and androgen receptor expression in the pathogenesis of nifedipine-induced gingival overgrowth. *J Periodontal Res.*, 38(4):422-7.
- Lu H-K, Chou H-P, Li C-L, Wang M-Y, Wang L-F. 2007. Stimulation of Cells Derived from Nifedipine-induced Gingival Overgrowth with Porphyromonas gingivalis Lipopolysaccharide, and Interleukin-1 $\beta$ . *J Dent Res.*, 86(11):1100-4.
- Rich S. and Brundage BH. 1987. High-dose calcium channel-blocking therapy for primary pulmonary hypertension: evidence for long-term reduction in pulmonary arterial pressure and regression of right ventricular hypertrophy. *Circulation*, 76(1):135-41.
- Seymour RA, Ellis JS, Thomason JM. 2000. Risk factors for drug-induced gingival overgrowth. *J Clin Periodontol.*, 27(4):217-23.
- Srivastava AK, Kundu D, Bandyopadhyay P, Pal AK. 2010. Management of amlodipine-induced gingival enlargement: Series of three cases. *J Indian Soc Periodontol.*, 14:279.
- Thomason JM, Seymour RA, Ellis JS, Kelly PJ, Parry G, Dark J. *et al.* 1995. Iatrogenic gingival overgrowth in cardiac transplantation. *J Periodontol.*, 66(8):742-6.

\*\*\*\*\*