



## RESEARCH ARTICLE

### A COMPARATIVE CLINICAL EVALUATION OF AMINOBISPHOSPHONATES (ALENDRONATE) IN THE MANAGEMENT OF PERIODONTAL OSSEOUS DEFECTS- A CONTROLLED CLINICAL TRIAL

\*Dr. Cherry Chamria, Dr. Roshani Thakur and Dr. Devanand Shetty

Dr D Y Patil University, School of Dentistry, Navi Mumbai, India

#### ARTICLE INFO

##### Article History:

Received 22<sup>nd</sup> February, 2017  
Received in revised form  
17<sup>th</sup> March, 2017  
Accepted 20<sup>th</sup> April, 2017  
Published online 23<sup>rd</sup> May, 2017

##### Key words:

Infrabony defects,  
Alendronate,  
Ofd,  
Autogenous Bone Graft,  
Host Modulation.

#### ABSTRACT

**Introduction:** Deep intraosseous defects represent a major challenge for the clinician. Sites with intraosseous lesions have been shown to be at higher risk of disease progression in subjects who had not received periodontal therapy. Treatments of intrabony defects include scaling and root planing with surgical access flap. Additional osseous resective therapy and / or reconstructive therapy by means of the application of membranes, biological agents or grafting biomaterials can be used to correct the bone deformities induced by destructive periodontal disease and achieve regeneration. Host modulation is a promising new adjunctive therapeutic option for the management of periodontal diseases. The purpose of host modulation therapy is to restore the balance of proinflammatory or destructive mediators and anti-inflammatory or protective mediators to that seen in healthy individuals. Bisphosphonates are bone seeking agents that inhibit bone resorption by disrupting osteoclast activity. They interfere with osteoblast metabolism and secretion of lysosomal enzymes. More recent evidence has suggested that bisphosphonates also possess anticollagenase properties. In human studies, these agents resulted in enhanced alveolar bone status and density. (El-Shinnawi *et al*-2003) Alendronate was approved by the FDA in the USA in 1995 and studies have reported the effectiveness of ALN in preventing alveolar bone destruction associated with periodontal disease when administered systemically or locally to the target site. It is with this background and since limited studies have been conducted using alendronate as a graft material, this study was undertaken.

**Aim:** To evaluate & compare the efficacy of Open flap debridement, Open flap debridement with Autogenous bone and Open flap debridement with Autogenous bone and Alendronate for the treatment of 2 walled and 3 walled intraosseous defects.

**Materials & Methods:** 30 Subjects in the age range of 30 – 60 years were selected with chronic (clinical attachment loss > 5mm) periodontitis and probing depth  $\geq$  6mm were selected. Mandibular molars, with 2 or 3 walled intrabony defects were included in the study, with no history of metabolic disorders involving bone resorption. Radiographic evidence of bone defects were evident.

**Results:** Mean measurements in the Group C for CAL gain (2.90  $\pm$ 0.73), PD reduction (3.10  $\pm$ 0.73) and RBH (2.40  $\pm$ 0.96) were significantly greater with a p-value <0.05 compared to the mean measurements of CAL gain (3.80  $\pm$ 0.78), PD reduction (4.40  $\pm$ 1.17) and RBH (3.50  $\pm$ 0.84) of Group A.

**Conclusion:** Use of Alendronate- bisphosphonate as an additive material to autogenous bone grafts demonstrated improved results at 6 months and 9 months as compared to baseline.

Copyright©2017, Dr. Cherry Chamria *et al.* This is an open access article distributed under the Creative Commons Attribution License, which permits unrestricted use, distribution, and reproduction in any medium, provided the original work is properly cited.

**Citation:** Dr. Cherry Chamria, Dr. Roshani Thakur and Dr. Devanand Shetty, 2017. "A comparative clinical evaluation of Aminobisphosphonates (Alendronate) in the management of periodontal osseous defects- A controlled clinical trial", *International Journal of Current Research*, 9, (05), 50556-50560.

## INTRODUCTION

Periodontitis is a multifactorial infectious disease of the supporting structures of the teeth, characterized by destruction of the bone and connective tissue. Specific periodontopathic bacteria and their virulence factors are the primary etiologic agents. But, in 1985, research began to focus very closely on bacterial-host interaction, leading to "host-bacterial interrelationship era (Kao *et al.*, 2015) although there is evidence that specific bacterial pathogens initiate pathogenesis of disease, the host response to these pathogens is equally important in mediating connective tissue breakdown and bone

loss. Deep intraosseous defects represent a major challenge for the clinician. Sites with intraosseous lesions have been shown to be at higher risk of disease progression in subjects who had not received periodontal therapy. Treatment of intrabony defects conventionally included scaling and root planing with open flap debridement. (Binderman *et al.*, 2000) Additional osseous resective therapy and / or reconstructive therapy by means of the application of membranes, biological agents or grafting biomaterials can be used to correct the bone deformities induced by destructive periodontal disease and achieve regeneration. The shift in paradigm of concentration on host response led to the development of Host Modulatory Therapies (HMT) which could improve therapeutic outcomes, slow the progression of disease, allow for more predictable management of patients, and possibly even work as preventive

\*Corresponding author: Dr. Cherry Chamria,  
Dr D Y Patil University, School of Dentistry, Navi Mumbai, India.

agents against the development of periodontitis (Nussbaum *et al.*, 1993) Introduction of such host modulation therapeutic agents act as an adjunct to the traditional periodontal therapies and represent a new integrated approach in long-term treatment and management of periodontitis. (Kanis *et al.*, 1995) The purpose of host modulation therapy is to restore the balance of proinflammatory or destructive mediators and anti-inflammatory or protective mediators to that seen in healthy individuals. Three categories of host-modulating agents have been investigated in the periodontal therapy:

1. Antiproteinases (represented by tetracyclines),
2. Anti-inflammatory drugs, and
3. Bone-sparing drugs (represented by anti-resorptive agents such as bisphosphonates).

Alendronate was approved by the FDA in the USA in 1995 and studies have reported the effectiveness of ALN in preventing alveolar bone destruction associated with periodontal disease when administered systemically or locally to the target site. (Yaffe *et al.*, 1997) The net effect of alendronate on bone formation might be explained by its inhibition of osteoclasts, thus affecting bone maturation and remodeling. Once taken up by bone, alendronate has a prolonged skeletal retention (half-life up to several years) and significant amounts can be released in the resorptive process which may in turn provide protection to the alveolar bone. (Yaffe *et al.*, 1995) Limited studies have been reported on alendronate as a graft material. Furthermore, entirely limited studies have been reported that compare the clinical efficacy of alendronate with gold standard for bone grafting i.e. autogenous bone. Hence it is with this background that this study was undertaken. (Pradeep *et al.*, 2013)

## MATERIALS AND METHODS

This clinical and radiographic study was performed in the Department of Periodontics at D. Y. Patil University, School of Dentistry, Nerul, Navi Mumbai. 30 patients, in the age group of 30-60 years, 17 females and 13 males were selected from the OPD of Department of Periodontics at D. Y. Patil University, School of Dentistry, Nerul, Navi Mumbai. The following are the inclusion and exclusion criteria for the study

**Inclusion Criteria:** 30-60 years of age.

- Subjects with chronic (clinical attachment loss > 5mm) periodontitis and probing depth  $\geq$  6mm.
- Mandibular molars with 2 or 3 walled intrabony defects.
- Systemically healthy patients.
- Subjects with the ability to maintain good oral hygiene compliance during Phase I therapy.
- Vital teeth.

**Exclusion Criteria:** Previous periodontal surgery at the site in the past 6 months. Presence of traumatic bite not amenable to correction by occlusal adjustment procedure. Previous regenerative surgery at the same site. Teeth with poor, questionable and hopeless prognosis. Teeth with presence of active infection. Tobacco consumption in any form. Mobile teeth. Poor oral hygiene. Presence of periapical infection. Non-cooperative patients. Patients who are medically compromised or under any therapeutic regimen that alters the outcome of

periodontal therapy. Pregnant and lactating women. Presence of severe cervical abrasion, erosion or root caries that would require restoration. 14. Females on HRT/alendronate for postmenstrual treatment for osteoporosis. Patients with known allergy to bisphosphonates. Subjects without any metabolic disorder involving bone resorption.

**Study Design** The present study was a controlled clinical trial including 3 groups.

- Group A: Patients with intrabony defects to be treated with Open flap debridement
- Group B: Patients with intrabony defects to be treated Open flap debridement and Autogenous bone
- Group C: Patients with intrabony defects to be treated with Openflap debridement, Autogenous bone and Alendronate.

The study obtained its ethical clearance from the Institutional Ethical Committee, D Y Patil University, School of Dentistry, Nerul, Navi Mumbai

### Steps in the conduct of the study

- Proforma was duly filled and all the relevant clinical findings were recorded.
- All the infrabony defects included in the study were 2 or 3 walled in nature and limited to mandibular 1<sup>st</sup> and 2<sup>nd</sup> molars
- Plaque index (PI) by Sillness and Loe (1964) and Gingival Index- Loe and Sillness (1963) (GI) was recorded as a baseline finding.
- Phase I periodontal therapy consisted of full mouth scaling and root planning using both hand and ultrasonic instruments under local anesthesia if required.
- Oral hygiene instructions were given at each visit and reinforced for cement for the oral prophylaxis throughout the study period.
- Patients were recalled after 3-4 weeks and Plaque index (PI) by Sillness and Loe (1964) and Gingival Index- Loe and Sillness (1963) (GI) was recorded again before patients were scheduled for the surgical procedure then at 6 months and 9 months post surgery.
- Random allocation of the patients within 1 of the 3 groups was done by using the online software of randomization <http://www.graphpad.com/quickcalcs/index.cfm>, and patients assign to receive one of the following treatments in the selected teeth.

### Surgical Phase

1. Flap Preparation: The area was sterilized with Povidone Iodine and was anesthetized using 1: 80,000 local anesthesia using the inferior alveolar nerve block and buccal nerve block. Crevice incisions were placed both on buccal and lingual sides extending one tooth mesial and distal to the site. A full thickness periosteal flap was then elevated by blunt dissection using a periosteal elevator to gain access to the root surface and alveolar bone.
1. Defect Preparation: The infrabony defects were debrided and all the root surfaces were scaled and root planed by hand and ultrasonic instruments.
2. Group A patients within infrabony defects were treated with open flap debridement

3. Group B patients with infrabony effects were treated with open flap debridement and Autogenous bone obtained from the mesial or distal aspect of the adjacent tooth surface using a Bone Scrapper (Hu- Friedy)
4. Group C patients within frabony defects were treated with openflap debridement, autogenous bone & Sodium Alendronate (Apex Healthcare Limited-Ankleshwar)
5. Flap Closure: The flaps were subsequently sutured to its original position with care. The buccal and lingual flaps were sutures by interrupted interdental loop sutures with 4-0 black silk suture (Mersilk- Johnson and Johnson Ltd)
7. Follow up care: Patients were given routine post-surgical instructions Patients were instructed to rinse with 0.2 % Chlorhexidine mouth rinse twice daily for 15 days. Patients were asked to refrain from brushing at the surgical site till sutures were removed. Interdental suture removal was done after 14 days.

**Medications:** Antibiotic regime: Amoxicillin 500mg thrice daily for 7 days. Analgesics: Ibuprofen 400mg thrice daily for 7 days.

#### Postsurgical Phase:

1. Patients were seen every 2 weeks for 1 month followed by recalling once a month for the next 9 months for oral prophylaxis and reinforcement of oral hygiene procedures. At the end of 6 months and 9 months all clinical and radiographic measurements were repeated.

## RESULTS

### Interpretation

The mean values of probing depth at three points in time were evaluated. Comparison of scores between baseline to 6 months and 6 months to 9 months was calculated at a confidence interval of 95%. There was statistical significance seen in the probing pocket depth from baseline to 6 months (0.009) but not significant from 6 months to 9 months (0.051) in Group A, There was statistical significance seen in the probing pocket depth from baseline to 6 months (0.001) and from 6 months to 9 months (0.015) in Group B and There was statistical significance seen in the probing pocket depth from baseline to 6 months (0.001) and from 6 months to 9 months (0.022) in group C. The mean values of clinical attachment level at three points in time were evaluated at a confidence interval of 95%. There was statistical significance seen in the clinical attachment level from baseline to 6 months (0.001) and from 6 months to 9 months (0.010) in Group A, from baseline to 6 months (0.001) and from 6 months to 9 months (0.019) in group B and from baseline to 6 months (0.001) and from 6 months to 9 months (0.015) in group C. The mean values of Radiographic Bone Height at three points in time were evaluated at a confidence interval of 95%. There was no statistical significance seen in the Radiographic Bone from baseline to 6 months (0.193) neither from 6 months to 9 months (0.081) in Group A. However there was statistical significance seen in the Radiographic Bone from baseline to 6

**Table 1. Mean values of periodontal pocket depth, clinical attachment level and radiographic bone height between the three groups – open flap debridement, open flap debridement with autogenous bone graft and open flap debridement with autogenous bone graft and alendronate**

Variables	Group A (n=10)	Group B (n=10)	Group C (n=10)
Periodontal Pocket Depth			
Baseline	6.20 ±1.03	6.30 ±1.25	6.60 ±1.26
6 Months	5.00 ±0.81	3.80 ±0.63	3.90 ±0.56
9 Months	4.40 ±1.17	3.30 ±0.48	3.10 ±0.73
Clinical Attachment Level			
Baseline	6.20 ±1.03	6.30 ±1.25	6.60 ±1.26
6 Months	4.50 ±0.52	3.80 ±0.63	3.40 ±0.51
9 Months	3.80 ±0.78	2.90 ±0.73	2.90 ±0.73
Radiographic Bone Height			
Baseline	4.10 ±0.73	4.10 ±0.87	4.50 ±0.97
6 Months	3.80 ±0.91	3.00 ±0.81	2.70 ±0.94
9 Months	3.50 ±0.84	2.60 ±1.07	2.40 ±0.96

**Table 2. Comparison of periodontal pocket depth scores between baseline and 6 months and 6 months and 9 months in Group A (open flap debridement group)**

Periodontal Pocket Depth	N	Mean	S.D.	S.E.	M.D.	95% C.I.	t-Value	Df	P-Value*
Baseline	10	6.20	1.03	0.32	1.20	0.38-2.01	3.343	9	0.009 <sup>†</sup>
6 Months	10	5.00	0.81	0.25					
6 Months	10	5.00	0.81	0.25	0.60	-0.00-1.20	2.250	9	0.051
9 Months	10	4.40	1.17	0.37					

\*p-value derived from paired t-test<sup>††</sup> significant at p < 0.01

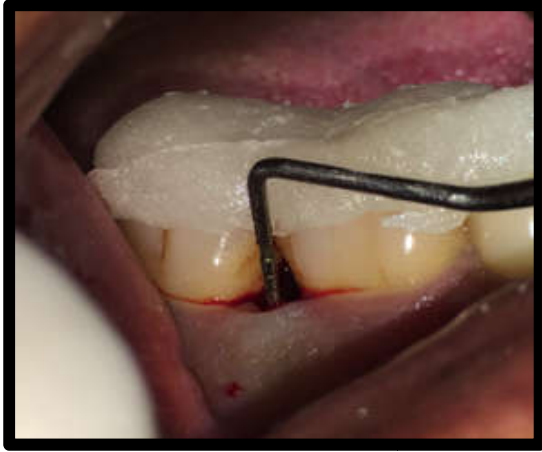**Table 3. Comparison of periodontal pocket depth scores between baseline and 6 months and 6 months and 9 months in Group B (open flap debridement with autogenous bone graft group)**

Periodontal Pocket Depth	N	Mean	S.D.	S.E.	M.D.	95% C.I.	t-Value	df	P-Value*
Baseline	10	6.30	1.25	0.39	2.50	1.80-3.19	8.135	9	<0.001 <sup>††</sup>
6 Months	10	3.80	0.63	0.20					
6 Months	10	3.80	0.63	0.20	0.50	0.12-.87	3.000	9	0.015 <sup>†</sup>
9 Months	10	3.30	0.48	0.15					

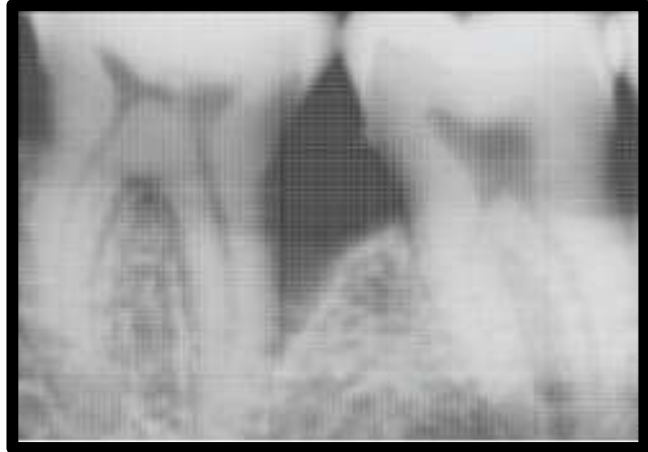\*p-value derived from paired t-test<sup>†</sup> significant at p < 0.05 ;<sup>††</sup> significant at p < 0.01

**Table 4. Comparison of periodontal pocket depth scores between baseline and 6 months and 6 months and 9 months in Group C (open flap debridement with autogenous bone graft and alendronate group)**

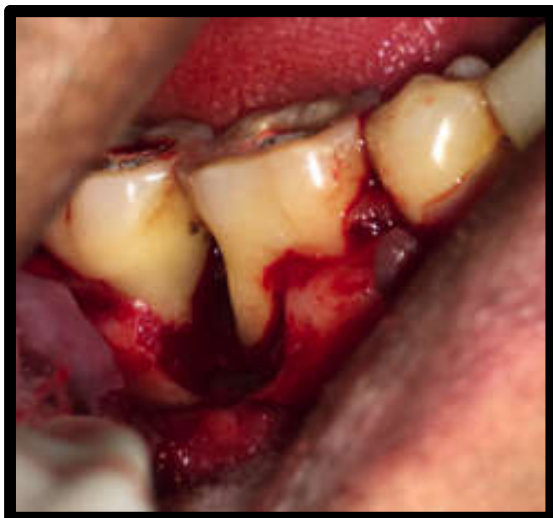Periodontal Pocket Depth	N	Mean	S.D.	S.E.	M.D.	95% C.I.	t-Value	df	P-Value*
Baseline	10	6.60	1.26	0.40	2.70	1.94-3.45	8.060	9	<0.001 <sup>††</sup>
6 Months	10	3.90	0.56	0.17					
6 Months	10	3.90	0.56	0.17	0.80	0.14-1.45	2.753	9	0.022 <sup>†</sup>
9 Months	10	3.10	0.73	0.23					



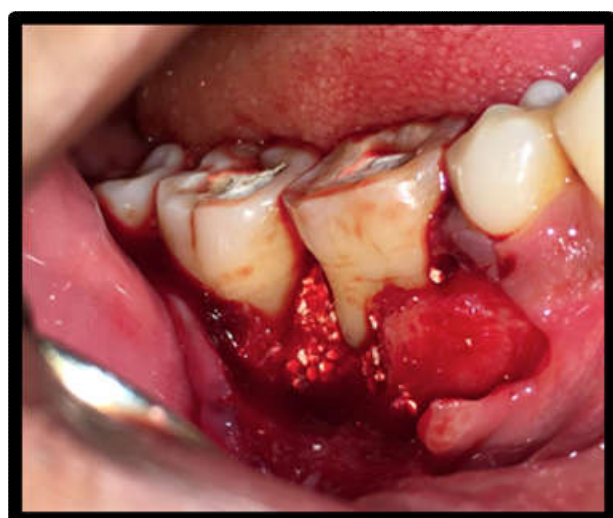
Preoperative



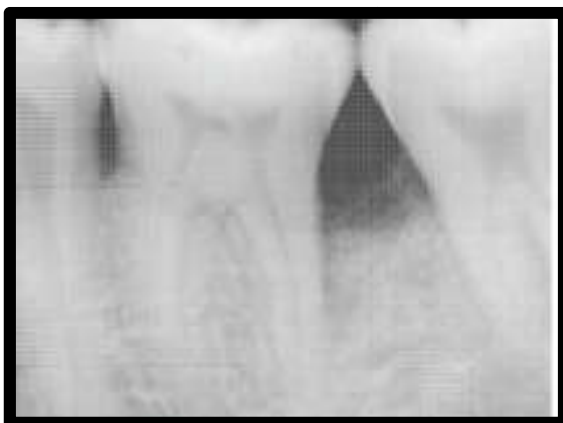Preoperative xrays



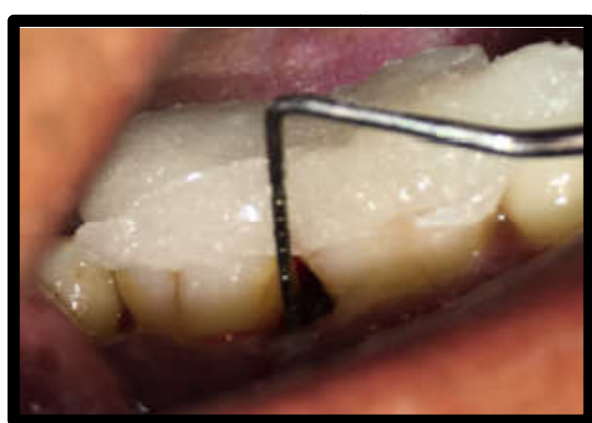Defect



Defect Filled



Postoperative xrays -9 months later



Postoperative-9 months later

months (0.001) and from 6 months to 9 months (0.037) in group B and from baseline to 6 months (0.001) but not from 6 months to 9 months (0.081) in Group C.

## DISCUSSION

In the present study on Intra-group comparison all 3 groups showed improvement with respect to mean reduction in Pocket

Probing Depth (PPD) of ( $P < 0.001$ ) at 6 months and ( $P < 0.022$ ) at 9 months, and gain in Clinical Attachment Level (CAL) of ( $P < 0.001$ ) at 6 months and ( $P < 0.015$ ) at 9 months and Radiographic Bone gain ( $P < 0.001$ ) at 6 months and 0.081 at 9 months. These results are in accordance with the study done by and Pradeep *et al.* (2013) in this study they have used Alendronate sodium and autogenous bone grafts where the mean pocket probing depth reduction was  $3.40 \pm 0.55$  mm ( $P < 0.001$ ). The clinical attachment gain for the intraosseous defects was  $3.2 \pm 2.17$ mm ( $P < 0.030$ ). The radiographic bone height gain was  $4.00 \pm 1.58$ mm ( $P < 0.015$ ) at 9 months. This study by far remains one of the earliest Controlled Clinical Trial involving 3 groups i.e. use of Autogenous bone graft along with ALN, autogenous bone graft alone and OFD as treatment modalities for the management of 2 or 3 walled intraosseous defects as compared to all of the previous studies. The present study has shown good results and additional benefits in clinical and radiographic parameters when Alendronate sodium was used in combination with autogenous bone graft. Thus in future, Alendronate sodium, bisphosphonate may prove to be a novel adjunct to conventional regenerative therapeutic modalities in management of periodontal defects. A larger sample size and longer observational period would enhance the ability to detect differences between three the groups and confirm the stability and substantivity of the clinical outcome.

### Conclusion

The present study showed that the predictability of bone formation increased by adding a host modulating agent like ALN to bone graft materials. Histologic studies are required to confirm the bone formation potential and effective dosage of ALN in human intra- osseous defects. Further research to produce an efficient drug delivery vehicle for controlled sustained release of the drug is required.

### REFERENCES

- Binderman I, Adut M, Yaffe A. 2000. Effectiveness of local delivery of Alendronate in reducing alveolar bone loss following periodontal surgery in rats. *J Periodontol.*, 71:1236-40.
- Kanis JA, Gertz BJ, Singer F, Ortolani S. 1995. Rationale for the use of alendronate in osteoporosis. *Osteoporos Int.*, 5:1-13.
- Kao RT, Nares S, Reynolds MA. 2015. Periodontal regeneration — Intrabony defects: A systematic review from the AAP Regeneration Workshop. *J Periodontol.*, 86(Suppl. 2):S77-S104.
- Nussbaum SR, Warrell RP Jr, Rude R, Glusman J, Bilezikian JP, Stewart AF, *et al.* 1993. Dose response study of alendronate sodium for the treatment of cancer-associated hypercalcemia. *J ClinOncol.*, 11:1618-23.
- Pradeep AR *et al.* 2013. 1% alendronate gel as local drug delivery in the treatment of degree II furcation defects: a randomized controlled clinical trial. *J Periodontol.*, 84:307-315.
- Yaffe A, Fine N, Alt I, Binderman I. 1995. Effect of bisphosphonate on alveolar bone resorption following mucoperiosteal flap surgery in the mandible of rats. *J Periodontol.*, 66:999-1003.
- Yaffe A, Iztovich M, Earon Y, Alt I, Lilov R, Binderman I. 1997. Local delivery of an aminobisphosphonate prevents the resorptive phase of alveolar bone following mucoperiosteal flap surgery in rats. *J Periodontol.*, 68: 884-9.

\*\*\*\*\*